

---

# Limb-Sparing Resections of the Shoulder Girdle

Jacob Bickels, MD, James C Wittig, MD, Yehuda Kollender, MD, Kristen Kellar-Graney, BS, Isaac Meller, MD, Martin M Malawer, MD, FACS

---

- BACKGROUND:** Limb-sparing surgeries around the shoulder girdle pose a surgical difficulty, because tumors arising in this location are frequently large at presentation, are juxtaposed to the neurovascular bundle, require en bloc resection of proportionally large amounts of bone and soft tissues, and necessitate complex resection and reconstruction.
- STUDY DESIGN:** Between 1980 and 1997, we treated 134 patients who presented with 110 primary malignant, 12 metastatic, and 12 benign aggressive bone and soft tissue tumors of the shoulder girdle and subsequently underwent a limb-sparing resection. Reconstruction of the bone defect included 92 proximal humerus and 9 scapular prostheses. All patients were followed up for a minimum of 2 years. We summarize the principles of limb-sparing resections of the shoulder girdle, with emphasis on the surgical anatomy of the shoulder girdle, principles of resection and reconstruction, and functional outcomes.
- RESULTS:** Function was estimated to be good or excellent in 101 patients (75.4%), moderate in 23 patients (17.1%), and poor in 10 patients (7.5%). Complications included 13 transient nerve palsies, 2 deep wound infections, and 1 prosthetic loosening. Local tumor recurrence occurred in 5 of 103 (4.9%) patients with primary sarcomas of the shoulder girdle.
- CONCLUSIONS:** Detailed preoperative evaluation and surgical planning are essential for performing a limb-sparing resection around the shoulder girdle. Local tumor control, associated with good functional outcomes, is achieved in the majority of patients. (*J Am Coll Surg* 2002;194:422–435. © 2002 by the American College of Surgeons)
- 

The shoulder girdle consists of the distal third of the clavicle, the scapula, and the proximal humerus and their surrounding envelope of muscles, nerves, and blood vessels. It is a common site of origin for high-grade primary bone sarcomas.<sup>1,2</sup>

Limb-sparing resections of malignant tumors of the shoulder girdle were long considered high-risk procedures because of the proximity of these tumors to the neurovascular bundle, the extent of bone and soft tissue resection required, and the poor anticipated functional outcomes.<sup>3</sup> Resections of large bone and soft tissue tumors were also thought to place the patient in jeopardy of a local recurrence.<sup>4</sup> As a result, before the mid-1970s,

shoulder disarticulation and forequarter amputation were the chosen treatment for patients with large tumors of the shoulder girdle. Both procedures were associated with major functional disability and dismal cosmetic and psychologic outcomes. Improved survival of patients with sarcomas made these effects of amputation surgeries even more pronounced and motivated the investigation of a less aggressive surgical approach. A better understanding of the biologic behavior of musculoskeletal tumors, the introduction of effective neoadjuvant chemotherapy that markedly reduced tumor size, and availability of options for reconstruction of major bony defects have allowed limb-sparing surgery to be done in 90% to 95% of these extreme situations.<sup>5,6</sup>

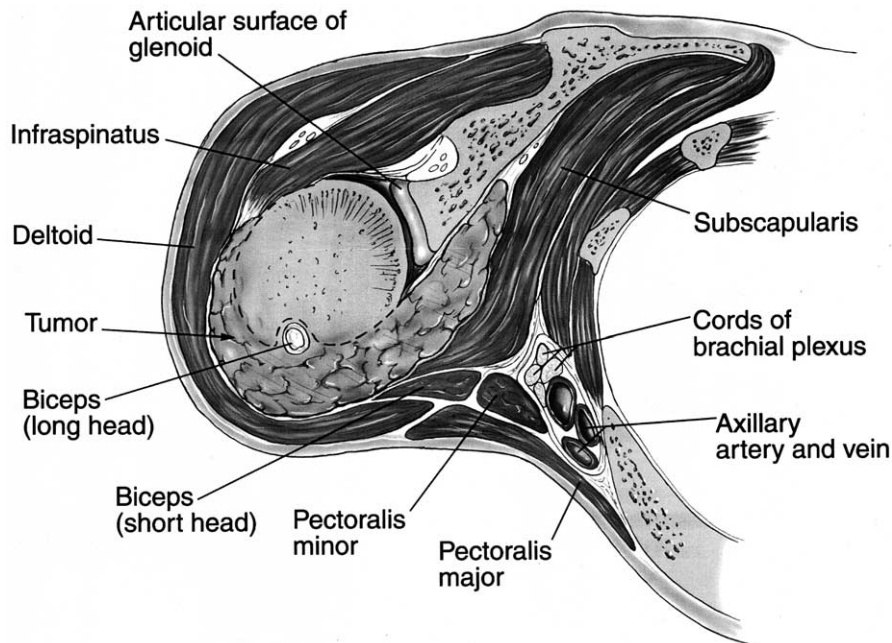
Boris Linberg<sup>7</sup> is considered to be the pioneer of limb-sparing resection for malignant tumors of the upper extremity. Although he published his experience with three patients in 1928, only a few cases of interscapulothoracic resection (Tikhoff-Linberg resection) were published until the 1970s.<sup>8-10</sup> In 1977, Marcove and colleagues<sup>11</sup> published the first report of a large series of patients with malignant tumors, most of which were high-grade sarcomas of the proximal humerus and scapula, who were

**No competing interests declared.**

Received August 1, 2001; Revised December 6, 2001; Accepted December 7, 2001.

From the Department of Orthopedic Oncology, Washington Cancer Institute, Washington Hospital Center, George Washington University, Washington, DC (Bickels, Wittig, Kellar-Graney, Malawer); and The National Unit of Orthopedic Oncology, Tel-Aviv Sourasky Medical Center, Sackler Faculty of Medicine, Tel-Aviv University, Tel-Aviv, Israel (Kollender, Meller).

Correspondence address: Martin M Malawer, MD, FACS, Department of Orthopedic Oncology, Washington Cancer Institute, Washington Hospital Center, 110 Irving St, NW, Washington, DC 20010.



**Figure 1.** Pattern of local extension of primary bone sarcomas of the proximal humerus. These tumors usually present with an extraosseous component and take the path of least resistance. The subscapularis muscle protects the neurovascular bundle. Extension through the joint capsule and biceps tendon may contaminate the joint space. (Reprinted from: Wittig JC, Kellar-Graney KL, Malawer MM, et al. Limb-sparing surgery for high-grade sarcomas of the proximal humerus. *Tech Shoulder Elbow Surg* 2001;2:54–69, with permission.)

treated with resection in lieu of forequarter amputation. In that series, which involved 17 patients, local recurrence and survival rates were similar to those achieved with forequarter amputation, but cosmesis and function were much better, with preservation of elbow motion and hand dexterity.

Between 1980 and 1997, we did 134 limb-sparing resections of bone tumors or deep, soft tissue tumors that necessitated en bloc resection of a bony component of the shoulder girdle; all patients were followed up for a minimum of 2 years. On the basis of this series, we here outline the guidelines for surgical management of a large tumor of the shoulder girdle. Emphasis is placed on preoperative evaluation; essentials of surgical anatomy of the shoulder girdle; and principles of resection, reconstruction, and rehabilitation.

### Surgical anatomy considerations

The shoulder girdle is a tight space in which bony structures, muscles, nerves, and blood vessels of the upper extremity are situated in close proximity to each other. Local anatomy influences extension of primary bone sarcomas by setting natural barriers to extension. High-grade sarcomas of bone that arise from the proximal humerus usually present with a cortical breakthrough

and a large extraosseous component. Although there are no truly soft tissue compartments around the proximal humerus, several spaces that are bound by muscles and their aponeuroses pose an anatomic barrier to tumor extension and serve as a functional compartment. These muscles, especially the subscapularis at the anterior aspect of the tumor, are compressed into a pseudocapsular layer and form a protective barrier that prevents encasement of the main neurovascular bundle by the tumor (Fig. 1). This phenomenon allows en bloc resection of the tumor with the covering muscle layer without major neurovascular compromise of the extremity. Similarly, tumors of the scapula are surrounded by a cuff of muscles in all dimensions that initially prevents direct invasion to the chest wall and adjacent neurovascular bundle. As a result, these tumors remain asymptomatic for a prolonged time. When brought to a physician's attention they are commonly large and in close proximity to the vital structures of the shoulder girdle.

Because of the relatively small joint size, tumor extension into the glenohumeral joint is common; primary bone sarcomas of the proximal humerus or scapula can cross the articular surface through the joint capsule and biceps tendon and contaminate the joint space. Because

of this, pericapsular and rotator cuff involvement should be carefully evaluated. It is safer to do extraarticular resection (in which the glenohumeral joint is resected en bloc with the tumor) for most high-grade sarcomas around the glenohumeral joint to ensure complete tumor removal. Intraarticular resection (in which the plane of resection passes through the glenohumeral joint) can be considered for metastatic lesions or low-grade sarcomas, which usually present with a relatively small extraosseous extension, or, in rare instances, for a completely intraosseous high-grade sarcoma.

The neurovascular bundle of the upper extremity passes under the clavicle and past the proximal humerus. It is tethered to the proximal humerus by the anterior and posterior circumflex vessels and is often displaced by large tumors of the proximal humerus and scapula. Early ligation of the circumflex vessels is a key maneuver in resection of proximal humeral sarcomas because it allows the entire axillary artery and vein to fall away from the tumor mass. Occasionally, anomalous brachial and axillary arteries can be seen that would be difficult to identify and explore if not recognized preoperatively. An angiogram should be obtained before surgery to localize the brachial artery and identify the level of circumflex vessels.

Tumors of the proximal humerus rarely invade the subscapularis muscle or break through the posterior humeral cortex. As a result, the musculocutaneous and radial nerves are rarely violated by tumor extension. Preservation of these nerves is essential for normal elbow and hand function, and because they can easily be injured during dissection, they should be identified and mobilized before any resection.

### **Preoperative evaluation**

#### **Physical examination**

Findings of the physical examination may suggest tumor extension into the glenohumeral joint, neurovascular involvement, or tumor invasion of the chest wall. If tumor has grossly invaded the joint, the patient might report discomfort and pain when moving the shoulder, and shoulder range of motion is generally reduced. Tumors that move freely with respect to the chest wall usually are separated from it by at least a thin plane of tissues, through which it is possible to dissect without compromising local tumor control. Abnormal neurologic evaluation, decreased pulses, or limb edema indicate neurovascular compression or invasion by the tumor.

### **Imaging studies**

The ultimate purpose of all imaging studies is to determine the anatomic extent of the tumor. Plain radiographs are the initial imaging modality for evaluation of bone tumors of the shoulder girdle. Because of the fine trabecular detail revealed by plain radiographs, they can detect bone lesions of the proximal humerus at a very early stage. Tumors of the scapula, by contrast, often are associated with a delayed diagnosis because of the overlying chest.

Exact evaluation of local tumor extension is achieved by two complementary studies: CT and MRI. CT reveals the extent of cortical involvement and breakthrough by the tumor. MRI is used to assess the intramedullary and extraosseous tumor extent. The relatively simple cortical outlines of the proximal humerus allow accurate assessment of tumor extent in this location by plain radiographs and MRI alone. Bone scan is used mainly to detect skeletal metastases elsewhere. Locally, it can indicate tumor extension across the glenohumeral joint and into the opposing bone or the chest wall. Although blood vessels can be seen using MRI, angiography remains the most useful study for determining the relationship of the tumor to the major blood vessels of the shoulder girdle and the presence of vascular anomalies.<sup>6</sup> A good response to chemotherapy causes tumor necrosis and a reduction in tumor vascularity. Serial angiographs that show such a reduction have been reported to be indicative of good response to preoperative chemotherapy.<sup>6</sup> Given the high quality of MRI angiograms, tumor relation to the vascular bundle and response to chemotherapy can be assessed by this modality as well.

Concluding the preoperative evaluation, local and systemic tumor extents are determined. Based on these studies, the trained surgical oncologist should be able to develop a three-dimensional concept of local tumor anatomy. Contraindications for a limb-sparing attempt are direct tumor invasion of the major neurovascular bundle of the upper extremity, chest wall invasion, and massive soft tissue extension with no option for wound closure and prosthetic coverage or an anticipated major loss of function.

### **METHODS**

Patients were treated at two different institutions; all participating surgeons were trained together and used the same techniques of resection and reconstruction.

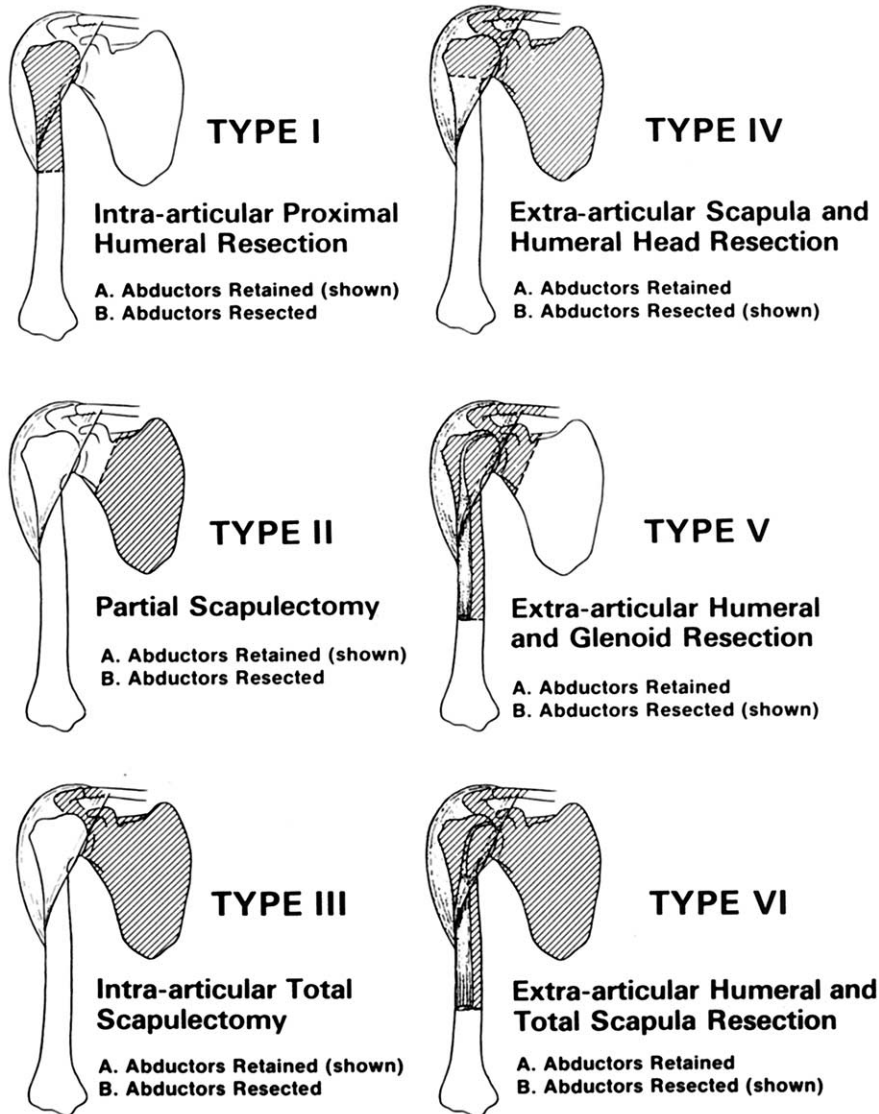
**Table 1.** Histologic Classification and Anatomic Location of Bone and Soft Tissue Tumors Around the Shoulder Girdle

Tumor histologic type	Anatomic location (n)				Total (n)
	Proximal humerus	Scapula	Proximal arm	Periscapular	
Primary bone sarcomas					88
Osteosarcoma	40	6	—	—	
Chondrosarcoma	29	5	—	—	
Ewing's sarcoma	3	5	—	—	
Other primary malignancies of bone					7
Lymphoma	1	2	—	—	
Multiple myeloma	1	2	—	—	
Hemangiopericytoma	—	1	—	—	
Metastatic bone disease					12
Adenocarcinoma of breast	7	—	—	—	
Carcinoma of lung	3	—	—	—	
Renal cell carcinoma	—	1	—	—	
Adenocarcinoma of unknown origin	1	—	—	—	
Benign aggressive and benign bone tumors					10
Giant cell tumor	2	1	—	—	
Aneurysmal bone cyst	1	1	—	—	
Chondroblastoma	1	—	—	—	
Aggressive osteoblastoma	1	—	—	—	
Osteochondroma	—	3	—	—	
Soft tissue sarcomas					15
Malignant fibrous histiocytoma	—	—	1	8	
Synovial sarcoma	—	—	1	2	
High-grade spindle cell sarcoma	—	—	—	3	
Benign aggressive soft tissue tumors					2
Fibromatosis	—	—	—	2	
Total (n)	90	27	2	15	134

There were 71 male and 63 female patients, ranging in age from 9 to 90 years (median, 30.5 years). Preoperative evaluation included a medical history with emphasis on neurologic symptoms and a physical examination with assessment of the anatomic relation of the lesion to the major neurovascular bundle of the upper extremity, the availability of uninvolved muscles for the purpose of soft tissue reconstruction, and complete neurovascular evaluation. Staging studies included plain radiography, CT, MRI, and angiography of the shoulder girdle and upper extremity and bone scan. Biopsy was performed only at conclusion of staging. Core needle biopsies were preferred, and biopsy site was in line with that of the anticipated incision of the definitive resection. Histologic classification and anatomic location of the 134 tumors are summarized in Table 1. There were 95 primary malignant, 12 metastatic, and 10 benign aggressive tumors of bone. Other diagnoses included 15 soft tissue sarcomas and 2 benign aggressive soft tissue tumors. Indica-

tions for surgery in the 12 patients who had metastatic bone disease were impending or pathologic fracture at presentation (7 patients), intractable pain (2 patients), and solitary bone metastasis (3 patients). Impending and pathologic fracture were grouped together as a single indication because both represent a mechanical failure of the skeleton. High-grade bone sarcomas were treated pre- and postoperatively with chemotherapy. High-grade soft tissue sarcomas were treated postoperatively with radiation therapy. Radiation therapy was also given postoperatively for high-grade bone sarcomas with a surgical margin of less than 1 mm. We preferentially used postoperative radiation therapy to avoid potential difficulty in surgery because of local scarring and inflammation, both of which might be the sequelae of preoperative radiation therapy.

All patients were followed up for a minimum of 2 years (range, 2 to 17 years; average, 6.7 years). For the first 2 years after surgery, patients were evaluated every 3

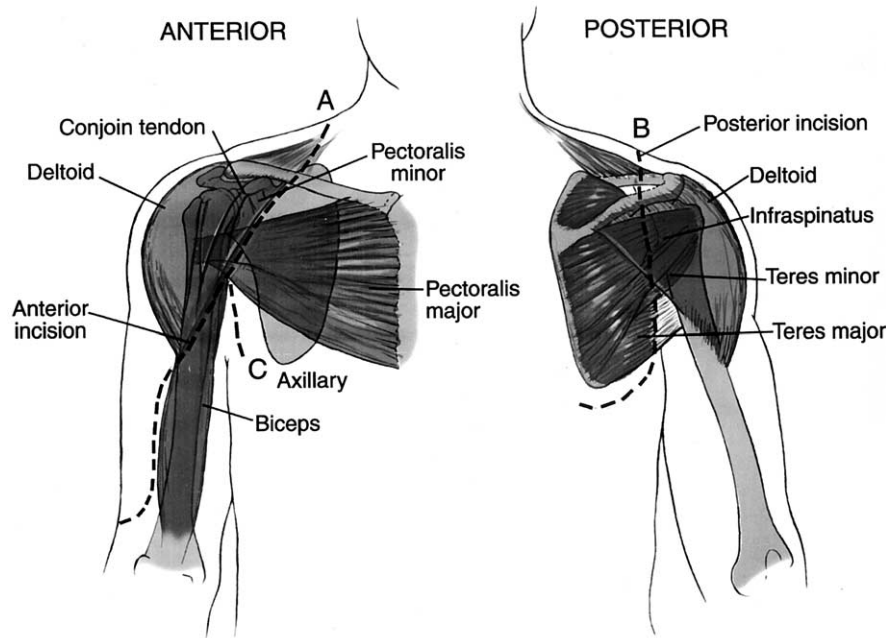


**Figure 2.** Surgical classification system of limb-sparing resections of the shoulder girdle. (Reprinted from: Wittig JC, Kellar-Graney KL, Malawer MM, et al. Limb-sparing surgery for high-grade sarcomas of the proximal humerus. *Tech Shoulder Elbow Surg* 2001;2:54–69, with permission.)

months. On each visit, physical examination, plain radiography, and chest CT were performed. Patients were evaluated semiannually for an additional 3 years and annually thereafter. An orthopaedic oncologist analyzed the clinical records, operative reports, and imaging studies. The histopathologic diagnoses, types of resection, technique and prostheses used for reconstruction, complications, and rates of local tumor recurrence and revisions were determined. Functional evaluation was done according to the American Musculoskeletal Tumor Society System,<sup>12</sup> which assigns a numerical value to pain,

function, emotional acceptance, hand positioning, dexterity, and lifting ability. The functional outcomes presented here are based on each patient's followup evaluation at 2 years after surgery.

Shoulder girdle resections were classified according to the classification system proposed by Malawer and colleagues<sup>13</sup> in 1991. This system was designed to provide guidelines for resections of the shoulder girdle. It is based on anatomic location, extent of the tumor, and tumor grade. In the classification scheme, resection types are numbered I to VI. Each number can be divided into



**Figure 3.** Anterior and posterior arms of the utilitarian shoulder girdle incision. (Reprinted from: Wittig JC, Kellar-Graney KL, Malawer MM, et al. Limb-sparing surgery for high-grade sarcomas of the proximal humerus. *Tech Shoulder Elbow Surg* 2001;2:54–69, with permission.)

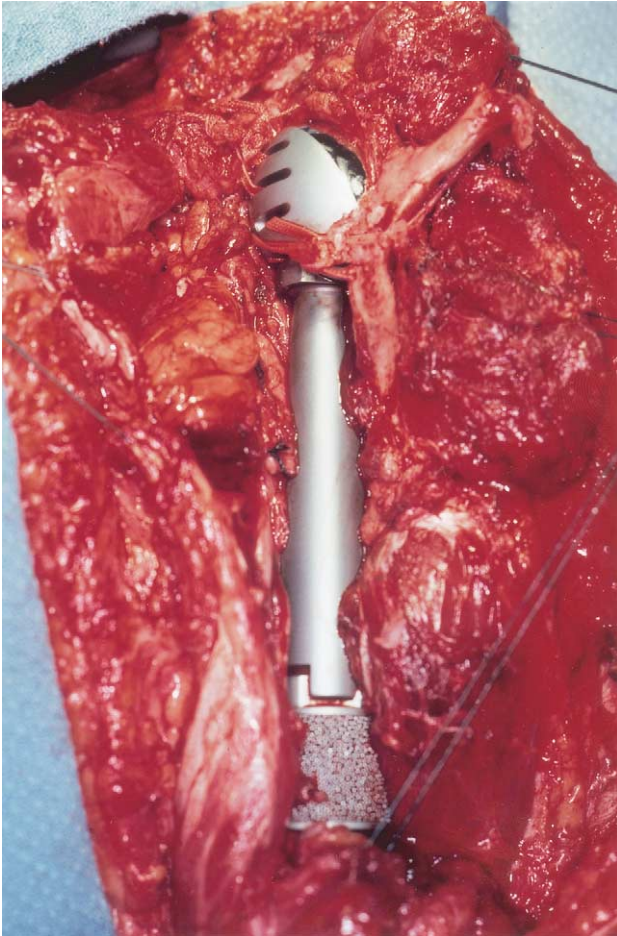
subtype A and B based on preservation or removal, respectively, of the abductor muscles (Fig. 2). In general, type I to III resections are intraarticular and are used to manage benign aggressive, low-grade malignancies or metastatic lesions, which usually have a relatively small extraosseous component without intracapsular extension. Types IV to VI resections are extraarticular. They are used to manage high-grade primary sarcomas of the shoulder girdle, which usually have a notable extraosseous component at presentation and commonly extend into the joint.

### Surgical technique

Limb-sparing resection of the shoulder girdle has three steps: tumor resection, bone defect reconstruction (if required), and soft tissue reconstruction. Reconstruction of the bony defect remaining after resection of bone or soft tissue tumor of the shoulder girdle is aimed at achieving a stable and moveable shoulder, adequate soft tissue coverage of the surgical wound and endoprosthesis (if present), and a functional extremity by a combination of static and dynamic muscle transfers. The three steps of limb-sparing resections are described separately in the following paragraphs.

### Tumor resection

The patient is placed in a semilateral position. A utilitarian shoulder girdle incision is used. This incision has anterior and posterior arms; anteriorly, it begins at the junction of the inner and middle thirds of the clavicle and continues over the coracoid process, along the deltopectoral groove, and down the arm over the medial border of the biceps muscle (Fig. 3). Posteriorly, the incision runs over the lateral aspect of the scapula, along the neck of the glenoid, and distally to the inferior tip of the scapula and curves toward the midline (Fig. 3). All or part of the incision can be used for adequate exploration of the neurovascular bundle and resection of any extent of the humerus and scapula. An initial key step in resection of the proximal humerus or extraarticular resection of the scapula is the exposure of the major neurovascular bundle of the upper extremity. This is done through the anterior arm of the utilitarian incision. Through the deltopectoral interval, the pectoralis major tendon is detached from its humeral insertion and reflected medially. This is followed by detachment and caudal reflection of the coracoid origins of the pectoralis minor, coracobrachialis, and short head of the biceps muscle. The musculocutaneous nerve is identified as it passes between the biceps and brachialis muscles and is preserved, if possi-

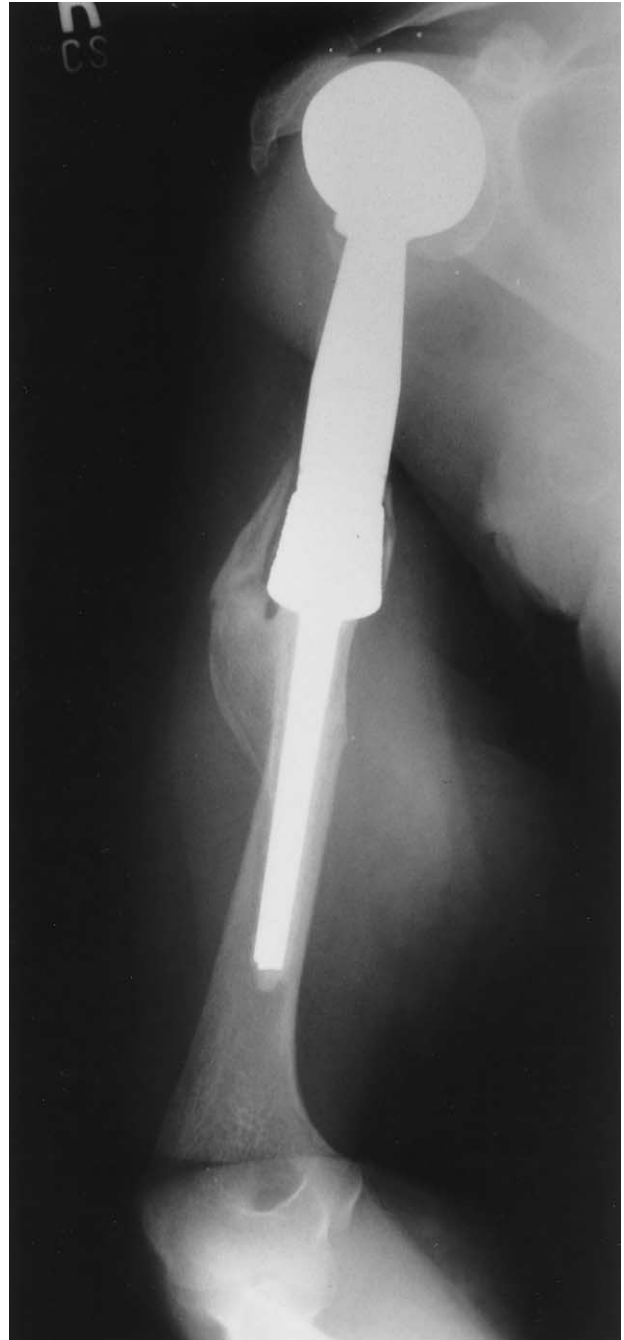


**Figure 4.** Proximal humerus endoprosthesis positioned anterior to the scapula and secured to the scapula and clavicle with Dacron tapes.

ble, to allow elbow flexion. The circumflex humeral vessels are ligated during the initial dissection; this allows the brachial artery and vein and nerves to be retracted away from the tumor mass. Intraarticular resections of the proximal humerus (type I) usually are done solely through the anterior arm of the utilitarian incision. Intraarticular total scapulectomies (type III) usually are done through the posterior arm of the utilitarian incision. Extraarticular resection of the glenohumeral joint (types IV through VI) requires both the anterior and posterior arms.

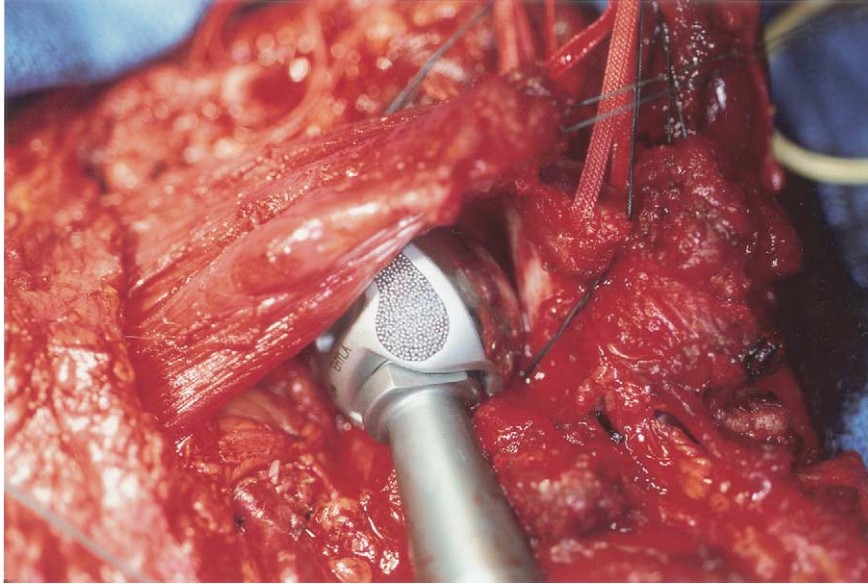
#### **Proximal humerus reconstruction** **Bone defect reconstruction**

Proximal humerus endoprosthesis is used for reconstruction. If intraarticular resection was performed, the prosthesis is positioned against the intact glenoid. If extraar-



**Figure 5.** Plain radiograph of proximal humerus endoprosthesis positioned against the glenoid after intraarticular resection of a proximal humeral chondrosarcoma.

ticular resection was performed, the prosthesis is positioned anterior to the remaining scapula, within the scapulothoracic joint. The prosthesis is then secured to the scapula and clavicle with 3-mm Dacron tape (Deknatel, Falls River, MA; Figs. 4, 5).



**Figure 6.** Pectoralis major muscle is laid anteriorly over a proximal humerus endoprosthesis head.

### **Soft tissue reconstruction**

The pectoralis major muscle is a cornerstone of soft tissue reconstruction. Laid anteriorly over the newly formed prosthesis-scapular joint and sutured to the lateral border of the scapula, it serves as a protective layer between the fasciocutaneous flap and the prosthesis (Fig. 6). The trapezius, supraspinatus, infraspinatus, and teres minor are secured to the superior and lateral borders of the pectoralis major. The pectoralis minor muscle is sutured to the subscapularis muscle over the neurovascular bundle to protect it from the prosthesis. The biceps and coracobrachialis are sutured together and are then reattached to the remaining clavicle and tenodesed to the underlying pectoralis major. The remaining long head of the biceps and the brachialis muscle are sutured to the short head of the biceps muscle under appropriate tension to contribute to its flexion ability. The remaining triceps muscle is secured anteriorly along the lateral border of the biceps to cover the lower and lateral portion of the prosthetic shaft.

### **Scapular reconstructions**

#### **Bone defect reconstruction**

In scapular resection with sparing of the glenohumeral joint (type II), no bony reconstruction is done. Total intraarticular scapulectomy can be followed with one of two reconstructive options: either proximal humerus suspension from the clavicle with a 3-mm Dacron tape or a total scapular endoprosthesis reconstruction. The

latter can be performed only if adequate muscle is available for prosthetic coverage. Scapular prosthesis muscle coverage includes the deltoid, trapezius, rhomboids, and latissimus dorsi muscles. If the remaining muscles are inadequate for coverage of a scapular endoprosthesis, suspension of the proximal humerus from the clavicle is done. Total scapular endoprosthesis reconstruction entails resecting the proximal humerus and replacing it with a prosthesis that opposes the articular surface of the scapular prosthesis (Figs. 7, 8). The endoprosthesis articulation between the scapula and proximal humerus is reinforced with a Gore-Tex sleeve (WL Gore & Assoc, Flagstaff, AZ), which bridges the endoprosthesis articulation, acts like the native joint capsule, and provides the initial mechanical support needed for healing and scarring of the surrounding soft tissues (Fig. 9).

### **Soft tissue reconstruction**

Muscle reconstruction after scapular endoprosthesis reconstruction is imperative. The scapular prosthesis, which is undersized, is laid on the chest wall in a muscular pocket that is formed anteriorly by the serratus anterior muscle (the muscle is placed between the prosthesis and the chest wall) and posteriorly by the teres major and minor muscles, if present, and the rhomboids and levator scapulae muscles. These are attached to the axillary and medial border of the prosthesis through its fenestrations. The trapezius and the posterior deltoid muscles are then tenodesed to provide coverage of the





**Figure 7.** Total scapular and proximal humerus endoprosthesis (Howmedica, Rutherford, NJ).

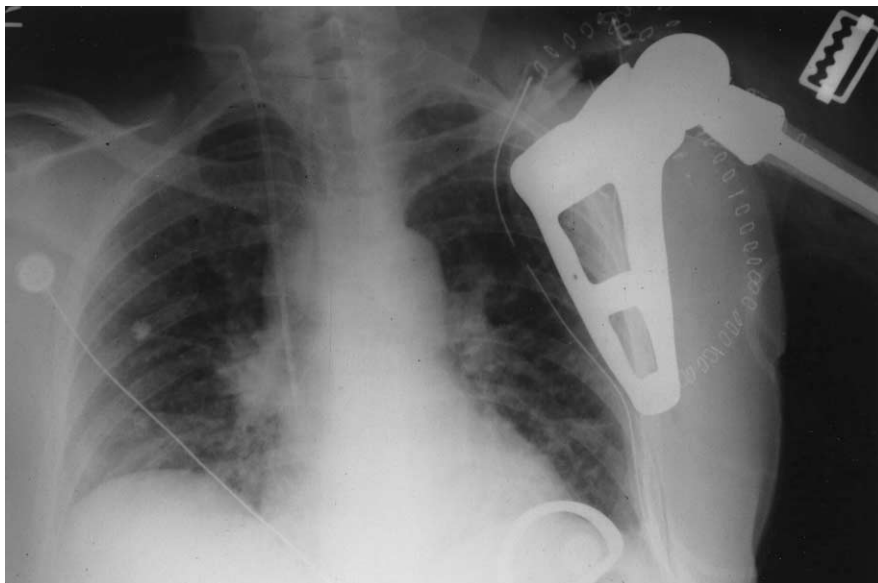
prosthesis. The latissimus dorsi muscle is advanced superiorly to cover the majority of the scapular prosthesis and the previous muscle transfers.

Large-bore suction catheters or a 28-gauge chest tube are used for drainage. The flaps are closed using a non-absorbable suture; their undersurface is tacked to the underlying muscle. After surgery, the shoulder is immobilized in a sling for 3 to 4 weeks or until soft tissue healing is established. During that time, full rehabilita-

tion emphasizes range of motion of the elbow, wrist, and fingers with gravity assistance. Gradual passive and active range of motion of the shoulder with emphasis on forward flexion, abduction, and shrugging then is started.

## RESULTS

One hundred thirty-four patients underwent shoulder girdle resection. Overall, there were 36 proximal hu-



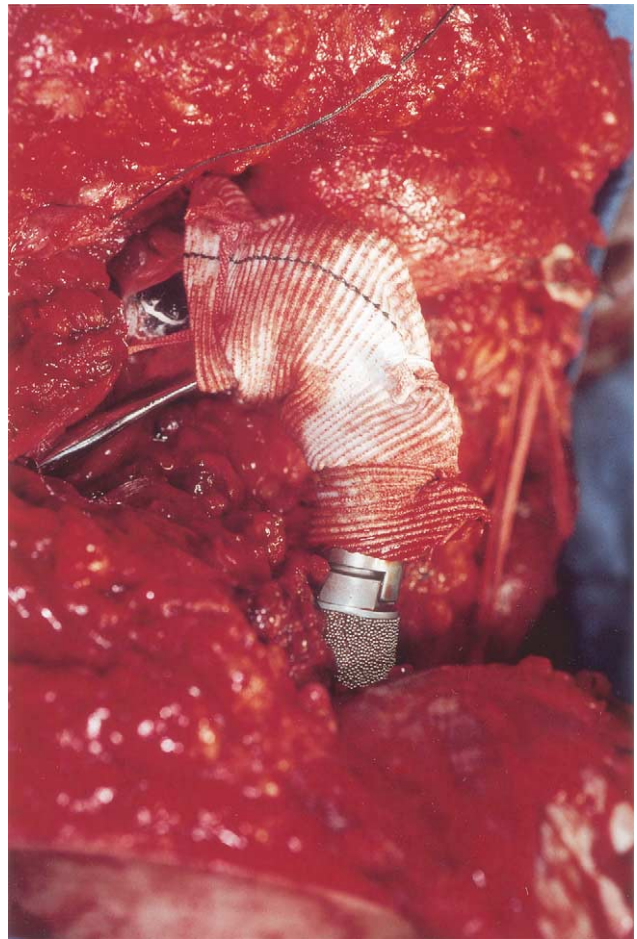
**Figure 8.** Plain radiograph of total scapular endoprosthesis reconstruction after total scapular resection for osteosarcoma of the scapula.

meral, 33 scapular, and 65 en bloc proximal humeral and scapular resections. Endoprosthetic reconstruction included 92 proximal humeral and 9 scapular prostheses. Reconstruction devices included 75 modular, 22 custom-made, and 4 expandable prostheses. Reconstruction of the bone defect was not required in 33 patients.

Function was estimated to be good to excellent in 101 patients (75.4%), moderate in 23 patients (17.1%), and poor in 10 patients (7.5%). The components of the functional evaluation, which mostly reflected the poor results in the latter 10 patients, were overall function, lifting ability, and emotional acceptance. Overall, patients who underwent intraarticular resection had better functional outcomes than did patients who underwent extraarticular resection (77% and 68% good to excellent, 19% and 20% moderate, and 4% and 12% poor functional outcomes, respectively). Patients who underwent types IVB, VB, and VIB shoulder resections (en bloc extraarticular resection of the shoulder joint with the deltoid muscle) had a loss of abduction and concavity of the affected shoulder because of resection of the deltoid muscle and axillary nerve with the tumor. These patients typically had preserved hand dexterity and intact range of motion of the elbow. Table 2 summarizes the type of resection, endoprosthetic reconstruction, and functional outcomes of the 134 patients.

Complications included five musculocutaneous, four radial, two anterior interosseous, and two ulnar nerve palsies, all of which were transient. It is assumed that these were the result of traction in surgery or were secondary to pressure of an inappropriately drained hematoma in the immediate postoperative period. Deep wound infection necessitating surgical intervention occurred in two patients (1.5%), one of whom required revision of his prosthesis. Clinically significant aseptic loosening occurred in one patient (0.7%). This patient underwent extraarticular proximal humerus resection with endoprosthetic reconstruction. The loosening occurred 6.5 years after surgery and required surgical revision.

Local recurrence developed in five patients (3.7%). Four of these recurrences occurred in patients who had a primary bone sarcoma; the other occurred in a patient who had a soft tissue sarcoma. Four patients with recurrences were treated with wide excision and adjuvant radiotherapy, and one patient required limb amputation. The overall recurrence and limb-salvage rates of a pri-



**Figure 9.** Total scapular endoprosthetic reconstruction. The endoprosthetic articulation between the scapula and the proximal humerus is reinforced with a Gore-Tex sleeve (WL Gore & Assoc, Flagstaff, AZ).

mary sarcoma of the shoulder girdle were 4.9% and 99%, respectively. At the most recent followup, 71 of the 103 patients with primary sarcoma of the shoulder girdle had no evidence of disease, 9 were alive with disease, and 23 were dead. Two of the 12 patients who had metastatic bone disease lived less than 1 year after surgery, 6 lived more than 1 year after surgery, and 4 lived more than 2 years after surgery.

## DISCUSSION

The purpose of this article is to describe the principles by which a limb-sparing resection of the shoulder girdle should be planned and done. It is based on our experience with 134 patients who had limb-sparing resection of a shoulder girdle tumor with a longterm followup.

**Table 2.** Type of Resection, Type of Reconstruction, and Functional Outcomes of 134 Tumors Treated by a Limb-Sparing Resection of the Shoulder Girdle

Resection type <sup>13</sup>	n	Proximal humerus prosthesis	Scapular prosthesis	Humeral head suspension	Functional outcomes* <sup>12</sup>			
					Excellent	Good	Moderate	Poor
IA	29	26	—	—	20	5	4	—
IB	7	7	—	—	3	3	1	—
IIA	5	—	—	—	4	1	—	—
IIB	12	—	—	—	8	4	—	—
IIIA	1	—	—	1	—	1	—	—
IIIB	15	—	3	12	6	3	4	2
IVA	—	—	—	—	—	—	—	—
IVB	8	4	4	—	4	2	1	1
VA	1	1	—	—	—	1	—	—
VB	53	53	—	—	4	31	11	7
VIA	—	—	—	—	—	—	—	—
VIB	3	1	2	—	—	1	2	—
Total	134	92	9	13	49	52	23	10

\*Functional outcomes presented here are based on each patient's followup evaluation at 2 years after surgery.

This is the largest report to date of limb sparing at this anatomic site.

A successful limb-sparing resection around the shoulder girdle mandates careful planning of the surgical approach, the extent of resection, and the means of bone and soft tissue reconstruction. A poorly performed surgery could result in a useless extremity and failure to achieve local tumor control, which would eventually result in an amputation. Familiarity with the surgical anatomy and patterns of tumor growth is essential. The aim of the preoperative physical examination and imaging studies is to evaluate bone and soft tissue extents of the tumor and their anatomic relation to the key anatomic structures of the shoulder girdle, and each imaging study used in the staging process should be evaluated in this regard; using these studies, the surgeon will be able to determine the tumor's resectability, extent of resection, and mode of reconstruction.

The utilitarian shoulder girdle incision that we use allows adequate exposure of the neurovascular bundle and resection of any extent of the humerus and scapula. Exposure and mobilization of the neurovascular bundle is a key and initial step of surgery; using the anterior arm of the utilitarian shoulder girdle incision, the pectoralis major tendon is exposed through the deltopectoral interval. The tendon is detached from its insertion site at the proximal humerus and is reflected medially. Detachment of the coracoid origins of the pectoralis minor, coracobrachialis, and the short head of the biceps muscle

and their caudal reflection reveals the neurovascular bundle.

Early reconstruction attempts after proximal humerus resections used a Kuntscher nail within the remaining humerus stump and suspension of the construct from the distal clavicle or the chest wall.<sup>9,11</sup> Although allowing a stable shoulder, which prevents the complications of a flail extremity, this mode of reconstruction did not allow optimal function. Instability, hardware failure, pain, and erosion through the skin or chest wall occurred frequently. The execution of a limb-sparing procedure in the majority of the patients and overall improvement in patients' survival imposed higher standards of durability and functional reconstructions. Although many surgeons agree on the extent of resection of a shoulder girdle tumor, the mode of reconstruction is controversial: current methods of skeletal reconstruction vary and include endoprosthetic reconstruction, osteoarticular allograft, prosthetic allograft composites, and resection-arthrodesis.<sup>14-19</sup>

Osteoarticular allografts, which were popular in the 1970s and 1980s, attempt to restore the natural anatomy of a joint by matching the donor bone to the recipient's anatomy. Reconstruction with an osteoarticular allograft is feasible when the abductor mechanism (the deltoid and rotator cuff) and glenoid are preserved; otherwise, allografts have no theoretical advantage over endoprosthetic reconstruction.<sup>20</sup> Retaining the abductor mechanism provides better function and appearance of

the reconstructed extremity, but because most high-grade sarcomas of the proximal humerus extend to the joint capsule and have an extraosseous component that lies underneath the deltoid muscle, en bloc extraarticular resection of these tumors with the deltoid muscle and axillary nerve is recommended to achieve wide margins.<sup>21,22</sup> Any compromise of this guideline might result in high rates of local recurrence. Jensen and Johnston<sup>23</sup> reported 19 proximal humeral resections and reconstruction for primary bone sarcomas. In that series, although 14 patients had an extraosseous component, intraarticular resection with preservation of the glenoid and most of the deltoid muscle was done in all patients. The local recurrence rate was 12%. Gebhardt and colleagues<sup>17</sup> reported 20 patients who underwent intraarticular proximal humerus resection with preservation of the deltoid muscle and allograft reconstruction for a variety of benign aggressive and malignant tumors. Two of three patients who were treated for an extraosseous primary sarcoma of bone had a local recurrence that necessitated forequarter amputation. Because of the common involvement of the deltoid muscle by direct tumor extension, the common intracapsular tumor extension through the joint capsule and biceps tendon, and the close proximity of the axillary nerve to the joint capsule and proximal humerus, we recommend en bloc extraarticular and deltoid resection for high-grade bone sarcomas of the proximal humerus. In selected cases in which the tumor is mostly intraosseous, the abductor mechanism can be spared.

A major concern exists about the longterm biologic properties of osteoarticular allografts. With time, these allografts are associated with major rates of infection, nonunion, instability, fracture, and subchondral collapse; O'Connor and colleagues<sup>18</sup> reported a series of 57 patients who underwent limb-sparing surgery around the shoulder girdle, 8 of whom underwent proximal humerus resection with osteoarticular allograft reconstruction. Of these eight patients, four (50%) had fracture and collapse of the articular and subchondral region. More recently, Getty and Peabody<sup>24</sup> reported 16 patients who underwent proximal humerus resection with osteoarticular reconstruction. They reported an extremely high rate of complications: 13 patients had mild to severe resorption of the implant, 4 patients had a fracture, and 1 patient had a deep infection.<sup>24</sup> At the most recent followup, 11 of the 16 patients had subluxation or dislocation of their allograft, and all had prominent hard-

ware as a result of resection or atrophy of the overlying deltoid muscle.<sup>24</sup> These authors noticed that, with time, the prevalence of the allograft-related complications increased and function decreased.<sup>24</sup> Because of the associated high risk of complications of osteoarticular allograft reconstruction and the oncologic necessity to do en bloc, extraarticular resection of the shoulder with the abductor mechanism for extraosseous primary bone sarcomas of the proximal humerus, we do not recommend the use of osteoarticular allografts for reconstruction after resection of these tumors.

Early shoulder girdle prostheses were custom manufactured on the basis of radiographic estimates of the intended surgical resection. The preoperative design and manufacturing processes required 8 to 10 weeks; this caused a delay in the timing of resections. A second drawback of custom-made prostheses was the difficulty in determining the actual length and width of the resected bone on the basis of imaging modalities alone. Any deviation in the surgical plan, whether caused by underestimation of tumor extension or error in the preoperative calculation, could jeopardize the planned reconstruction.

Introduced in the early 1980s,<sup>20,21</sup> modular proximal humerus prosthesis revolutionized endoprosthetic reconstruction. The modular system enables the surgeon to measure the actual bone defect at the time of surgery and select the most appropriate components to use in reconstruction. Design features include porous coating on the extracortical portion of the prostheses for bone and soft tissue fixation and metallic loops to assist in muscle reattachment. We currently use custom-made prostheses in cases requiring an unusual stem length or diameter.

Tumors of the scapula traditionally were treated with partial or total scapulectomy, which resulted in acceptable local tumor control, but function and cosmesis were impaired when total scapulectomy (sacrifice of the glenoid, either intraarticularly or extraarticularly) was done.<sup>8,25-28</sup> Within the past decade, the technique of scapular endoprosthetic reconstruction has been developed. It is considered for use after total scapulectomies, and its feasibility largely depends on the amount of soft tissues preserved. Scapular endoprosthetic reconstruction is possible only in cases where the periscapular musculature (the rhomboids, trapezius, and latissimus dorsi) can be spared. These muscles are essential for prosthetic coverage, stabilization, and proper limb function. Al-

though the number of patients who have undergone scapular endoprosthesis reconstruction is too small to make any valid statistical analyses, we think there is a functional advantage to prosthetic reconstruction over a flail extremity. Shoulder cosmesis and contour are improved.

In the current series of 101 prostheses in 134 patients, only 2 patients (2.0%) required revision of their prostheses. Aseptic loosening around the shoulder girdle was uncommon because the glenohumeral joint is not a weight-bearing joint, because its mobility allows an even distribution of forces around the bone-prosthesis interface, and because of the excellent blood supply of the shoulder girdle and availability of soft tissue for prosthetic coverage. Because of adequate coverage, deep infections also were rare.

The oncologic objective of limb-sparing resections of the shoulder girdle is to achieve local tumor control. Patient survival will be determined by the presence of metastatic disease and its response to adjuvant treatment modalities. The rate of local recurrence is the most appropriate criterion with which to evaluate the oncologic adequacy of a limb-sparing resection. In the current series, only 5 of 103 (4.9%) patients who were treated for primary sarcoma of the shoulder girdle had local recurrence. This rate of recurrence is below the 10% recurrence expected after limb-sparing resections.<sup>29,30</sup> The bone and soft tissue tumors in the current series represent a large spectrum of biologic behaviors and prognoses. Presenting detailed information on neoadjuvant and adjuvant treatment modalities and oncologic outcomes is beyond the scope of this article, which focuses on surgical guidelines for shoulder girdle resections.

Limb-sparing resections of the shoulder girdle are safe and reliable. Meticulous preoperative evaluation and planning the extent of resection and mode of reconstruction are mandatory. Good local tumor control, functional outcomes, and an acceptable rate of complications were achieved. We advocate the use of the utilitarian shoulder incision and endoprosthesis for reconstruction.

#### Author Contributions:

Study conception and design: Bickels, Kollender, Meller, Malawer

Acquisition of data: Bickels, Wittig, Kellar-Graney

Analysis and interpretation of data: Bickels, Kellar-Graney

Drafting of manuscript: Bickels, Wittig, Malawer

Critical revision: Bickels, Wittig, Kollender, Meller, Malawer

#### REFERENCES

1. Dorfman HD, Czerniak B. General considerations. In: Dorfman HD, Czerniak B, eds. Bone tumors. St Louis: CV Mosby; 1998:1–33.
2. Dorfman HD, Czerniak B. Metastatic tumors in bone. In: Dorfman HD, Czerniak B, eds. Bone tumors. St Louis: CV Mosby; 1998:1009–1040.
3. Sim FH, Pritchard DJ, Ivins JC. Forequarter amputation. *Orthop Clin North Am* 1977;8:921–931.
4. Meterissian SH, Reilly JA Jr, Murphy A. Soft-tissue sarcomas of the shoulder girdle: factors influencing local recurrence, distant metastases, and survival. *Ann Surg Oncol* 1995;2:530–536.
5. Ham SJ, Hoekstra HJ, Eisma WH, et al. The Tikhoff-Linberg procedure in the treatment of sarcomas of the shoulder girdle. *J Surg Oncol* 1993;53:71–77.
6. Malawer MM. Tumors of the shoulder girdle: technique of resection and description of a surgical classification. *Orthop Clin North Am* 1991;22:7–35.
7. Linberg BE. Interscapulothoracic resection for malignant tumors of the shoulder joint region. *J Bone Joint Surg* 1928;10:344–349.
8. Burwell HN. Resection of the shoulder with humeral suspension for sarcoma involving the scapula. *J Bone Joint Surg* 1965;47B:300–303.
9. Francis KC, Worcester JN. Radical resection for tumors of the shoulder with preservation of a functional extremity. *J Bone Joint Surg* 1962;44A:1423–1430.
10. Janecki CJ, Nelson CL. En bloc resection of the shoulder girdle: technique and indications. Report of a case. *J Bone Joint Surg* 1972;54A:1754–1758.
11. Marcove RC, Lewis MM, Huvos AG. En bloc upper humeral interscapulothoracic resection. *Clin Orthop* 1977;124:219–228.
12. Enneking WF, Dunham W, Gebhardt MM, et al. A system for functional evaluation of reconstructive procedures after surgical treatment of tumors of the musculoskeletal system. *Clin Orthop* 1993;286:241–246.
13. Malawer MM, Meller I, Dunham WK. A new surgical classification system for shoulder girdle resections: analysis of 38 cases. *Clin Orthop* 1991;267:33–44.
14. Bos G, Sim F, Pritchard D, et al. Prosthetic replacement of the proximal humerus. *Clin Orthop* 1987;224:178–191.
15. Burrows HJ, Wilson JN, Scales JT. Excision of tumours of humerus and femur with restoration by internal prosthesis. *J Bone Joint Surg* 1975;57B:148–159.
16. Cheng EY, Gebhardt MC. Allograft reconstructions of the shoulder after bone tumor resections. *Orthop Clin North Am* 1991;22:37–48.
17. Gebhardt MC, Roth YF, Mankin HJ. Osteoarticular allografts for reconstruction in the proximal part of the humerus after excision of a musculoskeletal tumor. *J Bone Joint Surg* 1990;72A:334–345.
18. O'Connor MI, Sim FH, Chao EYS. Limb salvage for neoplasms of the shoulder girdle. Intermediate reconstructive and functional results. *J Bone Joint Surg* 1996;78A:1782–1888.

19. Parrish FF. Allograft replacement of all or part of the end of a long bone following excision of a tumor: report of twenty-one cases. *J Bone Joint Surg* 1973;55A:1-22.
20. Campanacci M, Capanna R, Cervellati C, et al. Modular rotatory endoprosthesis for segmental resections of the proximal humerus: experience with thirty-three cases. In: Chao EYS, Irvins JC, eds. *Tumor prostheses for bone and joint reconstruction: the design and application*. New York: Thieme-Stratton; 1983:127-139.
21. Malawer MM, Sugarbaker PH. Shoulder girdle resections: the Tikhoff-Linberg procedure and its modifications. In: Sugarbaker PH, Malawer MM, eds. *Musculoskeletal surgery for cancer*. New-York: Thieme Medical Publishers; 1992:346-360.
22. Meller I, Bickels J, Ovadia D, et al. Excision of malignant bone and soft tissue tumors of the shoulder girdle: a retrospective analysis of 30 cases. *Acta Scand Orthop* 1997;68:374-380.
23. Jensen KL, Johnston KO. Proximal humeral reconstruction after excision of a primary sarcoma. *Clin Orthop* 1995;311:164-175.
24. Getty PJ, Peabody TD. Complications and functional outcomes of reconstructions with an osteoarticular allograft after intra-articular resection of the proximal aspect of the humerus. *J Bone Joint Surg* 1999;81A:1138-1146.
25. Malawer MM, Sugarbaker PH, Lampert M. The Tikhoff-Linberg procedure: report of ten patients and presentation of a modified technique for tumors of the proximal humerus. *Surgery* 1985;97:518-528.
26. Gibbons CL, Bell RS, Wunder JS, et al. Function after subtotal scapulectomy for neoplasm of bone and soft-tissue. *J Bone Joint Surg* 1998;80B:38-42.
27. Markhede G, Monastyrski J, Stener B. Scapulectomy for malignant tumor: function and shoulder strength in five patients. *Acta Orthop Scand* 1985;56:332-336.
28. Papaioannou AA, Francis KC. Scapulectomy for the treatment of primary malignant tumors of the scapula. *Clin Orthop* 1965;135:165-170.
29. Asavamongkolkul A, Eckardt JJ, Eilber FR, et al. Endoprosthetic reconstruction for malignant upper extremity tumors. *Clin Orthop* 1999;360:207-220.
30. Peabody TD, Eckardt JJ. Complications of prosthetic reconstruction. In: Simon MA, Springfield D, eds. *Surgery for bone and soft-tissue tumors*. Philadelphia: JB Lippincott Company; 1998:467-479.