

17

Forequarter Amputation

Martin Malawer and Paul Sugarbaker

OVERVIEW

Forequarter amputation entails surgical removal of the entire upper extremity, scapula, and clavicle. It was traditionally used for the treatment of high-grade bone sarcomas of the shoulder girdle, particularly osteosarcomas of the proximal humerus and scapula. Other indications included large and high-grade sarcomas of the axilla, brachial plexus and the suprascapular area of the shoulder.

As a result of advances in limb-sparing surgery for bony and soft-tissue sarcomas, forequarter amputation is rarely performed today. Only 5–10% of patients with primary bony sarcomas, and less than 5% of those with soft-tissue sarcomas of the shoulder, require a forequarter amputation.

Today, forequarter amputation generally is performed only for extremely large tumors arising from the proximal humerus or scapula. These lesions are usually associated with fracture, tumor-hemorrhage, fungation, infection, and/or axillary and brachial plexus involvement.

Preoperative evaluation entails examination and imaging of the potential margins of resection, particularly the underlying chest wall, paraspinal muscles, thoracic outlet and the posterior triangle of the neck. Extension into any of these areas may make it impossible to obtain surgical margins. At surgery the patient is placed in a semilateral position. The utilitarian surgical incision (see Chapter 33) is used. A semi-lateral position is used at surgery. The axillary vessels are exposed anteriorly and ligated, and the posterior structures are then released from the large, posterior, midline-based incision. Rehabilitation is begun prior to discharge from the hospital. Prostheses are available and are generally used only for cosmesis.

INTRODUCTION

Forequarter amputation (interscapulothoracic amputation) entails the surgical removal of the entire upper extremity and shoulder girdle, including the scapula and a portion of the clavicle.^{1,2} Traditionally forequarter amputations were most commonly performed for high-grade bone sarcomas of the proximal humerus and scapula (Figure 17.1). The proximal humerus is the third most common site for osteosarcomas, and these tumors are the most common primary malignancy of the proximal humerus. Chondrosarcomas and Ewing's sarcoma tend to occur in the scapula.

Until the 1970s most of these tumors were treated by forequarter amputation. In addition, some soft-tissue sarcomas of the periscapular and axillary area require forequarter amputation for local control due to neurovascular involvement.

Fortunately, forequarter amputation is rarely performed today. Approximately 90–95% of patients with bony sarcomas of the shoulder girdle can be treated with limb-sparing resection and adjuvant therapy, following the guidelines outlined in this book. Today, the most common indication for amputation of a proximal humeral osteosarcoma is failure to respond to induction chemotherapy and/or tumor progression. Finally, although rare, soft-tissue sarcomas of the supraclavicular or infraclavicular portion of the brachial plexus, and tumors involving the axillary vessels, still are best managed by a forequarter amputation.

UNIQUE ANATOMIC CONSIDERATIONS

The upper extremity and scapula are attached to the upper torso and chest wall by the rhomboid, levator scapulae, trapezius, pectoralis major and minor, latissimus dorsi, teres major, and serratus anterior muscles. During a forequarter amputation these muscles must be transected. The rotator cuff muscles, which consist of the supraspinatus, infraspinatus, subscapularis, and teres minor, and aid in humeral head suspension, are removed. The most significant structures that must be evaluated prior to surgery are the axillary and brachial vessels and the adjacent infraclavicular portion of the brachial plexus. These structures pass below the mid-portion of the clavicle and down the arm adjacent to the inferior border of the coracobrachialis muscle. The coracoid can be easily palpated to identify the brachialis plexus and axillary vessels that pass just inferior to it and lie below the deltopectoral fascia. The axillary vessels are routinely evaluated in order to determine the segment that can be safely transected, especially since large tumors may come close to the thoracic outlet.

Other important structures that must be evaluated prior to amputation are the posterior triangle of the

neck, the adjacent paraspinal (thoracic) musculature, and the underlying chest wall. Tumors of the periscapular area may easily extend into these structures. Involvement of these structures makes an amputation inadvisable because negative margins may not be attainable.

STAGING STUDIES

Computerized Tomography (CT) and Magnetic Resonance Imaging (MRI)

These studies accurately evaluate the potential soft-tissue margins; i.e. the neck, paraspinal muscles and chest wall.

Angiography

Angiography is extremely helpful in determining the anatomic position of the axillary and/or brachial vessels, and evaluating whether these structures are involved by tumor. Occasionally, anomalies (e.g. a duplicate axillary artery) are identified. Angiography also makes it possible to accurately determine the level of ligation of the axillary vessels.

Venography

No imaging studies can accurately determine whether the brachial plexus is infiltrated by tumor or whether the vessels and plexus are simply displaced. All of the above imaging studies provide only indirect evidence of tumor extension to the nerves. We have found venography of the axillary veins to be a simple and accurate method of determining brachial plexus involvement. A brachial venogram will show complete obstruction of the main axillary veins when tumor is infiltrating the brachial plexus, whereas a tumor adjacent to, but not infiltrating, the plexus will show venous patency and displacement.

BIOPSY

The biopsy site should follow the incision for a forequarter amputation so that it can be easily removed with the amputation. Care should be taken not to contaminate the large posterior flap, deltopectoral interval, suprascapular area (especially near the neck) and the pectoralis muscle. Large proximal humeral tumors should be biopsied through the anterior deltoid. Scapula tumors should be biopsied along the axillary border, which is in line with the amputation incision.

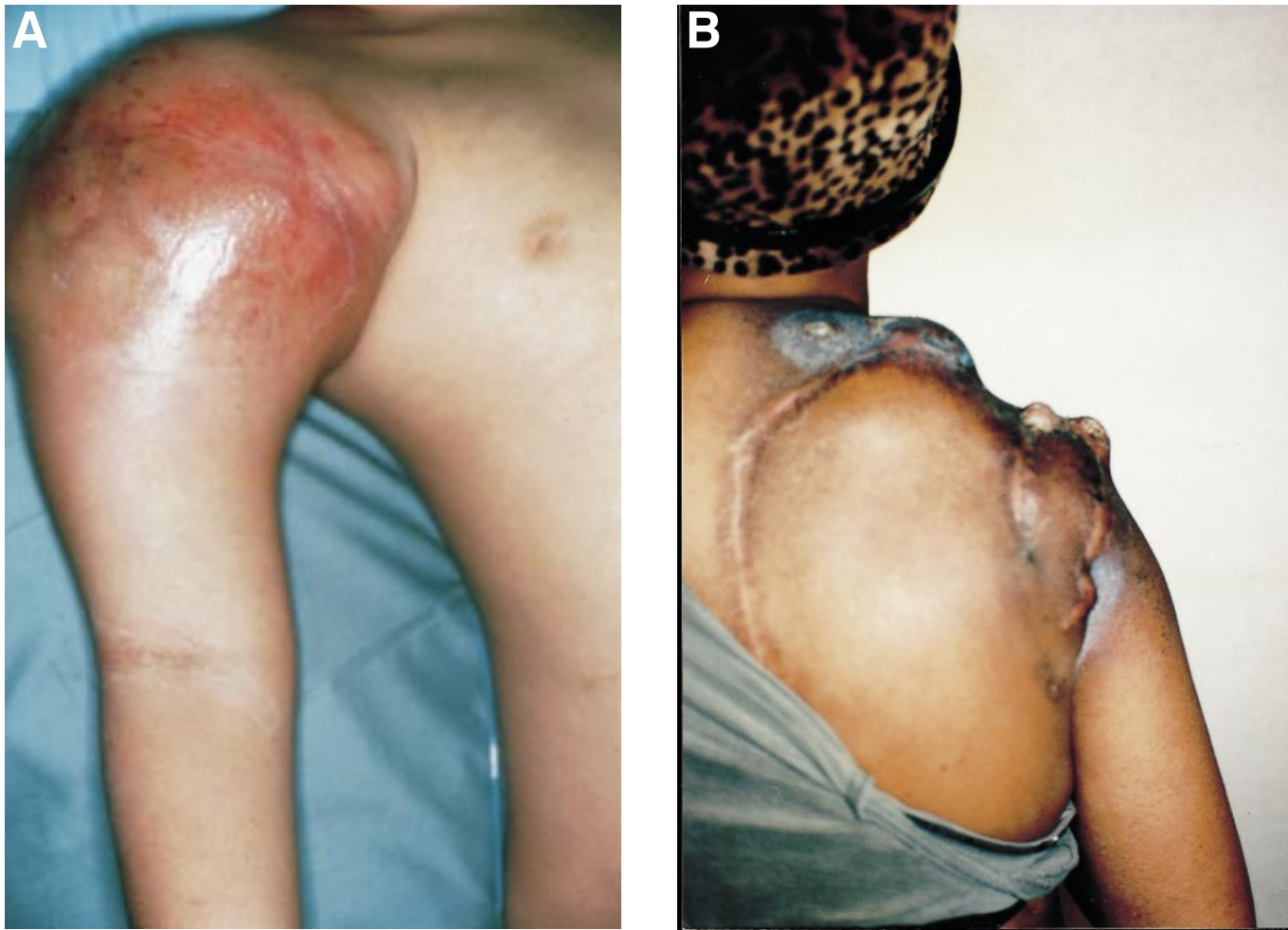


Figure 17.1 Two different patients requiring a forequarter amputation in lieu of a limb-sparing procedure. (A) A large telangiectatic osteosarcoma of the right proximal humerus that involves the entire shoulder circumferentially. (B) Multiple recurrent tumor nodules following a failed limb-sparing surgical procedure [Tikhoff-Linberg (Type IV) procedure] for a very aggressive multiple recurrent leiomyosarcoma. There are multiple tumor nodules along the entire previous suture line. This patient received radiation therapy prior to amputation.

INDICATIONS AND CONTRAINDICATIONS

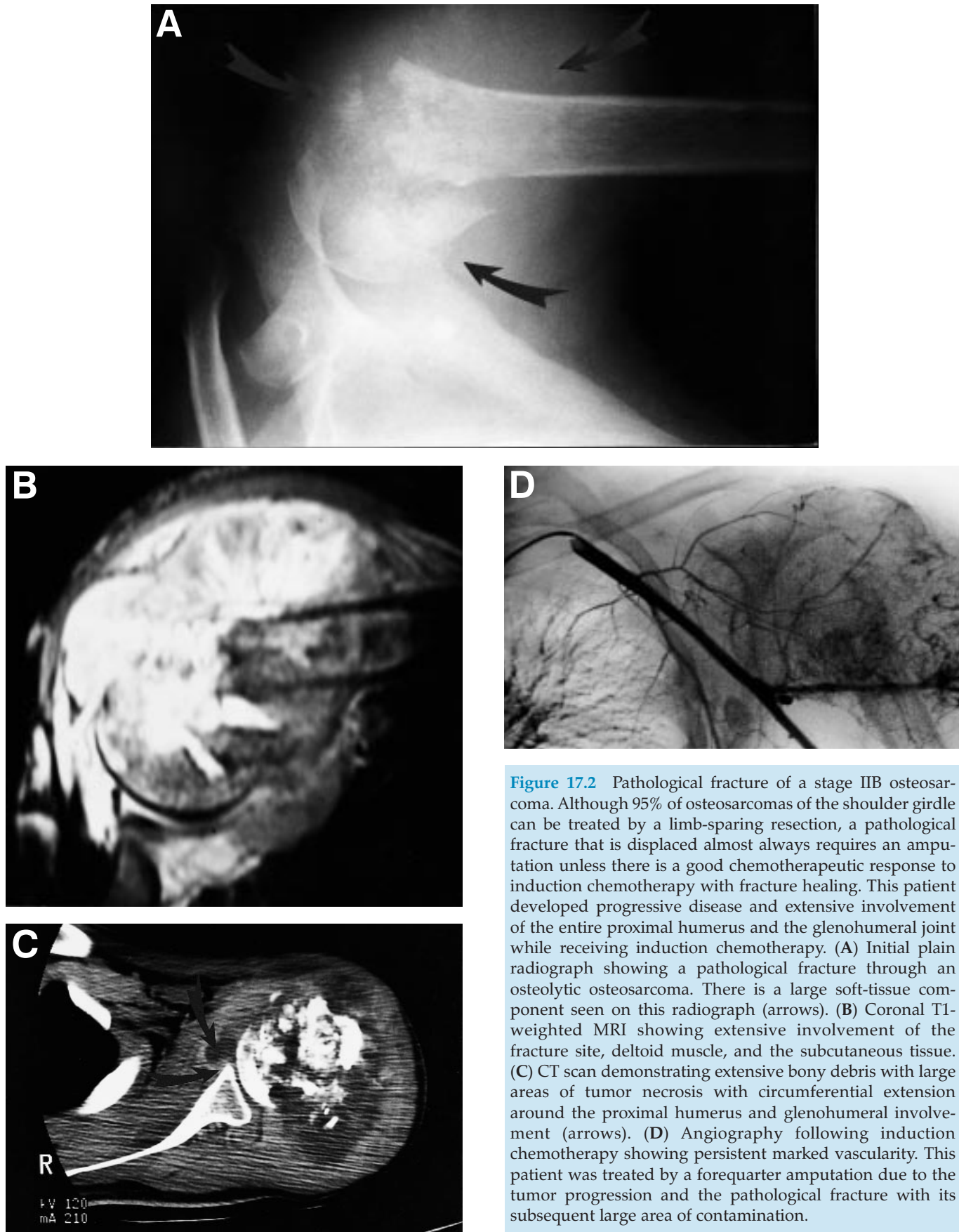
The major indications for forequarter amputation are as follows:

1. Unresectable high-grade osteosarcoma (or any other high-grade tumor) of the proximal humerus or the scapula (most commonly, chondrosarcoma).
2. Axillary soft-tissue sarcomas involving the brachial plexus.
3. Recurrent bone or soft-tissue sarcomas following a failed limb-sparing procedure.
4. Some radiation-induced sarcomas of the shoulder girdle.
5. Palliative amputation (primarily due to tumor fungation, infection, or bleeding).
6. Recurrent breast carcinoma involving the brachial plexus.
7. Pathological fracture through a high-grade sarcoma, especially if there is a poor response to induction chemotherapy (Figure 17.2).

Forequarter amputation is contraindicated when tumor extends to the chest wall. It is likewise contraindicated when tumor extends to the paraspinal and posterior triangle of the neck structures, because in this situation negative margins may not be obtained.

SURGICAL GUIDELINES

Several surgical techniques have been described for performing a forequarter amputation. We recommend a semilateral approach. The patient is placed in a lateral position and the majority of the surgery is performed anteriorly. The axillary vessels and brachial plexus are



exposed anteriorly and not posteriorly. The posterior approach alone has been found to be unreliable and dangerous for most large tumors of the scapula and suprascapula area. Anterior exposure is especially important when a large tumor has displaced the axillary and subclavian vessels. It would be extremely difficult to identify and avoid harming these structures from a strictly posterior approach.

- We recommend that the anterior limb of the utilitarian incision be utilized to perform an anterior exploration and to mobilize the brachial plexus and axillary nerves.
- Anterior vascular exploration is performed by detaching the pectoralis major muscle from the clavicle. A clavicular osteotomy is performed at the proximal one-third junction. Once these nerves are identified, a Statinski clamp can be placed high along the vessels that lie beneath the clavicle. Surgery can then proceed in an orderly manner.
- The posterior approach is utilized to detach the scapula from the rhomboid, trapezius, and the

levator scapulae and latissimus dorsi muscles. The scapula is lifted from the chest wall by detaching the latissimus dorsi at its lowest points. This exposes the posterior chest wall and makes it possible to perform a manual examination.

- The surgeon can place his or her hand into the axillary space to determine whether there is chest wall or intercostal muscle involvement. If not, the planned amputation can proceed. If there is chest wall involvement, a combined chest wall/forequarter amputation can be performed.
- Axillary incision is made to connect the anterior and posterior incisions.
- The entire forequarter is removed after ligation and transection of the brachial plexus and subclavian vessels.
- The large posterior flap is easily closed over the remaining chest wall defect.
- A marcaine catheter is placed into the remaining brachial plexus for postoperative pain relief. A 28-gauge chest tube is used for drainage for 48–72 h.

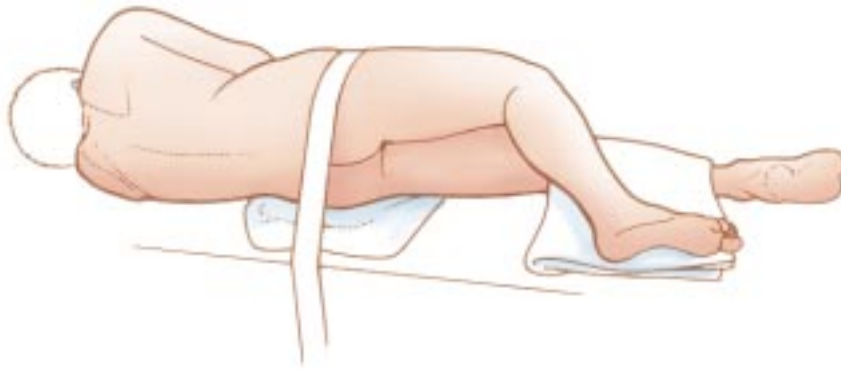

Figure 17.3 Position. Intravenous lines are secured, and a Foley catheter is placed in the bladder. The patient is placed in a full lateral position and secured at the hips with tape. Alternatively, a VAC pack can be used to secure the torso. An axillary roll is placed under the axilla to allow full excursion of the chest, and a sponge-rubber pad is placed under the hip to prevent ischemic damage to the skin in this area. The skin is prepared, and the tumor-bearing extremity is draped free.

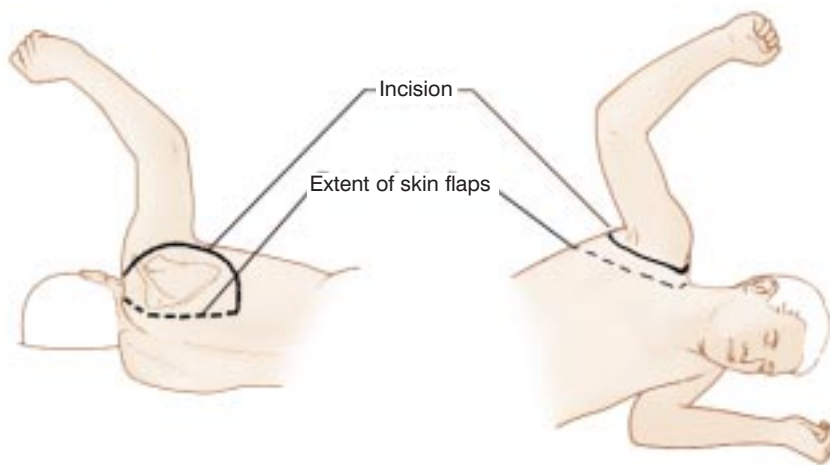


Figure 17.4 Incision and skin flaps. The incision starts over the clavicle about 1 inch lateral to the sternoclavicular joint. The medial line of incision is in or near the deltopectoral groove; the lateral line crosses the tip of the acromion. These lines meet below the axilla; the surgeon must be sure to excise all of the skin bearing axillary hair. The position of the lines of excision will vary with tumors in different positions. In the patient shown, a hematoma over the deltoid muscle anteriorly required that the anterior skin flap be moved further forward than usual. Because of the excellent blood supply to the skin in this region, long anterior or posterior flaps uniformly survive even though closed under considerable tension. If a tumor mass has extensive skin involvement, the flaps that remain should be secured to the chest wall with absorbable suture material, and the remaining defect covered with split-thickness skin graft.

The surgeon stands posterior to the patient. The posterior skin flap is usually constructed first. The flaps are constructed as thick as possible so that dissection is usually on the muscle fascia. It is usually possible to widely sacrifice skin around a tumor mass or a previous biopsy site so that thin skin flaps are usually unnecessary. Hematoma that results from the biopsy should always be included within the operative specimen. The posterior skin flap is elevated back to the medial border of the scapula. If a long posterior skin flap is required, this dissection may go back to the vertebral spines. The anterior skin flap is elevated back to the anterior axillary line. If a long anterior flap is required, the flap can extend back to the mid-sternum.

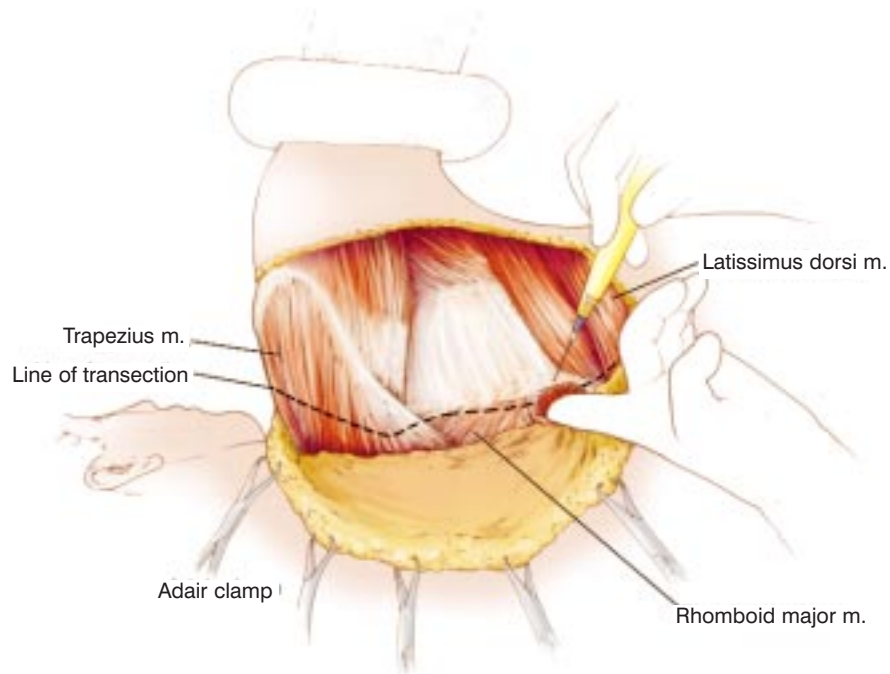


Figure 17.5 Transection of posterior muscular attachments of the scapula. An incision in the deep fascia at the mid-portion of the posterior border of the scapula allows the surgeon to pass a finger beneath the scapula. Electrocautery is then used to divide the rhomboid muscles (major and minor), trapezius muscle, and levator scapulae muscles as they insert onto the scapula. Moving caudally, the surgeon transects the latissimus dorsi.

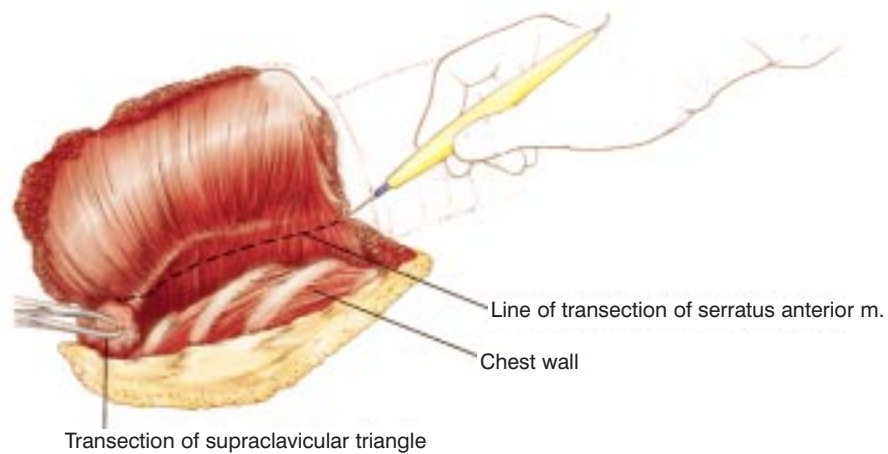


Figure 17.6 Division of contents of the supraclavicular triangle and serratus anterior muscle. Elevation of the scapula allows the structures of the supraclavicular triangle to be divided between hemostats. This includes the transverse cervical and transverse scapular arteries, many lymphatic channels, and the omohyoid muscle. Care is taken to sweep the contents of the axilla into the surgical specimen. The serratus anterior muscle is divided at its origin on the chest wall. This clearly exposes the neurovascular bundle.

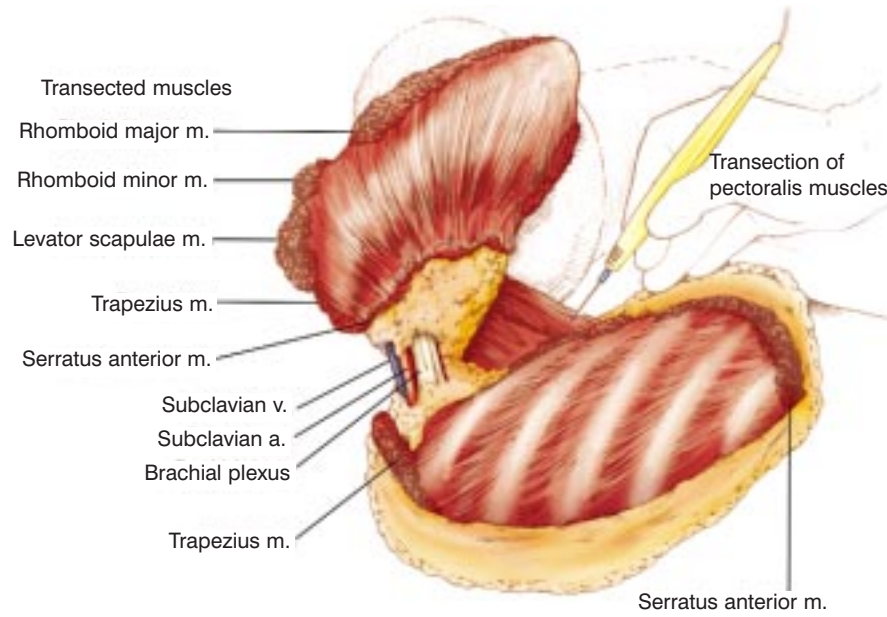
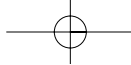


Figure 17.7 Transection of the pectoralis muscles, clavicle, and neurovascular bundle. Anteriorly, the pectoralis major and pectoralis minor muscles are divided. Elevation of the inferior angle of the scapula allows these muscles to be divided under tension by using electrocautery with minimal blood loss. The clavicular head of the sternocleidomastoid muscle is severed from this bone. The clavicle is disarticulated from its sternoclavicular joint. Subclavian vein and artery are ligated, divided, and then suture-ligated. The three large nerve bundles are ligated and then transected.

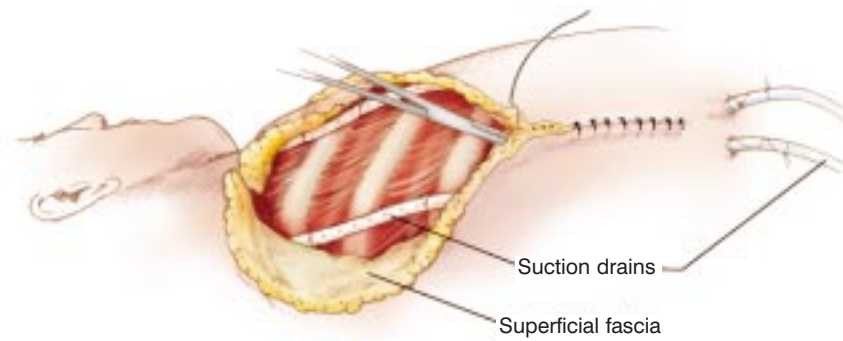
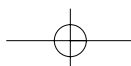


Figure 17.8 Closure. The area is copiously irrigated. Generous suction drainage under the anterior and posterior skin flaps is secured. A marked inequality of the anterior and posterior skin flaps exists. Marked redundancy of the skin may present an unacceptable cosmetic appearance unless the skin flaps are carefully approximated. The mid-portion of the long posterior skin flap is closed to the mid-portion of the anterior flap. Having the closure in this way pleats the longer posterior skin flap and prevents unsightly folds of skin. A two-layered closure of superficial fascia and then skin is used. Suction drains are removed when serous drainage is minimal.

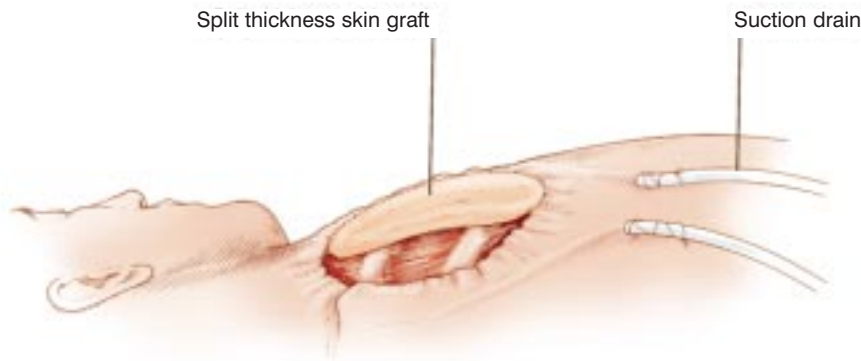

Figure 17.9 Split-thickness graft used to cover the chest wall in tumors with skin infiltration over a wide area.



DISCUSSION

Forequarter amputation is the removal of the entire upper extremity as well as the scapula and a portion of the clavicle. Traditionally, this procedure was the recommended method of treatment of shoulder-girdle sarcomas, both bone and soft-tissue. Today, most osteosarcomas of the proximal humerus are treated with a limb-sparing resection. It is rare for a soft-tissue sarcoma to be unresectable. Amputation is usually required for recurrent soft-tissue sarcomas or those bony lesions that fail induction chemotherapy.

The most common indications for forequarter amputation today are unresectable bone and soft-tissue sarcomas, axillary sarcomas that involve the brachial plexus and axillary artery, recurrent sarcomas following radiation therapy or those bony tumors that progress on induction chemotherapy. Tumor recurrence around the shoulder girdle is a major problem when it occurs. If multiple local resections and radiation therapy fail, the only alternative often is a forequarter amputation. More recently, patients with locally recurrent breast carcinoma (without metastatic disease) that extensively involve the shoulder, the pectoralis muscle, and/or the brachial plexus may require a palliative forequarter amputation.

Before a forequarter amputation is performed, it is important to ascertain that all surgical margins will be free of tumor. Thus, it is important to evaluate the following close anatomic structures that are not removed: the chest wall, posterior triangle of the neck, and the thoracic paraspinal muscles. If these planes are clear, an amputation can proceed.

No imaging studies can adequately determine brachial plexus involvement. Brachial venography can be extremely valuable in determining whether the brachial plexus is involved by tumor or simply displaced. When tumor is infiltrating the brachial plexus, a brachial venogram will show complete obstruction of the main brachial veins and axillary vein. Simple displacement would not occlude the venous structures.

Brachial venography, in conjunction with a careful physical examination, is the key to determining brachial plexus involvement. Patient complaints of nerve pain or weakness, combined with a positive brachial venogram, generally indicate tumor invasion of the brachial plexus, not simple displacement. In some cases nerve pain or actual sensory motor loss, combined with brachial and axillary venography showing an obstruction, is pathognomonic of brachial plexus invasion by

tumor. This is a clear indication of the need for forequarter amputation.

Palliative forequarter amputation remains an important procedure in the treatment of large, bulky sarcomas of the shoulder girdle as well as breast carcinomas that recur following multiple procedures and radiation therapy. Unfortunately, a significant number of women develop locally recurrent disease in the axilla, pectoralis major muscle, or of the adjacent clavicle or shoulder girdle. This, combined with previous radiation and the resultant lymphedema, as well as a brachial plexus neuropathy, may often leave the patient with a useless extremity. This combination of recurrent tumor, brachial plexus neuropathy, shoulder-girdle involvement, unresolvable pain, and inevitable tumor fungation, bleeding, and infection requires that a palliative forequarter amputation be performed with individualized types of flaps or skin grafts. This often is required, even in the face of metastatic disease. It is even more appropriate when there is no evidence of metastatic disease; in this case the procedure may be considered curative.

The surgical procedure utilized for palliative forequarter amputation differs from the standard amputation presented in this chapter in that it entails the development of a large posterior fasciocutaneous flap that involves the arm skin, extending from the shoulder to the elbow from the middle to lateral aspects posteriorly. This large flap is extremely vascular and can be rotated to close the chest wall defect. This technique has been utilized in cases of major crush injuries to the upper extremity and shoulder girdle, as well as following massive gunshot wounds. It has found a place in the treatment of the oncological patient when there has been previous radiation therapy to the skin flaps combined with massive recurrent tumor, with or without infection. The outcome of this operative procedure can be satisfactory. The patient is almost immediately relieved of infection and pain and can proceed with the remainder of his/her life on a very functional basis.

Phantom pain (causalgia) is a major problem following high-level amputations. We use an epineural catheter placed into the axillary sheath at the time of surgery and infuse 0.25% marcaine for 3–5 days postoperatively. This decreases postoperative pain and may decrease late causalgia syndromes. Although forequarter amputation is rarely performed today, it can be a life-saving procedure as well as providing a long-term palliative benefit.

References

1. Fanous N, Didolkar MS, Holyoke ED *et al.* Evaluation of forequarter amputation in malignant diseases. *Surg Gynecol Obstet.* 1976;142:381-4.
2. Sim FH, Pritchard DJ, Ivins JC. Forequarter amputation. *Orthop Clin N Am.* 1977;8:921-31.