

2

Biopsy of Musculoskeletal Tumors

Jacob Bickels, James Jelinek, Barry Shmookler and
Martin Malawer

OVERVIEW

Biopsy is a key step in the diagnosis of bone and soft-tissue tumors. An inadequately performed biopsy may fail to allow proper diagnosis, have a negative impact on survival, and ultimately necessitate an amputation to accomplish adequate margins of resection. Poorly performed biopsy remains a common finding in patients with musculoskeletal tumors who are referred to orthopedic oncology centers. The principles by which an adequate and safe biopsy of musculoskeletal tumors should be planned and executed are reviewed and a surgical approach to different anatomic locations is emphasized.

INTRODUCTION

Biopsy is a key step in the diagnosis of a musculoskeletal tumor. In a book published in 1958, Jaffe stated that a biopsy should be regarded as the final diagnostic procedure, not as a mere short cut to diagnosis.¹ Biopsy must be preceded by careful clinical evaluation and analysis of the imaging studies. The diagnosis of a musculoskeletal lesion is based on these three parameters; all three have to fit and the diagnosis must be questioned when they do not match.¹ In the past, biopsies were performed routinely through a large incision with significant contamination of the surrounding soft tissues with tumor cells. The contamination, however, had minimal significance because most malignant tumors of the extremities and pelvis were treated with amputation. Today, limb-sparing procedures are performed in 90–95% of patients with musculoskeletal tumors of the extremities, and indications and surgical technique of musculoskeletal biopsy had to be changed to allow these procedures to be performed.^{2,3}

The presence of a bone or soft-tissue lesion does not necessarily merit a biopsy. The combination of medical history, thorough physical examination, laboratory data when indicated, and appropriate imaging studies allows accurate diagnosis of most musculoskeletal lesions. Clinically and radiologically benign-appearing lesions do not have to have a biopsy. In contrast, biopsy is indicated in benign aggressive, malignant, and questionable lesions to confirm the clinical diagnosis and accurately classify the lesion before initiation of definitive treatment.

Technically, most biopsies are simple. Decisions regarding the indication for biopsy, the specific region of the lesion that has to have a biopsy, and the anatomic approach and biopsy technique can make the difference between a successful biopsy and a catastrophe. A poorly performed biopsy could become an obstacle to proper diagnosis and may have a negative impact on survival. Furthermore, patients who have undergone poorly performed biopsies subsequently may require an amputation to achieve an adequate surgical resection.

In 1982, Mankin *et al.*⁴ evaluated 329 patients who underwent biopsy for bone or soft-tissue sarcomas. The rate of major errors in diagnosis was 18.2%, and the rate of complications was 17.3%. Unnecessary amputations were performed in 4.5% of these patients.⁴ These events were found to occur with far greater frequency when the biopsy was performed in a referring institution rather than in a specialized oncology center. In addition to technical recommendations (most of which will be discussed in this chapter), it was

recommended that if a surgeon or an institution is not equipped to perform accurate diagnostic studies or definitive surgery and adjunctive treatment of musculoskeletal tumors, the patient should be referred to a specialized treating center before the biopsy is performed.⁴ In 1996, Mankin *et al.*⁵ performed a second study on 597 patients. They documented major errors in diagnosis in 13.5% of the patients, a complication rate of 15.9%, and unnecessary amputations in 3%. The differences in outcome between referring and oncology centers were unchanged and their recommendation was identical.⁵

The current chapter reviews the principles according to which a safe and adequate biopsy of bone and soft-tissue tumors should be planned and performed.

BIOLOGY OF MUSCULOSKELETAL TUMORS

Because of the common origin from the mesenchymal elements of the musculoskeletal system, bone and soft-tissue sarcomas share certain unique biologic characteristics. Sarcomas grow in a centripetal fashion with the most immature part of the lesion at the growing edge. A reactive zone is formed between the tumor and the compressed surrounding normal tissues. The reactive zone is composed of induced proliferation of mesenchymal cells, neovasculature, and inflammatory process.⁶ The type of mesenchymal proliferation is determined by the anatomic location of the tumor: soft-tissue tumors stimulate a fibrous reaction, and intraosseous lesions stimulate a bone-forming reaction. Furthermore, the same lesion in different areas will stimulate different mesenchymal responses. The reactive region around an intraosseous lesion matures into reactive bone, whereas if the lesion penetrates the soft tissues, the mesenchymal response is fibrous.^{6,7} Unlike sarcomas, carcinomas usually infiltrate, rather than push, the surrounding tissues and usually do not induce the formation of a reactive zone.⁸

The reactive zone may be invaded by tumor nodules that represent microextensions of tumor. These nodules are termed satellites and are not a metastatic phenomenon. High-grade sarcomas may present with tumor nodules that grow outside the reactive rim but within the same anatomic compartment in which the lesion is located. These nodules are termed skip lesions (Figures 2.1, 2.2).^{2,7} Low-grade sarcomas rarely manifest with skip lesions.⁶ Metastatic disease from bone and soft-tissue sarcomas is site-specific; it is manifested by lung involvement in its early stage and secondarily by bone involvement.^{2,9}

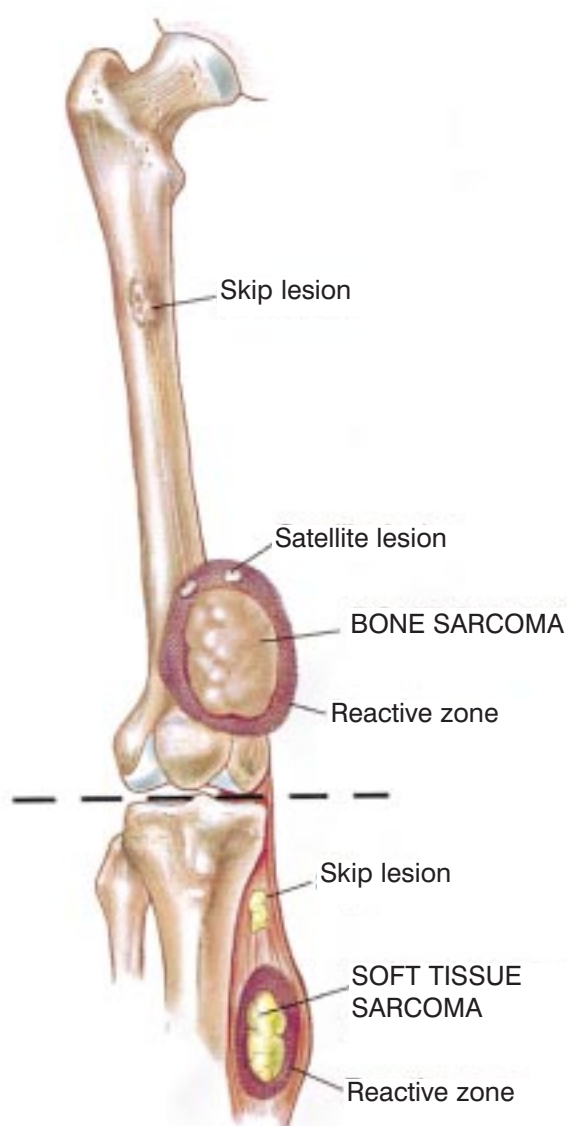


Figure 2.1 Growth pattern of bone and soft-tissue sarcomas. Sarcomas grow in a centripetal fashion, with the most immature part of the lesion at the growing edge. A reactive zone is formed between the tumor and the compressed surrounding normal tissues and may be invaded by tumor nodules that represent microextensions of tumor (satellites) and are not a metastatic phenomenon. High-grade sarcomas may present with tumor nodules that grow outside the reactive zone (skip lesions) but within the same anatomic compartment in which the lesion is located.

DIAGNOSTIC STUDIES AND BIOPSY CONSIDERATIONS

Biopsy of a musculoskeletal lesion should be performed only at the conclusion of staging, which is the process that entails performing the imaging studies required to determine the characteristics and local extent of the tumor and the presence of metastatic disease. Staging

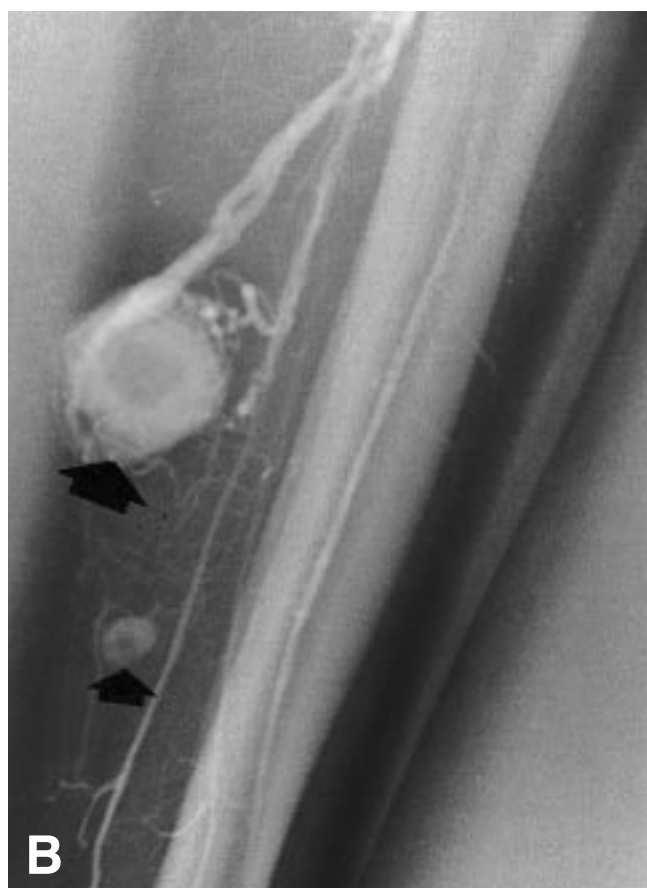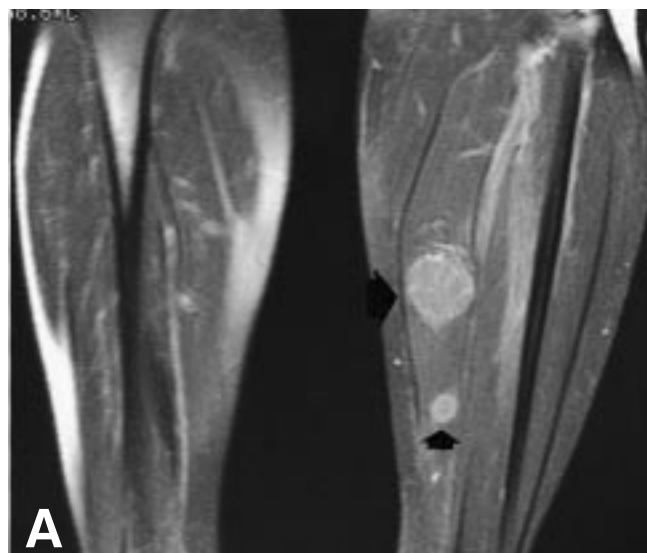


Figure 2.2 A 40-year-old woman presented with a rapidly enlarging mass that had developed in her calf. Physical examination revealed a deep-seated, firm mass, 10 cm in diameter, located at the proximal aspect of the calf. (A) Magnetic resonance imaging revealed the primary lesion and additional skip metastasis in the substance of the soleus muscle. Core needle biopsy of the primary lesion established the diagnosis of a high-grade leiomyosarcoma. (B) The skip metastasis is shown clearly in an angiogram performed before radical excision of the tumors.

helps determine the exact anatomic approach to the tumor and specifies the region of the tumor that represents the underlying disease. A final reason for deferring biopsy until staging is complete is that biopsy superimposes real and artificial radiologic changes at the biopsy site, and therefore can alter the interpretation of the imaging studies.

Anatomic Location of the Biopsy Tract

The position of the biopsy site within the lesion has a major significance because bone and soft-tissue tumors may have regional morphologic variations.^{2,6,7} As a result of that heterogeneity, multiple samples are required to establish a diagnosis. Carcinomas, by contrast, are commonly homogeneous and a single tissue core or aspirate is sufficient for diagnosis. The term "sampling error" refers to an incorrect or inconclusive diagnosis that occurs because the biopsy specimen was taken from a region that does not represent the underlying primary disease. The clinical findings and imaging studies must be evaluated before biopsy by the surgeon and the radiologist, who must be familiar with the biologic and radiologic findings of musculoskeletal tumors. The questions that must be answered before biopsy are: (1) What part of the lesion has to have a biopsy? and (2) What is the safest anatomic route to that location?

Despite serious concerns regarding the potential of accelerated growth or metastatic dissemination of a malignant tumor after biopsy, there is no well-founded, objective evidence that biopsy promotes either adverse event. The real risk of open and needle biopsies is that they may spread tumor cells locally and facilitate local tumor recurrence (Figure 2.3).¹⁰⁻¹³ The actual risk of local recurrence after biopsy is not well documented, but it is reasonable to assume that it is higher in open biopsy than in needle biopsy, and that it is related to the width of the biopsy tract and adequacy of homeostasis. In planning the definitive surgery it must be assumed that the biopsy tract is contaminated with tumor cells and, therefore, it should be resected with the same safety margins as the primary tumor (i.e., wide margins – Figure 2.4).

For these reasons the surgeon performing the biopsy must be familiar with the technique of the potential definitive procedure, whether it is limb-sparing surgery or amputation. The biopsy incision or the needle puncture hole, and the tract to the tumor, must be made with the planned surgical incision site so that they will be included within the surgical specimen. Preferably, the surgeon performing the biopsy will be the same person who will perform the definitive procedure.

General guidelines regarding positioning of the biopsy tract are applicable to biopsies of bone and soft-

tissue lesion and are independent of the technique (open versus needle biopsy) and anatomic location. These guidelines can be summarized as follows: (1) Decide, before biopsy, what part of the lesion is most representative of the underlying disease and will need to have a biopsy. As a rule the extraosseous component of a malignant bone tumor is as representative of the tumor as is the bony component, and should have biopsy, if present. Violating the cortex of a bone that harbors a malignant tumor, predisposes the patient to a pathologic fracture, and is recommended only if there is no extraosseous extension of the tumor. (2) Position the point of entry along the planned incision of the definitive surgery. (3) The biopsy tract must be the shortest way to the lesion; however, it must not violate more than one compartment and must be as remote as possible from the main neurovascular bundle of the extremity. Figures 2.5–2.7 show the recommended surgical approach to the four most common locations of primary bone sarcomas (proximal femur, distal femur, proximal tibia, and proximal humerus).

Biopsy Technique

A closed biopsy does not involve an incision. The specimen is obtained after skin puncture by a needle or trephine. An open biopsy, in contrast, requires an incision. It can either be incisional, in which case only a representative specimen is removed from the lesion, or excisional, in which the lesion is excised en-bloc. Any surgical procedure, even the most minor, is accompanied by a risk of complications that may include iatrogenic injury to blood vessels or nerves, complicated wound healing, wound infection, and tumor cell contamination along the biopsy tract and subsequent local recurrence.

Open incisional biopsy is a reliable diagnostic method because it allows the pathologist to evaluate cellular morphologic features and tissue architecture from different sites of the lesion. Furthermore, it provides material for performing ancillary studies such as immunohistochemistry, cytogenetics, molecular genetics, flow cytometry, and electron microscopy. These studies may help in the diagnosis and subclassification of bone and soft-tissue tumors, and therefore guide the definitive treatment.

Needle biopsy of mesenchymal tumors initially was criticized because the quantity of biopsy material was often insufficient for routine histopathologic evaluation and ancillary studies that require tissue. Fine-needle aspiration (FNA) using a 22-gauge needle, has been shown to be a reliable technique for the diagnosis of soft-tissue tumors that also provides sufficient material for additional studies.¹⁴⁻²⁰ Diagnostic accuracy of FNA is highest when the cell type of the tumor is homogeneous,

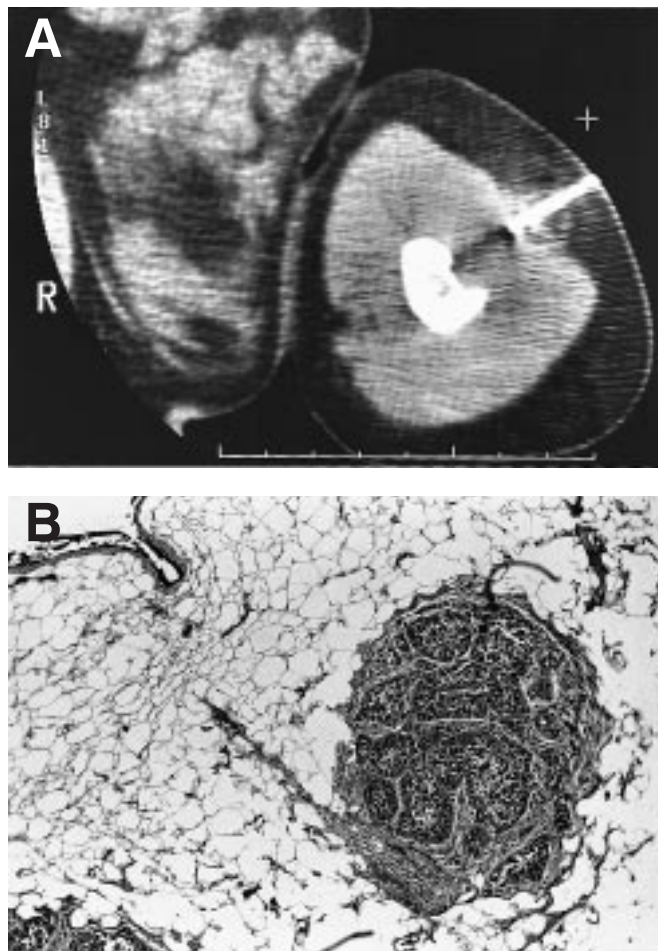


Figure 2.3 (A) Computed tomography guided core needle biopsy of a lytic lesion of the distal humerus, suspected of being a metastatic malignant melanoma. (B) That patient underwent resection-curettage and cryosurgery, followed by radiation therapy. The biopsy tract was resected en-bloc and its pathological evaluation revealed a tumor deposit.

as in the case of multiple myeloma or metastatic carcinomas. Tissue architecture and matrix formation have a major significance in the histologic evaluation and diagnosis of bone tumors. An important limitation of FNA stems from its inability to sample tissue matrix adequately and to show tumor structure.¹⁶ Because of these considerations, with the exception of few specialized centers,^{14,21,22} FNA is not commonly used to diagnose primary bone tumors.²³

Core needle biopsy (CNB), using a 14-gauge needle that provides a core of tissue with a maximum length of 20 mm, was shown to be more than 90% accurate in differentiating malignant from benign lesions.²⁴ In most patients with suspected bone or soft-tissue sarcomas it is the biopsy performed before initiation of treatment. Core needle biopsy is commonly practiced as the first

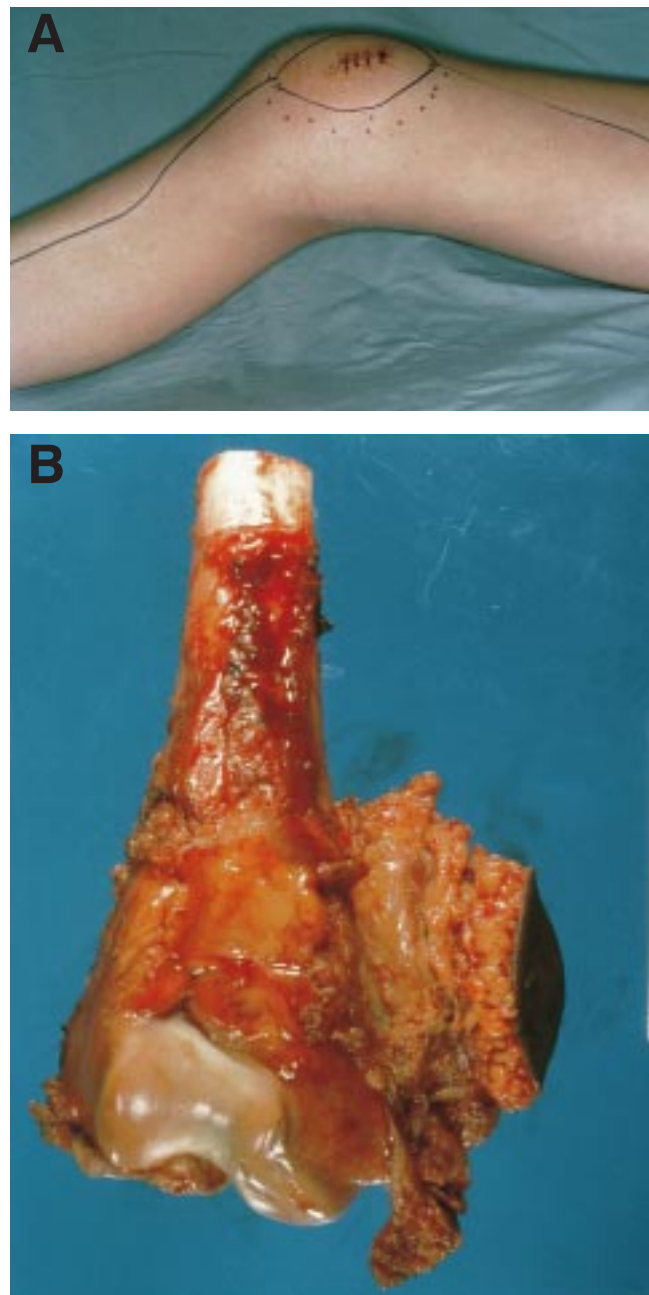


Figure 2.4 (A) Biopsy site over an osteosarcoma of the distal femur. The definitive surgical incision is planned to include the biopsy skin incision and the biopsy tract. (B) The tumor is resected en-bloc with the biopsy tract and the biopsy skin incision.

biopsy modality.²⁴ Open biopsy is performed when the pathologic diagnosis either is inconclusive or does not correlate with the clinical presentation and radiologic findings. Bone biopsies, using a CNB, should be performed under CT or fluoroscopy guidance, and multiple cores should be obtained. Biopsy of a deep-

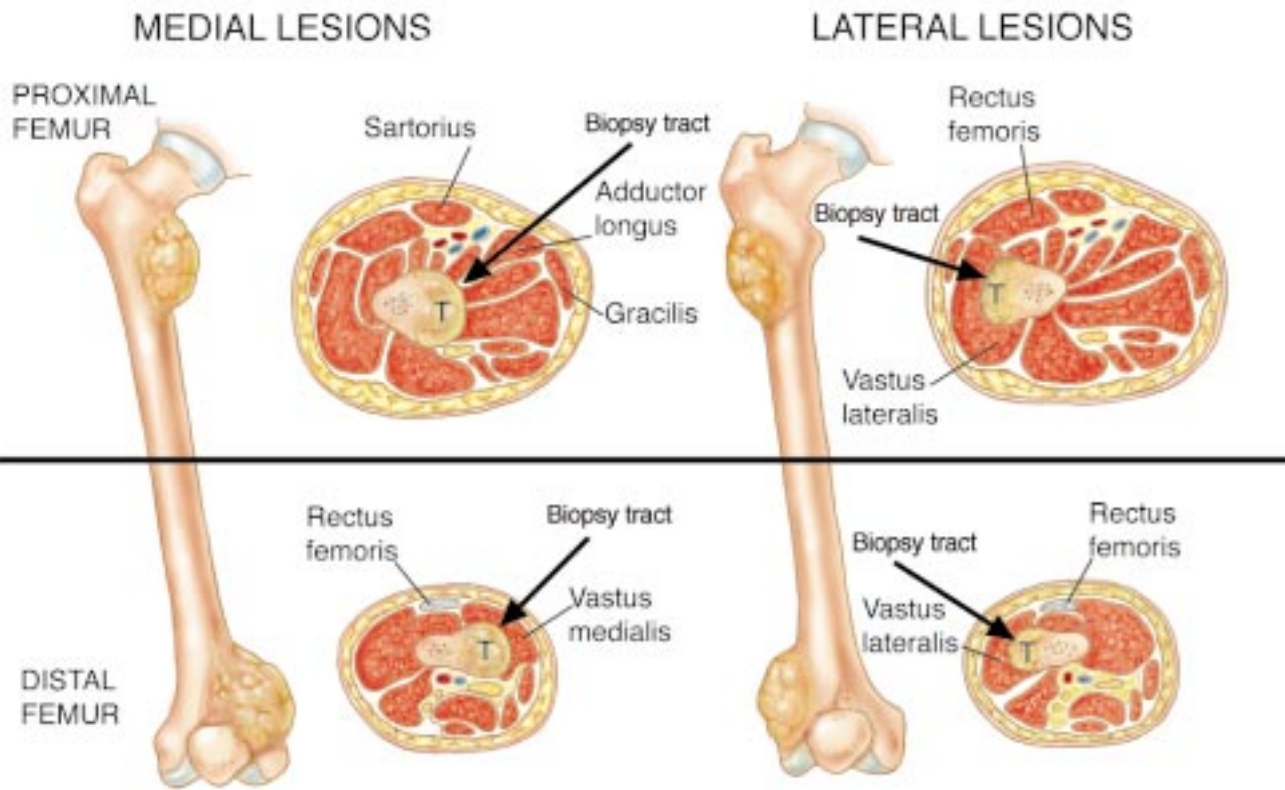


Figure 2.5 Biopsy tract, proximal and distal femur. A distinction is made between lateral and medial lesions. Because the majority of primary bone sarcomas have an extraosseous extension, the muscle underlying the tumor has to be resected with the specimen. This principle applies to all anatomic locations.

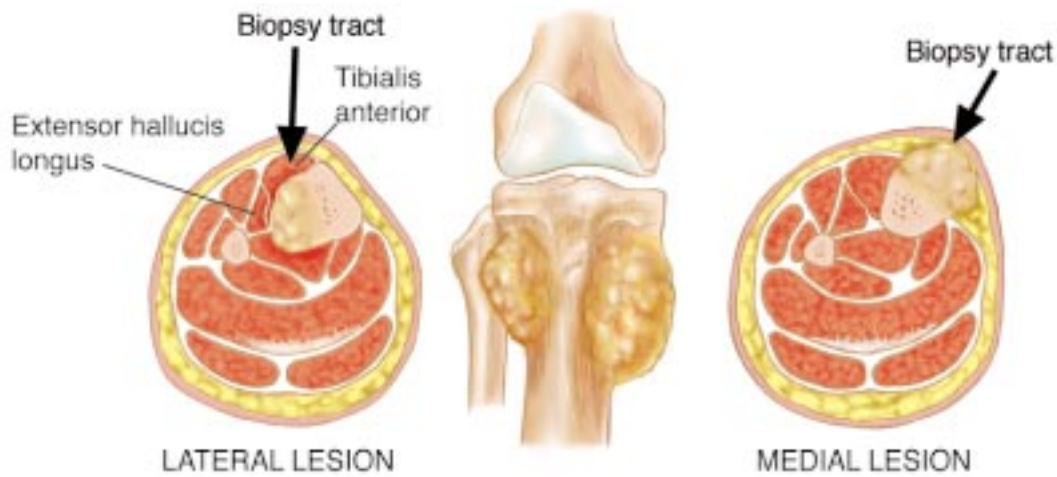


Figure 2.6 Biopsy tract, proximal tibia.

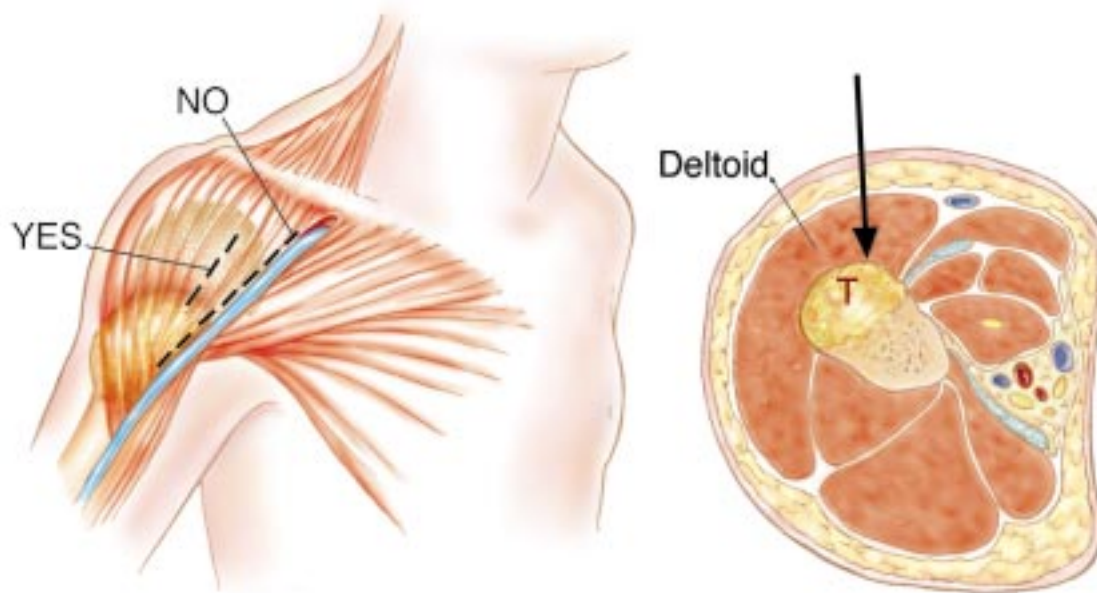


Figure 2.7 Biopsy tract, proximal humerus. The deltoid muscle has to be resected with most primary bone sarcomas of the proximal humerus. A transdeltoid approach through the anterior third of the muscle is used. The traditional deltopectoral approach will necessitate wider resection of the pectoralis major muscle, compromise its use for soft-tissue reconstruction, and may contaminate the main neurovascular bundle of the upper extremity.

seated or pelvic soft-tissue tumors is performed under CT guidance. If a soft-tissue tumor is palpable and is remote from the neurovascular bundle, a biopsy can be performed in a clinic setting.

After adequate planning of the biopsy tract, biopsy should be executed according to the following guidelines: (1) Use the smallest longitudinal incision that is compatible with obtaining an adequate specimen. Transverse incisions are contraindicated because they require a wider soft-tissue resection at the time of definitive surgery (Figure 2.8). (2) Use a knife or curette to avoid crushing or distorting the specimen's texture. When a purely intraosseous bone lesion is having biopsy, make a cortical window and pay attention to its shape. Clark *et al.*²⁵ evaluated the impact of three types of hole shape (rectangular hole with square corners, rectangular hole with rounded corners, and oblong hole with rounded ends) on the breaking strength of human femora. They found that an oblong hole with rounded ends afforded the greatest residual strength.²⁵ They also found that increasing the width of the hole caused a significant reduction in strength, but increasing the length did not.²⁵ Therefore, when the biopsy must be taken from the bone, a small circular hole should be made so that only minimal stress-risers are created. If a larger window is needed, an oblong window should be made (Figure 2.9). (3) Obtain

enough tissue. Always send a specimen for frozen section or touch-prep to verify the presence of representative tumor material in the specimen. For needle biopsies, cytopathologic evaluation has to confirm the presence of viable tumor cells. If pathologic evaluation is negative or questionable, repeat the biopsy. (4) As a general rule, culture what you biopsy and biopsy what you culture. (5) Use meticulous hemostasis. Any hematoma around a tumor should be considered contaminated. Large hematoma may dissect the soft and subcutaneous tissues and contaminate the entire extremity, making limb-sparing surgery impossible. A tourniquet is rarely indicated for an open biopsy, because bleeding vessels cannot be observed and adequate hemostasis is hard to achieve. If a tourniquet is used, the limb should not be exsanguinated by wrapping with an Esmarch bandage, because this may force tumor cells to the proximal aspect of the extremity and into the bloodstream. To allow hemostasis, the tourniquet must be removed before wound closure. (6) Use drains if necessary. The port of entry has to be in proximity and continuation with the skin incision, not to its sides (Figure 2.10). The drain path is considered contaminated and has to be excised with the surgical specimen. Guidelines regarding the excision of the draining tract therefore are similar to those that apply to the biopsy tract.

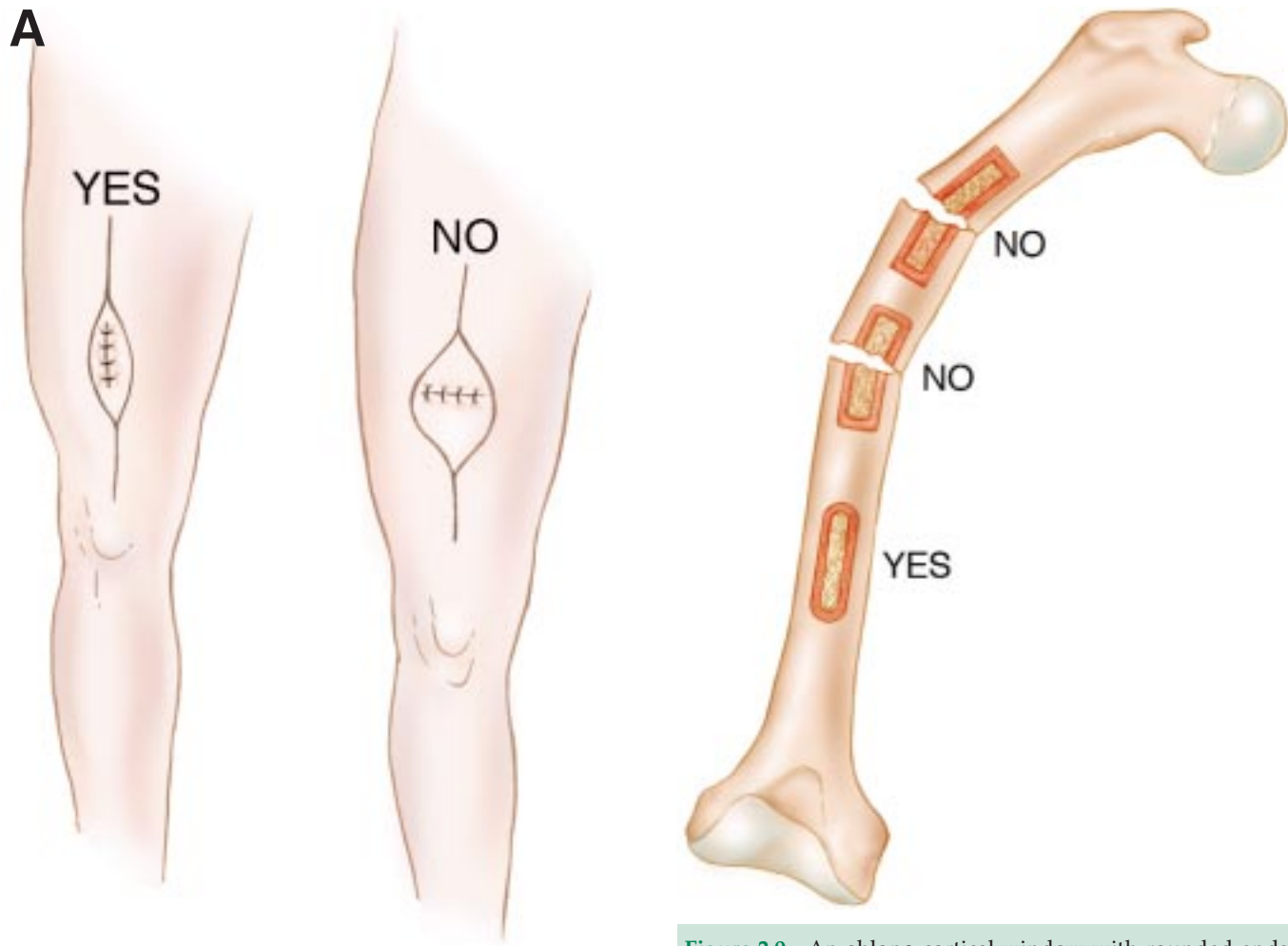


Figure 2.9 An oblong cortical window with rounded ends affords the greatest residual strength and is recommended for biopsy of purely intraosseous lesions.

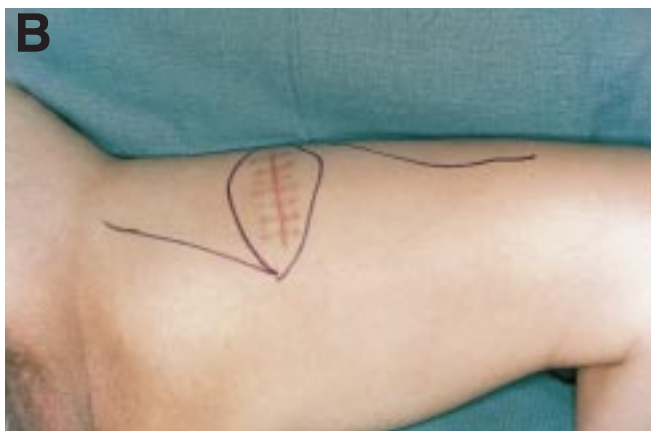


Figure 2.8 (A) The smallest longitudinal incision that allows an adequate specimen to be obtained should be used. A transverse biopsy incision requires a wider resection of soft tissues at the time of the definitive surgery. (B) Horizontal biopsy incision over a high-grade soft-tissue sarcoma of the thigh. Definitive surgery had to be modified to include the biopsy incision.

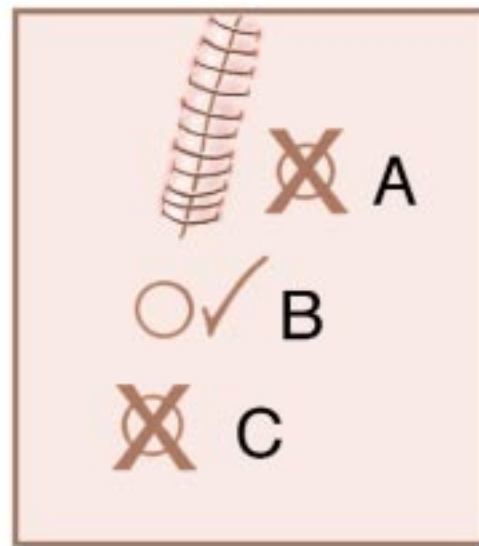


Figure 2.10 A drain has to be positioned in proximity to and along the site for planned incision of the definitive procedure.

SUMMARY

Accurate diagnosis of a musculoskeletal tumor is based on these factors: clinical presentation, results of radiologic studies, and pathologic evaluation. The importance of careful planning and performance of a

biopsy cannot be overemphasized because an error may have a negative impact on survival, impede a proper diagnosis, and compromise the ability to perform limb-sparing surgery. Core needle biopsies, performed under CT guidance when indicated, are recommended.

References

- Jaffe HL. Introduction: Problems of classification and diagnosis. In: Jaffe HL, editor. *Tumors and Tumorlike Conditions of the Bones and Joints*. Philadelphia: Lea & Febiger; 1958:9–17.
- Chang AE, Sondak VK. Clinical evaluation and treatment of soft tissue tumors. In: Enzinger FM, Weiss SW, editors. *Soft Tissue Tumors*. St Louis: CV Mosby; 1995:17–38.
- Simon MA. Current concepts review: Biopsy of musculoskeletal tumors. *J Bone Joint Surg*. 1982;64A:1253–7.
- Mankin HJ, Lange TA, Spanier SS. The hazards of biopsy in patients with malignant primary bone and soft tissue tumors. *J Bone Joint Surg*. 1982;64A:1121–7.
- Mankin HJ, Mankin CJ, Simon MA. The hazards of biopsy, revisited. *J Bone Joint Surg* 1996;78A:656–63.
- Enneking WF. General principles of musculoskeletal tumor surgery. In: Enneking WF, editor. *Musculoskeletal tumor surgery, vol. 2*. New York: Churchill-Livingstone; 1983:3–27.
- Dorfman HD, Czerniak B. General considerations. In: Dorfman HD, Czerniak B, editors. *Bone Tumors*. St Louis: CV Mosby; 1988:1–33.
- Frassica FJ, Frassica DA, Sim FH. Carcinoma metastatic to bone: pathogenesis and pathophysiology. In: Simon MA, Springfield D, editors. *Surgery for Bone and Soft-Tissue Tumors*. Philadelphia: Lippincott-Raven; 1998:615–20.
- McKenna RJ, Schwinn CP, Soong KY, Higinbotham NL. Sarcomata of osteogenic series (osteosarcoma, fibrosarcoma, chondrosarcoma, parosteal osteosarcoma and sarcomata) arising in abnormal bone: an analysis of 552 cases. *J Bone Joint Surg*. 1966;48A:1–26.
- Davies NM, Livesly PJ, Cannon SR. Recurrence of an osteosarcoma in a needle biopsy tract. *J Bone Joint Surg*. 1993;75B:977–8.
- Ferrucci Jr JT. Malignant seeding of needle tract after thin needle aspiration biopsy: a previously unrecorded complication. *Radiology*. 1979;130:345–6.
- Noria S, Davis A, Kandel R *et al*. Residual disease following unplanned excision of soft-tissue sarcoma of an extremity. *J Bone Joint Surg*. 1996;78A:650–5.
- Schwartz HS, Spengler DM. Needle tract recurrences after closed biopsy for sarcomas: three cases and review of the literature. *Ann Surg Oncol*. 1997;4:228–36.
- Ayala AG, Ro JY, Fanning CV, Flores JP, Yasco AW. Core needle biopsy and fine needle aspiration in the diagnosis of bone and soft-tissue lesions. *Hematol Oncol Clin N Am*. 1995;9:633–51.
- Berardo MD, Powers CN, Wakely Jr PE, Almeida MO, Frable WJ. Fine-needle aspiration cytopathology of malignant fibrous histiocytoma. *Cancer*. 1997;81:228–37.
- Bommer KK, Ramzy I, Mody D. Fine needle aspiration biopsy in the diagnosis and management of bone lesions: a study of 450 cases. *Cancer*. 1997;81:148–56.
- Will'en H. Fine needle aspiration in the diagnosis of bone tumors. *Acta Orthop Scand*. 1997;273(Suppl.):47–53.
- Will'en H, Akerman M, Carl'en B. Fine needle aspiration (FNA) in the diagnosis of soft-tissue tumours: a review of 22 years experience. *Cytopathology*. 1995;6:236–47.
- Akerman M, Killander D, Rydholm A, Rooser B. Aspiration of musculoskeletal tumors for cytodiagnosis and DNA analysis. *Acta Orthop Scand*. 1987;58:523–8.
- Akerman M, Rydholm A, Persson BM. Aspiration cytology of soft tissue tumors. The 10-year experience at an orthopedic oncology center. *Acta Orthop Scand*. 1985;56:407–12.
- Akerman M. The cytology of soft tissue tumors. *Acta Orthop Scand*. 1997;273(Suppl.):54–9.
- White VA, Fanning CV, Ayala AG *et al*. Osteosarcoma and the role of fine-needle biopsy: a study of 51 cases. *Cancer*. 1988;62:1238–46.
- Costa MJ, Campman SC, Davis RL, Howell LP. Fine-needle aspiration cytology of sarcoma: retrospective review of diagnostic utility and specificity. *Diagn Cytopathol*. 1996;15:23–32.
- Heslin MJ, Lewis JJ, Woodruff JM, Brennan MF. Core needle biopsy for diagnosis of extremity soft tissue sarcoma. *Ann Surg Oncol*. 1997;4:425–31.
- Clark CR, Morgan C, Sontegard DA *et al*. The effect of biopsy hole shape and size on bone strength. *J Bone Joint Surg*. 1977;59A:213–17.

