

# 21

## Hip Disarticulation

Paul Sugarbaker and Martin Malawer

### OVERVIEW

Hip disarticulation is an amputation through the hip joint capsule, removing the entire lower extremity, with closure of the remaining musculature over the exposed acetabulum. Hip joint disarticulation was the classic procedure for the treatment of distal femoral osteosarcomas. The oncological thinking during the 1970s was that the existence of skip metastases throughout the intraosseous extent of the femur was extremely significant and a cause of local recurrence and metastatic disease. Therefore, the philosophy of the day (1960s–1970s) was to remove the entire bone when involved by an osteosarcoma. Tumors of the distal and proximal femur were treated by total femur resection/removal; that is, a hip disarticulation. Similarly, an osteosarcoma of the proximal humerus was treated with a forequarter amputation to remove the entire humerus.

Fortunately, today, hip disarticulations are rarely performed for tumors of the distal femur. Ninety to 95% of distal femoral sarcomas can be treated with limb-sparing procedures. Those that cannot are treated with a mid-thigh to a high above-knee amputation. Soft-tissue sarcomas, which involve the distal or mid-portion of the thigh, can often be treated by a limb-sparing resection. A hip disarticulation for a soft-tissue sarcoma is rarely performed, although, similar to bone sarcomas, it was the standard operation for mid-thigh, high-grade soft-tissue sarcomas during the 1960s and 1970s.

It must be noted that tumors that involved the proximal femur are best treated by a modified hemipelvectomy. A hip disarticulation would leave extremely close or positive margins along the remaining hip capsule and/or the musculature around the hip joint that attaches to the ileum anteriorly and posteriorly.

Today, most diaphyseal femoral tumors are treated with an intercalary resection or total femoral replacement. An intercalary resection can be reconstructed with a composite, consisting of an allograft spanned with an intramedullary rod, or an allograft spanned by an autogenous fibula from the same side. MRI is extremely useful in determining the intraosseous extent of diaphyseal tumors.

Today hip disarticulation is considered a poor oncological operative procedure. Its main use is for failed vascular procedures following multiple lower-level amputations, or for massive trauma with crush injuries to the lower extremity.

The surgical technique is based upon a wide fish-mouth incision placed over the central aspect of the femoral triangle. This incision passes medial and lateral at the level of the greater trochanter and then transverses around the posterior thigh. The femoral vessels are initially exposed, ligated, and doubly transected. The medial and lateral thigh musculature is transected above the level of the greater trochanter. The adductor attachments of the muscles are removed from their origin along the ischium and pubic rami.

The hip is then flexed and the posterior incision is made. The posterior musculature is released from the ischium. The sciatic nerve is cut high above the profundus to allow it to retract. The inferior and superior gluteal vessels are ligated prior to removal of the extremity. We routinely utilize epineural marcaine catheters placed into the sciatic and femoral nerves at the time of surgery for postoperative pain control. It has been our experience that this dramatically reduces the amount of postoperative narcotics by 90%. This is especially true in younger patients who have extreme pain following amputations at any level. This catheter is continued for a minimum of 3–5 days postoperatively and, if necessary, the patient can go home with the catheter in place with a portable infusion pump (these pumps are made by several manufacturers).

Function following a hip disarticulation with a modern prosthesis is acceptable. Patients are ambulatory at approximately 6 months with the use of one cane. Intensive physical therapy and psychological rehabilitation is required prior to and following surgery, for optimal results. We routinely transfer patients to a rehabilitation hospital immediately after surgery for a 2-week period of intensive therapy. Patients are instructed in the use of crutches and a walker, and are taught how to wrap their stump. This, in conjunction with a support group for amputees and sarcoma patients, has been found to be beneficial. Early and intensive psychological and physical rehabilitation results in most patients being completely independent and ambulatory at the end of 1 year. Surprisingly, all patients who require amputation at the hip-joint level for vascular disease can also become functional with crutches and/or a wheelchair. Amputations performed for vascular disease are often on a semi-emergency basis. The typical patient is in sepsis from multiple failed above-knee procedures or clotted femoral–popliteal grafts.

## INTRODUCTION

Hip disarticulation is the removal of the entire lower extremity through the hip joint. Hip disarticulation has traditionally been performed for osteosarcomas of the distal femur prior to induction chemotherapy in the 1970s. The oncological dogma at that time required that the entire bone be removed due to the existence of intraosseous skip metastases. Therefore hip disarticulation was the standard operation for distal femoral sarcomas and, similarly, forequarter amputations were the standard operation for proximal humeral sarcomas. Other indications for hip disarticulation today are large diaphyseal tumors that do not extend above the lesser trochanteric area. If the head and neck are involved, a modified hemipelvectomy is required. Otherwise, a high above-knee amputation can be performed. Soft-tissue sarcomas that involve the anterior and posterior thigh in the mid-portion can often undergo a limb-sparing surgical procedure. Approximately 5% of these tumors involve the underlying femur and superficial femoral artery. In such cases an amputation is often required.

Today, in conjunction with the use of adjuvant chemotherapy (induction chemotherapy and/or preoperative radiation therapy for soft-tissue sarcomas), limb-sparing procedures for distal femoral and diaphyseal tumors are extremely successful. Less than 5–10% of patients require an amputation. If an amputation is required for a distal femoral or diaphyseal lesion, a high above-knee amputation can be performed safely. Most soft-tissue sarcomas will respond to induction chemotherapy and/or preoperative radiation therapy with very few requiring an amputation for local control.

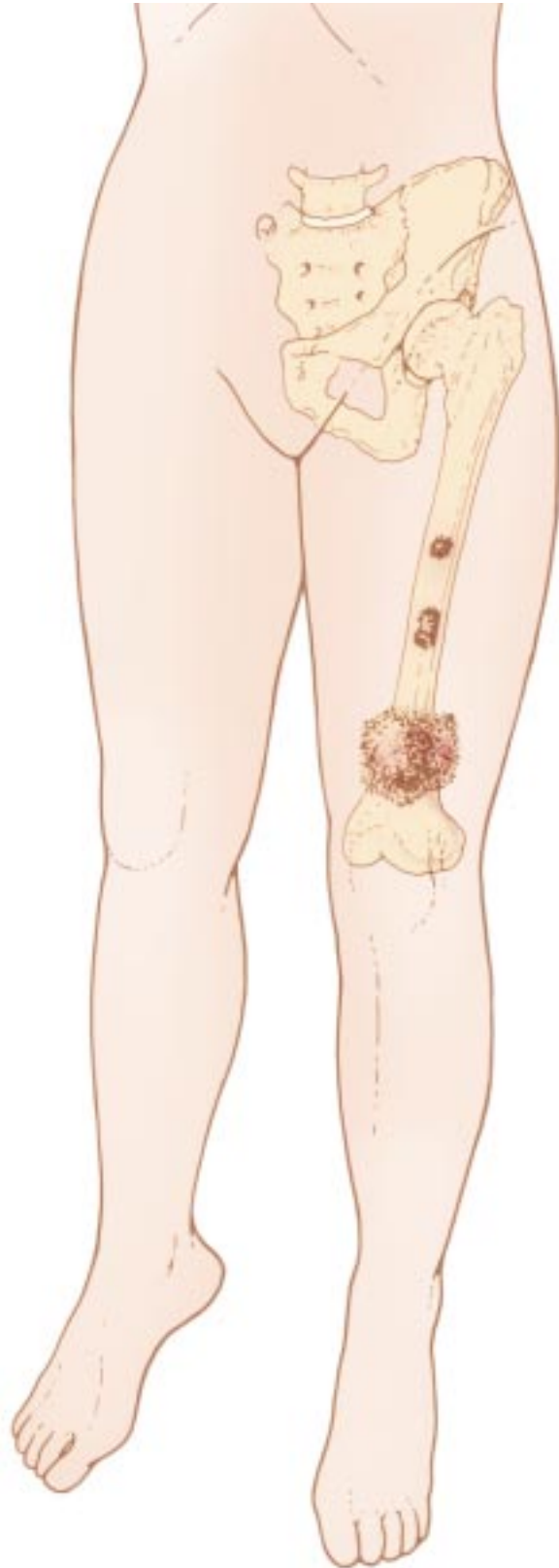This chapter describes the technique developed by the senior author for performing a hip disarticulation in an orderly manner with minimal blood loss. It is applicable to all ages (Figure 21.1).

## INDICATIONS/CONTRAINDICATIONS

High-grade sarcomas of the distal femur and diaphysis of the femur can most often be resected with a limb-sparing procedure. Amputation is rarely required. The criteria for limb-sparing resection are given in Chapter 30. This section will summarize the basic contraindications to resection of bony and soft-tissue sarcomas of this anatomic location.

### Diaphyseal Bone Tumors with Large Intramedullary Extension

Tumors of the diaphysis may extend extremely long distances proximally and distally. If the intraosseous



**Figure 21.1** Hip disarticulation is indicated for malignant bony and soft-tissue tumors below the lesser trochanter of the femur.

spread is above the level of the lesser trochanter, a hip disarticulation may be required if the required criteria for limb-sparing surgery are not met. Those tumors that involve the head and neck of the femur require modified hemipelvectomy.

### Pathological Fractures of Bone Sarcomas

Fractures that do not respond to induction chemotherapy and cast immobilization with progressive tumor necrosis and fracture healing may require an amputation for local control.

### Unresectable Local Recurrences

Local recurrence following limb-sparing procedures and/or radiation therapy around the thigh or distal femur may require hip disarticulation.

### Unresectable Soft-tissue Sarcomas

Tumors of the thigh which are extracompartmental involving two or three compartments of the thigh with encasement of the sciatic nerve and/or femoral vessels are deemed unresectable and are best treated by amputation. If the tumor is below the mid-third of the thigh a hip disarticulation is adequate. If the tumor is located more proximally, a modified hemipelvectomy is required so as to obtain negative margins.

Extension of the tumor around the hip, ischiorectal space, and sciatic notch must be evaluated in deciding between a hip disarticulation and a hemipelvectomy. Tumors of the proximal thigh most often require a modified hemipelvectomy. Those of the mid-portion of the thigh may be treated by hip disarticulation. It is important to note that there is minimal functional difference between the two procedures. Therefore, the safest procedure is a modified hemipelvectomy. This is an extra-articular amputation on the opposite side of the pelvis with preservation of the gluteus maximus and the ileum. All potentially contaminated structures are removed with this procedure. A hip disarticulation is in general a poor oncological procedure because, despite the imaging studies, tissues that are at risk for local recurrence still persist; that is, the muscle attachments around the hip, the hip joint capsule, and the acetabulum.

## STAGING AND IMAGING STUDIES

### CT and MRI

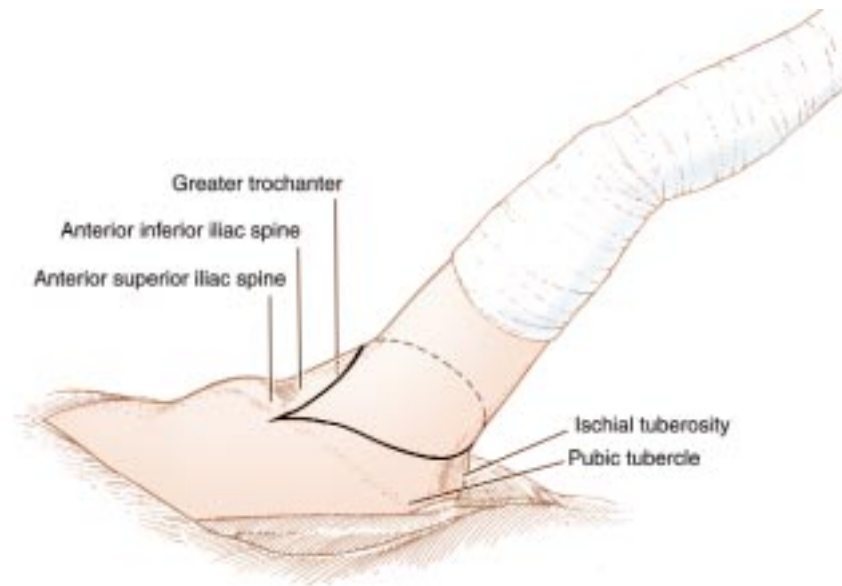
CT and MRI are extremely useful in determining tumor extent, especially the proximal extent. The ischiorectal fossa, hip joint, and the groin must be carefully evaluated for additional tumor extension. The MRI is especially useful to evaluate the intraosseous spread of tumor within the marrow. If the tumor is below the level of the lesser trochanter, a high above-knee amputation or hip disarticulation can probably be performed. If the head or neck of the femur is involved by tumor there is a significant risk of joint involvement; therefore a modified hemipelvectomy is required. There have been reports of extra-articular hip resection for tumors of the proximal femur in lieu of modified hemipelvectomy, but this is essentially an extension of a hip disarticulation that is an extra-articular resection of the acetabulum en-bloc with the proximal femur.

### Bone Scan

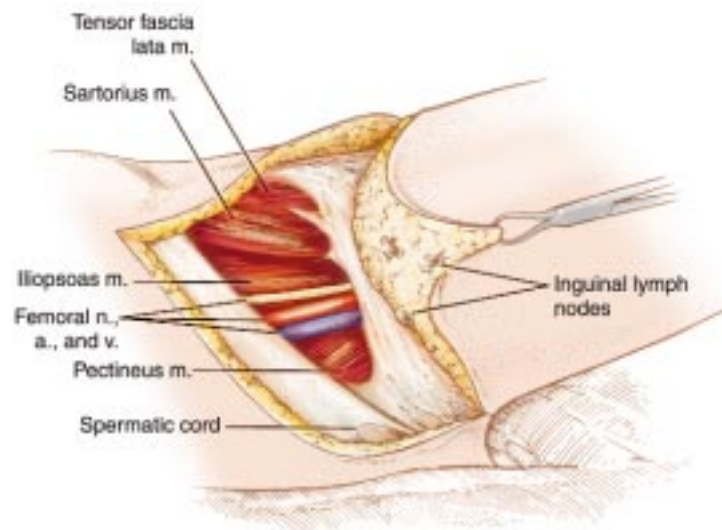
Bone scan is useful in determining bony involvement of the femur as well as the involvement of the adjacent pelvis and acetabulum. Acetabular involvement (transarticular metastases) contraindicates a hip disarticulation and is an indication for a modified hemipelvectomy.

## SURGICAL GUIDELINES

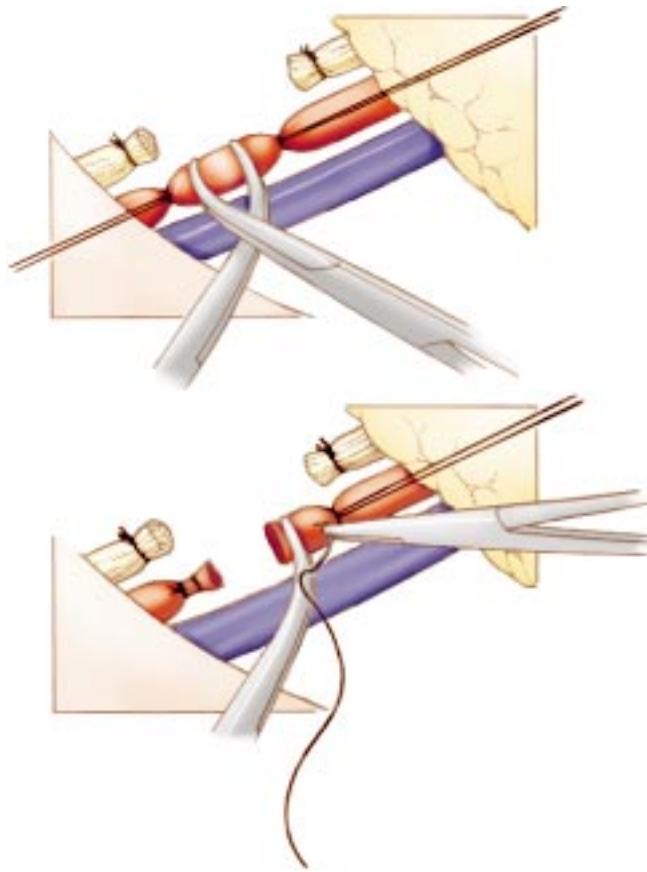
1. Equal anterior and posterior flaps are utilized. Modification of these flaps may be required depending on the location of the tumor.
2. The femoral triangle is exposed and the common femoral vessels are doubly ligated and transected.
3. The abductors are released from the greater trochanter and the adductors are transected from their origin on the pelvis.
4. The sciatic nerve must be transected high near the sciatic notch.
5. The closure must consist of tenodesing the remaining muscles over the acetabulum.
6. A sciatic epineural catheter is used for postoperative pain relief.



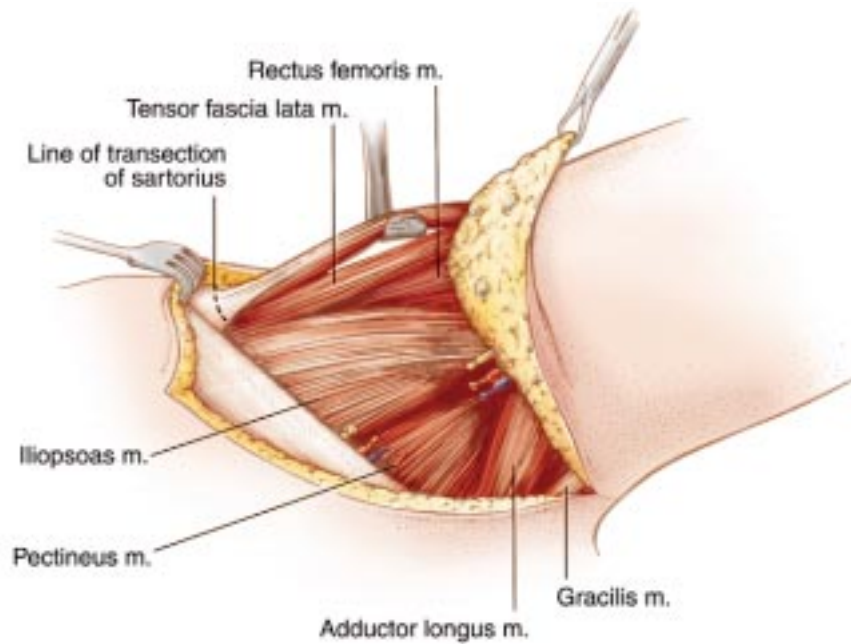
**Figure 21.2** Incision. Bony landmarks to be identified include the pubic tubercle, anterior superior iliac spine, anterior inferior iliac spine, ischial tuberosity, and greater trochanter. The anterior portion of the incision commences one fingerbreadth medial to the anterior superior iliac spine. It descends to the pubic tubercle and then over the pubic bone to two fingerbreadths distal to the ischial tuberosity and gluteal crease. If the buttock flap is extremely thick, the anterior portion of the incision should be moved laterally. The posterior portion of the incision extends two fingerbreadths anterior to the greater trochanter and then around the back of the leg distal to the gluteal crease. The distance the incision is beyond the gluteal crease is directly proportional to the anterior-posterior diameter of the patient's pelvis.



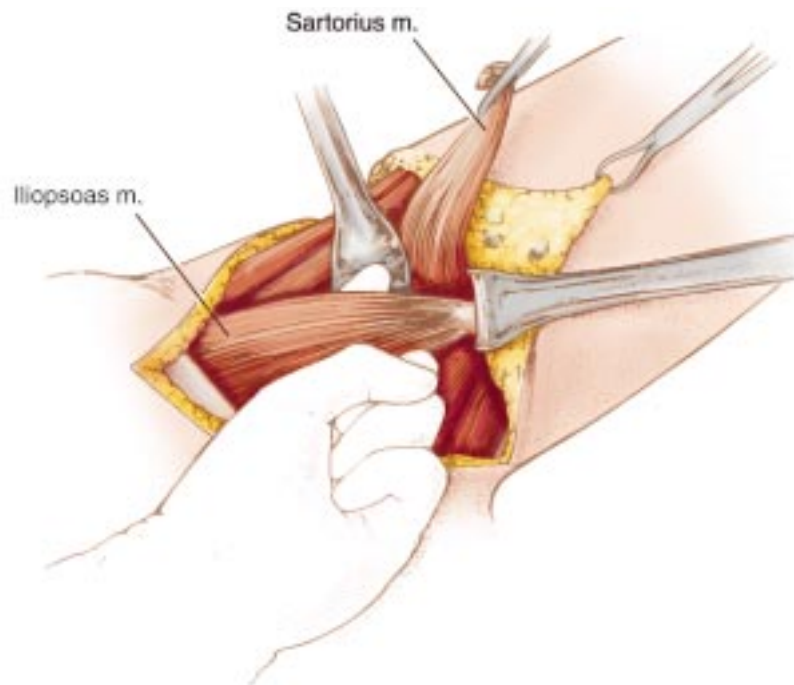
**Figure 21.3** Exposure of femoral triangle. The skin is incised, and the dissection is extended through subcutaneous fat and Scarpa's fascia until the external oblique aponeurosis is seen. Multiple venous bleeding points from branches of the saphenous vein are clamped, divided, and ligated. A moderate-sized artery, the superficial epigastric, and multiple branches of the external pudendal vessels must be secured. The superficial inguinal lymph nodes should be moved laterally with the specimen, and the round ligament in the woman, or the spermatic cord in the man, is exposed but not included in the specimen. An Adair clamp is placed securely on the apex of the skin specimen for traction. By making an incision just below the inguinal ligament into the fossa ovalis, the femoral vein, artery, and nerve are widely exposed below the inguinal ligament.



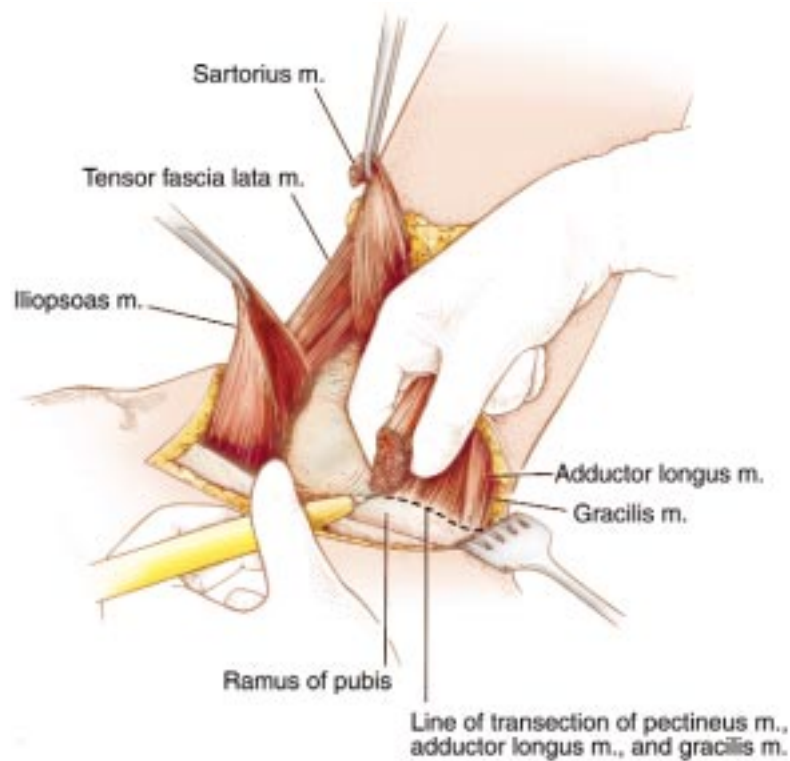
**Figure 21.4** Division of femoral vessels and nerve. Individual silk ties are placed around the femoral vessels; first the artery and then the vein are tied in continuity. Right-angle clamps are placed between the ties, and the vessels are severed. The proximal ends of the vessels are further secured by a silk suture ligature placed proximal to the right-angle clamps. The femoral nerve is placed on gentle traction and ligated at its point of exit from beneath the inguinal ligament. When the femoral nerve is severed, it retracts beneath the external oblique aponeurosis, so that if a neuroma forms it will not be in a weight-bearing portion of the stump.



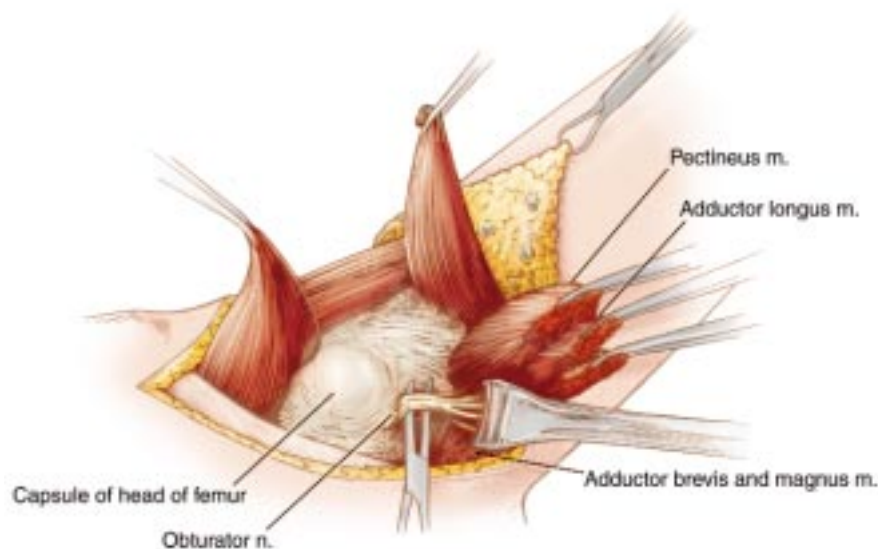
**Figure 21.5** Division of sartorius muscle and femoral sheath. The sartorius muscle is located as it arises from the anterior superior iliac spine. It is dissected free from the surrounding fascia and then transected from its origin on the spine by electrocautery. The femoral sheath and fibroareolar tissue posterior to the femoral vessels are also incised by electrocautery. This dissection exposes the hip joint capsule.



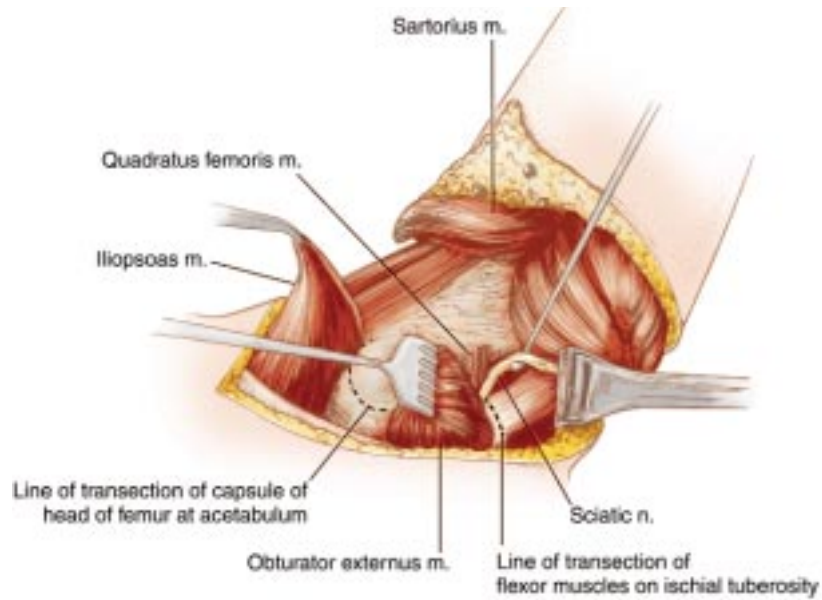
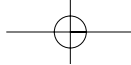
**Figure 21.6** Division of iliopsoas muscle at its insertion. The hip is flexed slightly to relax the iliopsoas muscle. It is then possible to pass a finger around the iliopsoas muscle in a mediolateral blunt dissection. If an attempt is made to pass the finger beneath the muscle from lateral to medial, the very intimate attachments between the iliopsoas muscle and the rectus femoris muscle prevent this from being easily done. By sharp and blunt dissection the entire iliopsoas muscle is dissected until its insertion on the lesser trochanter is clearly defined. Several vessels of prominent size pass from the anterior surface of this muscle, and care should be taken to secure these vessels prior to their division. The iliopsoas muscle is severed at the level of its insertion onto the lesser trochanter.



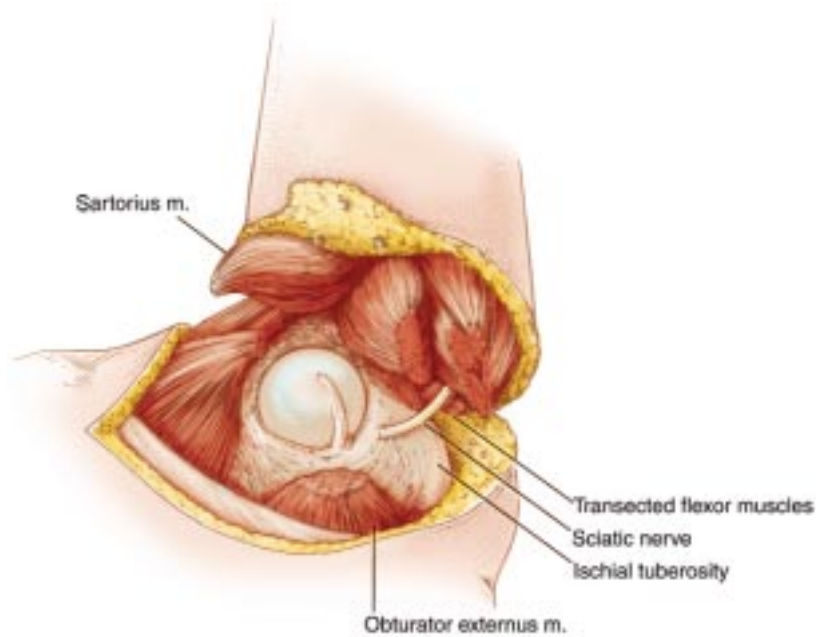
**Figure 21.7** Transection of pectineus muscle at its origin. Now attention is turned to the adductor muscles and their release from the pelvis. It is important to note that this dissection proceeds from lateral to medial around the extremity. To preserve the obturator externus muscle on the pelvis, locate its prominent tendon arising from the lesser trochanter. Locating this tendon identifies the plane between pectineus muscle and obturator externus; a difference in the direction of the muscle fibers of these two muscles is also apparent. A finger is passed beneath the pectineus muscle, and it is released at the level of its origin from the pubis by electrocautery. Beneath the pectineus muscle numerous branches of the obturator artery, vein, and nerve can now be visualized.



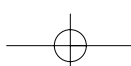
**Figure 21.8** Transection of gracilis, adductor longus, brevis, and magnus muscles from their origin; division of obturator vessels and nerve. The remainder of the abductor muscles are transected at their origin on the symphysis pubis. These include the gracilis, adductor longus, adductor brevis, and adductor magnus muscles. Note that the obturator vessels and nerves usually bifurcate around the adductor brevis muscle. It is important that branches of the obturator artery be identified and secured during the dissection, to prevent accidental rupture and retraction of the proximal ends up into the pelvis.



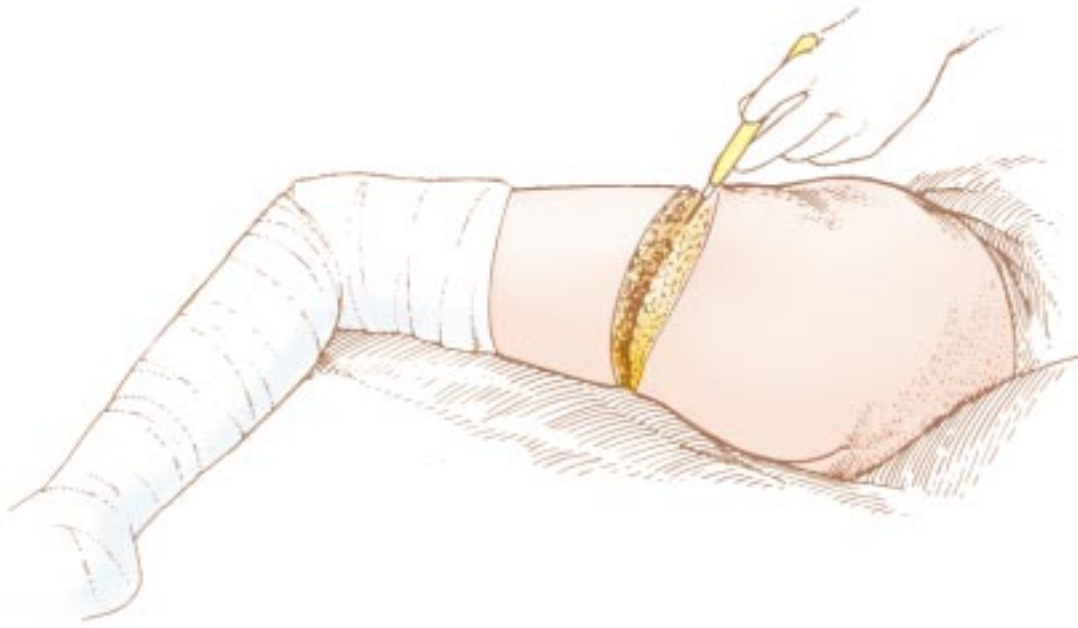
**Figure 21.9** Release of the flexor muscles from the ischial tuberosity. The extremity is hyperabducted to help localize the ischial tuberosity and to retract the cut ends of the abductor muscles. The flexor muscles, sciatic nerve, and quadratus femoris muscle are now identified. The large circumflex femoral vessels are nearby and should be avoided. The semimembranosus, semitendinosus, and long head of the biceps muscle are transected from their origin on the ischial tuberosity while preserving the quadratus femoris muscle and sciatic nerve.



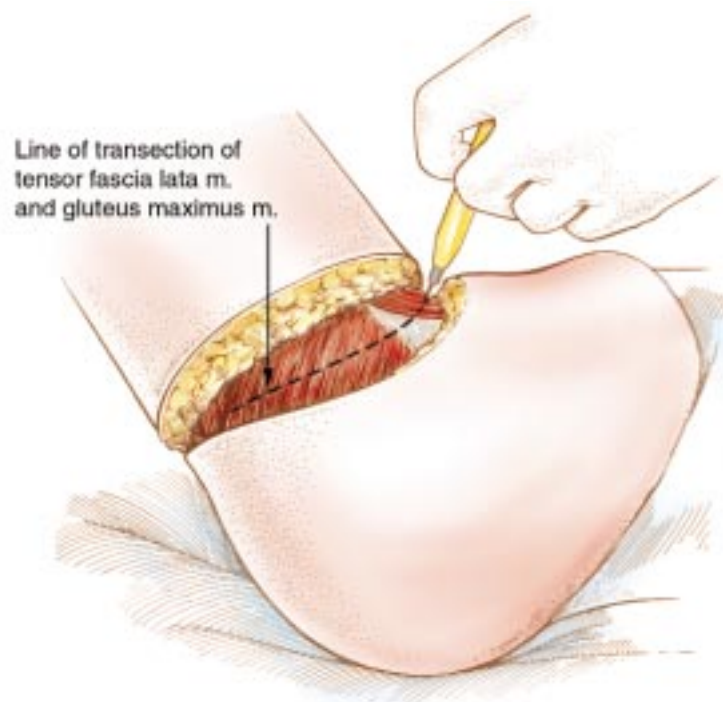
**Figure 21.10** Incision of the anterior portion of the hip joint capsule. At this point all the anterior and posterior muscle groups have been divided. The joint capsule overlying the head of the femur is incised, and the ligamentum teres is transected by electrocautery.



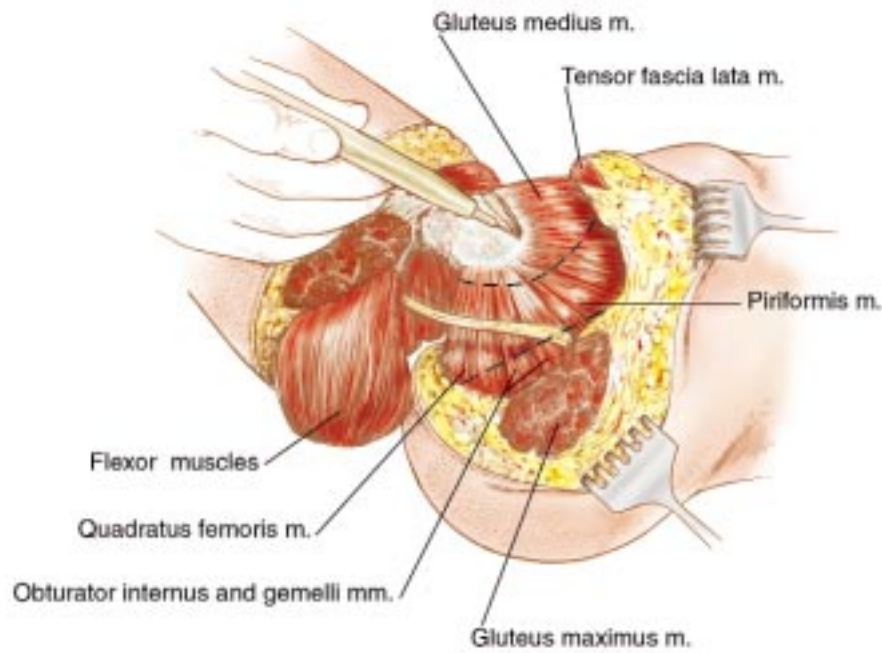




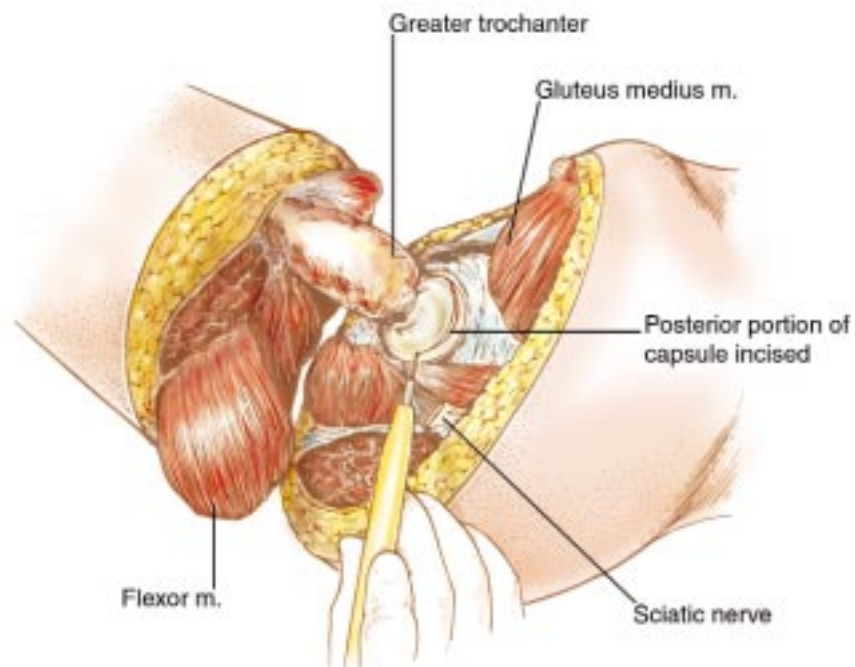
**Figure 21.11** Completion of the skin incision. The surgeon now moves from a position anterior to the patient to a posterior position. The patient's torso is tilted from posterolateral to anterolateral, and the skin incision is completed down through gluteal fascia.



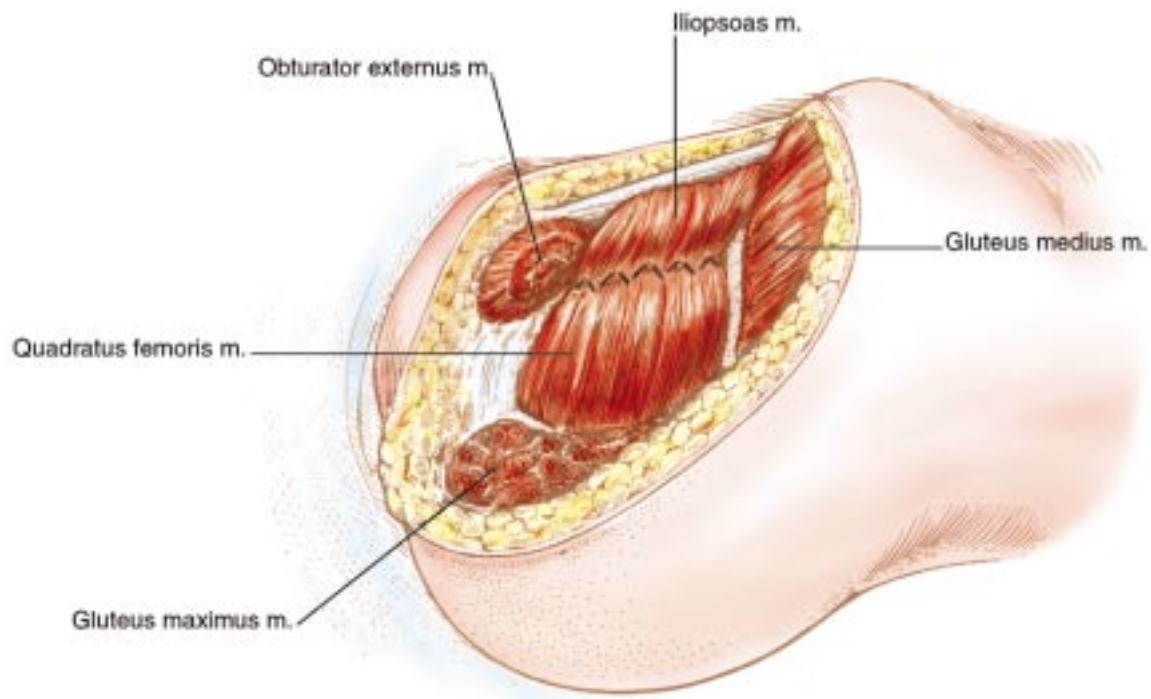
**Figure 21.12** Division of tensor fascia lata, gluteus maximus, and rectus femoris muscles. The tensor fascia late and gluteus maximus muscles are divided in the depths of the skin incision. These are the only muscles not divided at either their origin or insertion in the procedure. Directly beneath these muscles is the rectus femoris muscle, which is transected at its origin on the anterior inferior iliac spine by electrocautery.



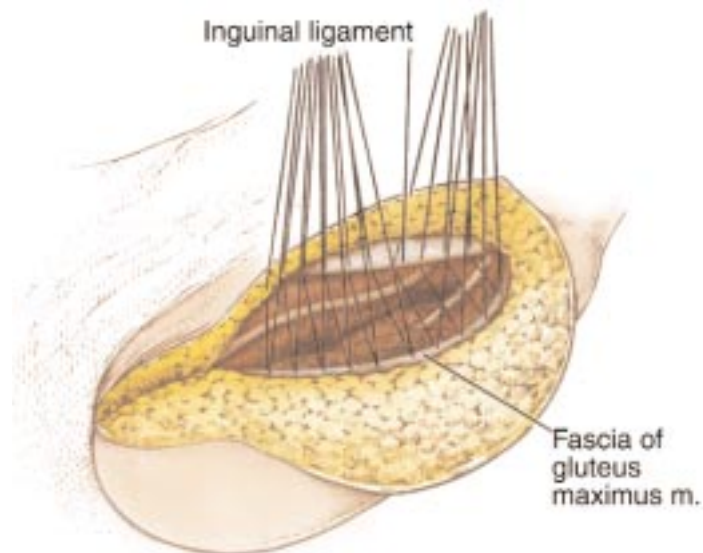
**Figure 21.13** Transection of the muscles inserting into the greater trochanter. After division of the gluteus maximus muscle the common tendon containing the multiple muscles inserting into the greater trochanter is exposed. This tendon receives contributions from the gluteus medius, gluteus minimus, piriformis, superior gemellus, obturator internus, inferior gemellus, and quadratus femoris muscles. These muscles are divided close to their insertions on the greater trochanter by electrocautery.



**Figure 21.14** Release of specimen. Transection of the hip joint capsule is completed by incising the posterior portion of the capsule. The sciatic nerve is dissected free of surrounding muscle, transected, and allowed to retract beneath the piriformis muscle.

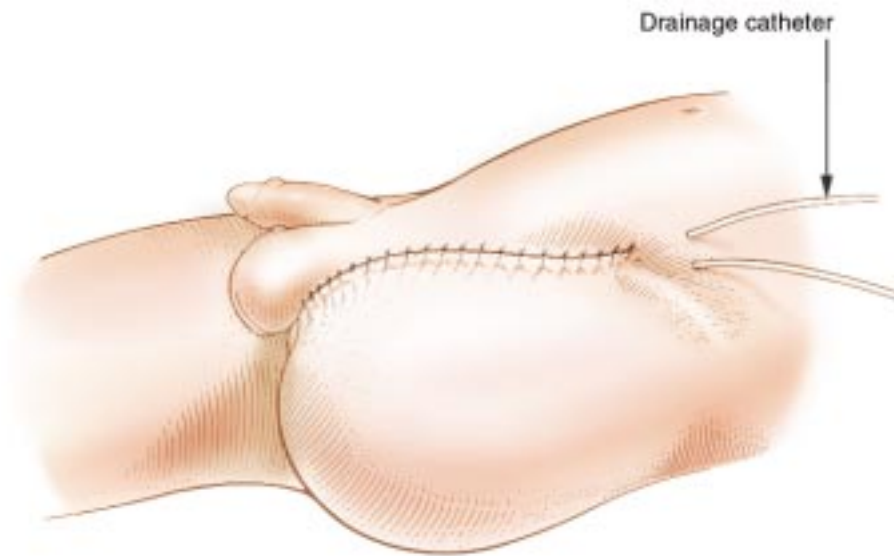
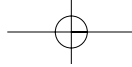


**Figure 21.15** Approximation of obturator externus and gluteus medius over the joint capsule. To help provide soft-tissue coverage of bony prominences, the obturator externus and gluteus medius muscles are sutured together over the acetabulum.



**Figure 21.16** Approximation of gluteal fascia to the inguinal ligament and pubic ramus. The gluteal fascia is elevated and secured to the inguinal ligament and pubic ramus. In doing this it becomes apparent that the posterior myocutaneous flap is much longer than the anterior fascia; therefore, multiple stitches are placed that bisect the fascial edge and uniformly gather the gluteal fascia as it is secured to the inguinal ligament.

Sutures are individually placed and then tied. Prior to closure suction catheters are placed beneath the gluteal fascia.



**Figure 21.17** Skin closure. The skin is closed with interrupted sutures. Again care is taken to make sure that there is equal distribution of the excess tissue of the posterior flap. Not infrequently, additional suction catheters must be used to obliterate space within the subcutaneous tissue when the buttock flap is thick. Patency of the suction catheters must be maintained until drainage is diminished. Ambulation may proceed if the patient's hemodynamic status permits on the first postoperative day.

