

Thermal Ablation of Spinal Osteoid Osteomas Close to Neural Elements: Technical Considerations

Leon D. Rybak¹
 Afshin Gangi²
 Xavier Buy²
 Renata La Rocca Vieira¹
 James Wittig³

OBJECTIVE. The purpose of this study was to evaluate experience with and determine the efficacy and safety of thermal ablation in the management of spinal osteoid osteomas close to neural elements.

MATERIALS AND METHODS. The records of all patients with osteoid osteomas of the spine managed with thermal ablation at two academic centers from 1993 to 2008 were reviewed.

RESULTS. Seventeen patients (13 male patients, four female patients; mean age, 25.9 years) had lesions in the lumbar (seven patients), thoracic (six patients), cervical (three patients), and sacral (one patient) regions of the spine. Two lesions were in the vertebral body, one was within the dens, and the others were in the posterior elements. The mean lesion diameter was 8.8 mm, and the mean distance between the lesion and the closest neural element was 4.3 mm. The lesions were managed with laser (13 lesions) or radiofrequency (four lesions) ablation. Special thermal protection techniques involving the epidural injection of gas or cooled fluid were used. Pain levels were assessed immediately before the procedure and on the day after the procedure. Long-term follow-up findings were available for 11 patients. No complications were encountered, and all patients reported relief of pain. The 11 patients who participated in long-term follow-up reported continued relief of pain.

CONCLUSION. Percutaneous thermal ablation can be used to manage spinal osteoid osteomas close to the neural elements. Special thermal protection techniques may add a margin of safety.

Keywords: laser ablation, osteoid osteomas, radiofrequency ablation, spine, thermal ablation

DOI:10.2214/AJR.10.4192

Received December 28, 2009; accepted after revision March 10, 2010.

¹Department of Radiology, New York University Hospital for Joint Diseases, 301 E 17th St., 6th Fl., New York, NY 10003. Address correspondence to L. D. Rybak (Leon.Rybak@nyumc.edu).

²Department of Radiology, University Hospital of Strasbourg, Strasbourg, France.

³Department of Orthopedic Surgery, Mount Sinai Medical Center, New York, NY.

WEB

This is a Web exclusive article.

AJR 2010; 195:W293–W298

0361–803X/10/1954–W293

© American Roentgen Ray Society



steoid osteoma is a small benign but painful lesion usually found in persons 7–25 years old [1]. Ten percent of the lesions occur in the spine, most within the posterior elements. The lesions typically become evident with pain, particularly at night, that is temporarily relieved by antiinflammatory medication. Lesions in the spine can become evident as painful scoliosis (63–70% of cases), permanent deformity being reported in some cases [2–4]. These spinal lesions can be particularly difficult to diagnose; the average reported delay from presentation to treatment is 18–24 months [5, 6].

Treatment options for osteoid osteomas include surgical excision and percutaneous imaging-guided ablation; most spinal lesions are managed surgically. Complete excision of the nidus often involves removal of extensive amounts of bone, and surgical augmentation may be needed to strengthen the site postoperatively. Incomplete excision has led to reported recurrence rates of 4.5–25%

[7, 8]. Surgical complications specific to the spine include incomplete removal, instability secondary to resection of the posterior elements, and cord or nerve injury [6, 9, 10].

For years, lesions within the spine were considered untreatable with radiofrequency ablation (RFA) because of the inherent risk posed by proximity to the neural elements [9, 11–13]. Both in vivo and ex vivo experiments on the generation of heat in the spinal canal and perineural tissues during ablation have been conducted on animal models, and the influences of proximity to neural structures, the presence of intervening bone, and probe size have been evaluated [14–17]. Although several clinical reports of the successful ablation of spinal osteoid osteomas have been published, the management of such lesions remains controversial [5, 10, 15, 18–22]. Two reports [20, 22] have introduced the concept of perineural injection of insulating substances during ablation of such lesions to provide an additional margin of safety. The purpose of this study was to investigate the

efficacy of thermal ablation in the management of spinal osteoid osteomas close to the neural elements. We also report on our experience with the use of these new neuroprotective techniques.

Materials and Methods

The study was conducted at two academic institutions. The institutional review boards at both institutions granted approval for retrospective review of the clinical data and imaging studies. Waiver of consent was obtained at both institutions.

Patient Selection

At institution 1, from 1993 to 2008, 25 patients with the suspected diagnosis of spinal osteoid osteoma were treated with percutaneous laser ablation. On the basis of measurements made on CT scans obtained at ablation, 13 of these lesions were found to be within 1 cm of an adjacent neural structure and were included in the study. At institution 2, from 2006 to 2008, another four patients with spinal osteoid osteomas were treated with RFA. On the basis of measurements on CT scans obtained at ablation, these lesions also were found to lie within 1 cm of an adjacent neural structure.

In all cases, the diagnosis of osteoid osteoma was based on clinical presentation and imaging findings. The symptoms were considered suggestive of osteoid osteoma if the pain occurred at rest, woke the patient at night, and was temporarily relieved by antiinflammatory medication. All patients underwent preprocedure imaging. On radiographs or CT scans, the presence of a small lytic nidus with surrounding sclerosis was considered suggestive of osteoid osteoma. Marrow or soft-tissue edema on MR images corresponding to a lytic lesion on CT scans, a focus of increased scintigraphic activity on a bone scan, or scoliosis with the lesion localized to the concavity of the curve were seen in some cases.

Procedure

The benefits and risks of thermal ablation and the surgical alternatives were discussed with the patients, parents, and consulting surgeons, and written consent was obtained. All patients were treated by one of two radiologists, both experienced in thermal ablation of osteoid osteomas. The 13 patients at institution 1 were treated with laser ablation, and the four patients at institution 2 with RFA. The mode of thermal ablation was strictly a matter of user familiarity and preference. Because the lesions are painful and precise needle placement is required for accurate, safe ablation, all procedures were performed under general anesthesia.

At both institutions, every patient underwent planning CT through the region of interest with

parameters (tube current–time setting, tube voltage, tube rotation speed) appropriate for standard diagnostic CT and adjusted at the technician's discretion for patient size and age. Reconstructions 1 mm thick were obtained from this data set to localize the nidus. The radiologist performing the procedure measured the nidus in three planes (anteroposterior, transverse, and craniocaudal) using the measurement tools on the CT monitor.

At institution 1, laser ablation was performed under CT guidance (Somatom Plus-S ICT or Volume Zoom Plus 4 scanner, Siemens Healthcare). Guidance for needle placement and treatment involved a combination of CT and fluoroscopy with a mobile C-arm system (Sire Mobile, Siemens Healthcare). The lesions were accessed with a 14-gauge Ostycut bone biopsy needle (Bard) or a 14-gauge Bonoptoy coaxial bone biopsy system (Radi Medical Systems). Biopsy was performed in three cases in which the lesion diameter was 1 cm or greater. Because the specimens were quite small, there was not enough material for a frozen section. Pathologic examination was performed on the permanent specimens, and the results were available only after several days. At institution 1, our experience has shown that the small gauge of the needles used and the limited material acquired from lesions smaller than 1 cm results in a high rate of nondiagnostic biopsies. For this reason, no biopsies were performed on lesions smaller than 1 cm.

An 18-gauge spinal needle was introduced coaxially through the 14-gauge access device. A flexible, single-use, bare-tipped, 400- μ m fiber with polymer cladding was measured outside the patient to ensure adequate placement within the center of the lesion and then placed coaxially through the 18-gauge spinal needle (Fig. 1). The measurements obtained at the beginning of the procedure were used to determine the amount of energy required to completely coagulate the tumor. A continuous-wave semiconductor portable diode laser (model 25 laser, Diomed) with an 805-nm wavelength was operated in continuous-wave mode, and the amount of energy to be delivered was calculated according to the formula $(NS \times 100 \text{ J}) + 200 \text{ J}$, where NS is nidus size in millimeters [19, 20, 23]. A maximum of 1,200 J was applied in 12 cases. One sacral lesion with a nidus exceeding 15 mm in diameter was managed by placement of two laser fibers simultaneously and application of 3,000 J. Patients were discharged the same day or stayed in the hospital overnight for observation.

At institution 2, RFA was performed with CT guidance (Somatom 4 scanner, Siemens Healthcare). The lesions were accessed with a 14-gauge Bonoptoy system, and biopsy with a 15-gauge Bonoptoy coaxial biopsy needle was attempted in all four cases. In three cases, an adequate speci-

men was obtained, and a permanent specimen was submitted for pathologic examination, the results being available after several days. No sample was obtained from the smallest of the four lesions. The biopsy needle was replaced with a radiofrequency probe (Cool-Tip, Covidien) with a 7-mm or 1-cm active tip. The probe generator was operated in the manual mode without a switch box. The output was gradually increased to achieve a temperature of 90°C.

The dimensions of the lesions as measured on the planning CT scan were used to determine the number of probe placements and radiofrequency applications (all at 90°C) necessary to completely ablate the tumor nidus without putting the neural elements at risk. At least one 6-minute application of the radiofrequency probe was used in each case with the number and length of subsequent overlapping treatments predicated on the position of the probe, the size of the active tip used, and the size and shape of the lesion. The internal cooling system was not used because it was considered to place the neural structures at greater risk. The patients were monitored in the postanesthesia recovery unit and discharged the same day. The patients were instructed to use pain medications as necessary.

Special techniques adapted specifically for ablation of tumors close to the neural elements were used in all cases at both institutions. At preliminary CT, the areas of greatest concern were identified as the central canal, neural foramen, or both. Under CT guidance, a 22-gauge spinal needle was introduced into the adjacent epidural

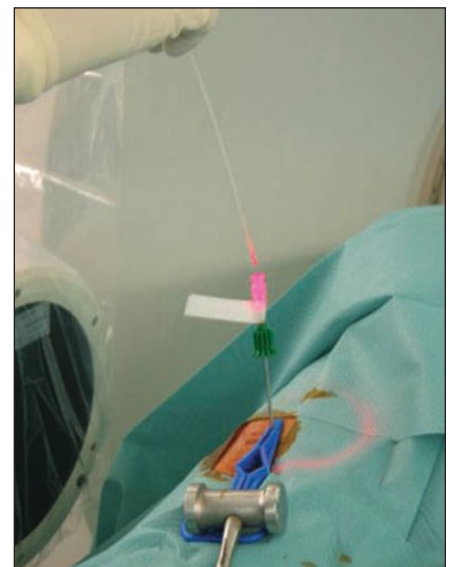


Fig. 1—Photograph depicts coaxial placement of optical fiber under imaging guidance for laser ablation of spinal osteoid osteoma. Both coaxial bone biopsy sheath and 18-gauge spinal needle have been introduced.

Thermal Ablation of Spinal Osteoid Osteomas

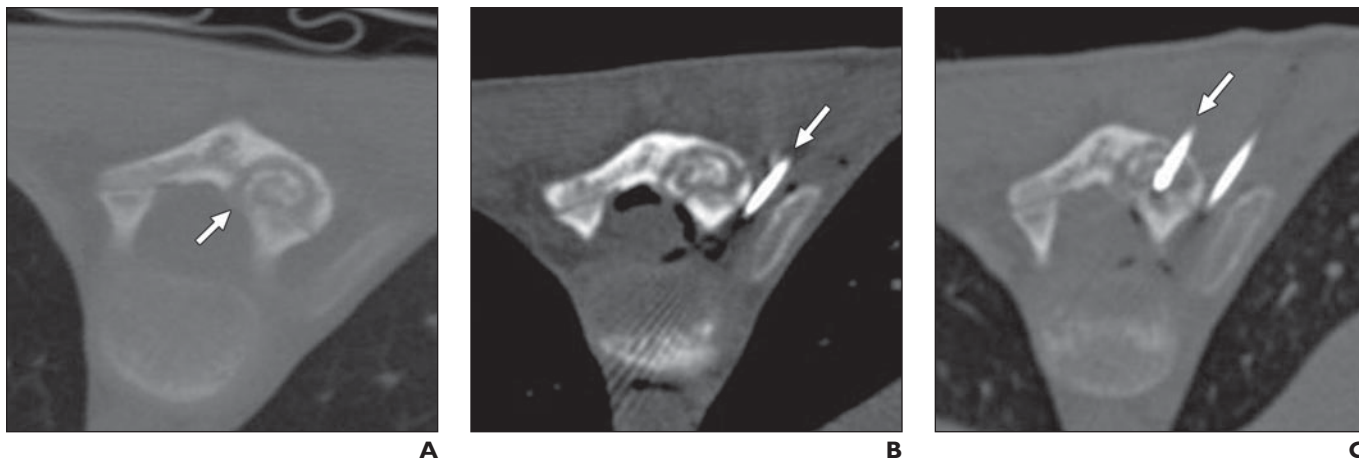


Fig. 2—12-year-old girl with osteoid osteoma in lamina of thoracic vertebra managed with radiofrequency ablation.

A, Initial CT scan shows lytic mildly expansile lesion in left lamina with central calcification. Cortical rim with adjacent central canal is incomplete in areas (arrow).
B, CT scan shows spinal needle (arrow) inserted in adjacent epidural space through transforaminal approach. Air outlines epidural space both centrally and within foramen.
C, CT scan shows radiofrequency probe (arrow) in center of lesion. Portion of epidural air has been replaced by fluid similar in attenuation to soft tissues.

space through a transforaminal or interlaminar approach or both. The interlaminar approach involved placing the spinal needle through the interlaminar space and ligamentum flavum into the epidural space on the same side of the lesion. The transforaminal approach involved placement of the spinal needle into the posterior aspect of the adjacent foramen through a posterolateral approach in the thoracic and lumbar spine and an anterolateral approach in the cervical spine.

An epidurogram was obtained by injection of 2–5 cm³ of air or carbon dioxide. The gas outlined the epidural space and in many cases succeeded in increasing the distance between the neural elements at risk and the lesion (Figs. 2 and 3). As an added precaution, fluid at room temperature or slightly cooled (dextrose 5% in water) was infused through the epidural needle at a rate of approximately 1–2 mL/min during the thermal ablation (Fig. 4). At institution 1, a thermocouple was placed coaxially through an 18-gauge spinal nee-

dle into the epidural or perineural space adjacent to the lesion in nine cases, and continuous monitoring was performed to ensure temperatures below the expected neurotoxic threshold (< 45°C).

Twenty-four hours and 1 week after treatment, patients at institution 1 evaluated pain relief using a visual analog scale. Further follow-up was performed at intervals of 2 months for the first 6 months and then yearly afterward. At institution 2, pain relief was assessed by telephone interview within 24 hours of the procedure; pain relief was assessed subjectively with no visual analog scale score assigned. Further follow-up was conducted with all four patients by telephone interview (range, 2–14 months; mean, 6 months).

Data Collection

Medical records were reviewed for patient sex and age at the time of procedure. The histologic diagnosis was obtained from the pathology reports when available. At institution 1, where laser

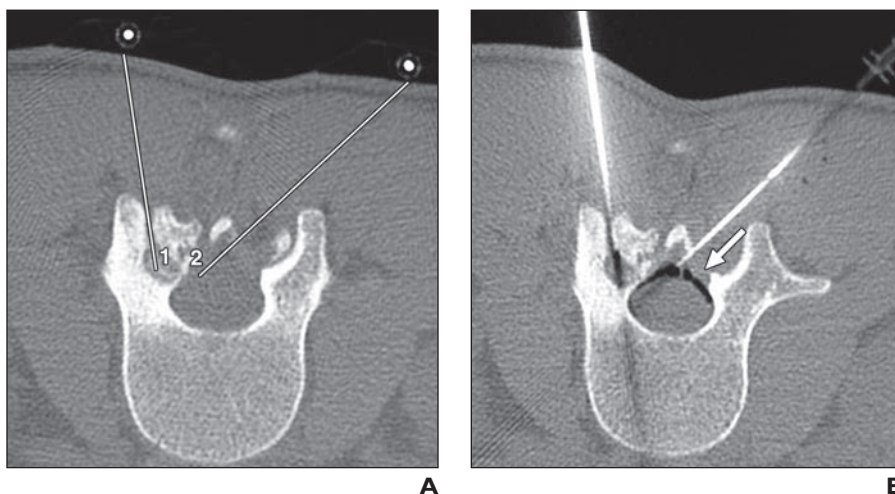
ablation was performed, reports of the procedures were reviewed to determine the energy delivered and the duration of laser application. At institution 2, where RFA was performed, the size of the probe, number of treatments administered, and overall duration of application of radiofrequency energy were noted. Any immediate complications encountered at either institution were noted.

Imaging Analysis

The CT images obtained at the procedure were reviewed, and all measurements were made by the respective author performing the ablation. Lesion location with respect to both the segment of the spinal column and position within a given vertebra was recorded. Note was made of the neural structures closest to the tumor. The dimensions of the lesions were obtained from the procedure reports, and the single largest dimension of each lesion was noted. Additional measurements were made on film at institution 1 and with a PACS at insti-

Fig. 3—18-year-old man with osteoid osteoma in articular process of lumbar vertebra managed with laser ablation.

A, Preprocedure planning CT scan shows plan for placement of both coaxial bone biopsy sheath (1) and second needle in epidural space (2).
B, CT scan shows coaxial bone biopsy sheath and epidural sheath in position and gas in posterior epidural space (arrow).



tution 2. The distance between the lesion and the closest neural element was recorded. The integrity of the cortical margin between the lesion and neural element was graded as completely intact (grade 1), intact over two thirds of the interface (grade 2), or largely destroyed with less than two thirds of the cortical interface intact (grade 3).

Clinical Analysis

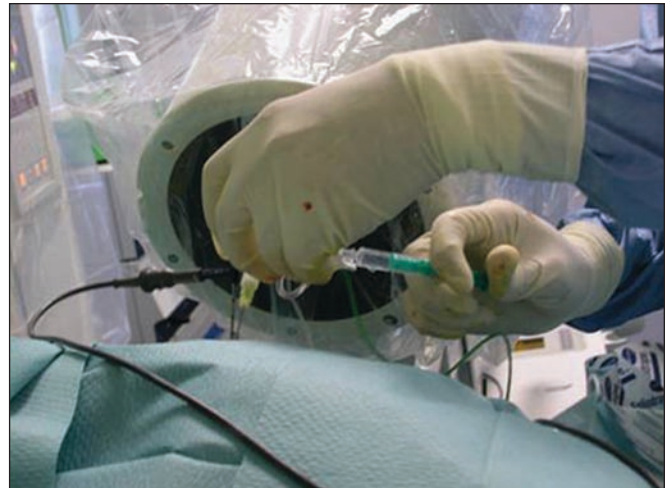The records were reviewed to determine the level of pain relief on postprocedure day 1. When available, findings from longer follow-up were recorded. Any symptoms at follow-up evaluation or complications necessitating additional treatment were noted.

Results

Patients and Procedure

Seventeen procedures on 17 patients (13 male patients, four female patients; age range, 12–44 years; mean, 25.9 years) were reviewed. The histologic diagnosis of osteoid osteoma was made in six cases. The patient and procedure information is shown in Table 1. At institution 1, where laser ablation was performed, the mean energy delivered for ablation purposes was 1,000 J (range, 700–3,000 J). At institution 2, where RFA was used, the radiofrequency probe sizes were 1 cm (two patients) and 7 mm (two patients).

Fig. 4—Photograph depicts operator introducing cooled fluid through tubing attached to second epidural needle during treatment.



The mean number of radiofrequency applications was 2.3 (range, 1–3). The mean duration of radiofrequency application was 11.3 minutes (range, 6–16 minutes).

Imaging

The lesions were located in the lumbar (seven patients), thoracic (six patients), cervical (three patients), and sacral (one patient) spinal segments. Two lesions were in the vertebral body and one within the dens of C2. The rest were within the posterior elements

in the lamina (seven patients), articular process (three patients), pedicle (three patients), and lateral mass (one patient). The lesions were believed to be in greatest proximity to the central canal (one patient) or neural foramen (13 patients) or in equal proximity to both structures (three patients). The mean single largest lesion dimension was 8.8 mm (range, 5–15 mm). The mean distance between the lesion and the closest neural element was 4.3 mm (range, 1–10 mm). The integrity of the cortical margin at the interface

TABLE 1: Patient, Tumor, and Treatment Characteristics

Patient No.	Age (y)	Sex	Spinal Level	Anatomic Site	Size (mm) ^a	Distance (mm) ^b	Ablation Type	Insulation
1	34	M	T2	Vertebral body	10	2	Laser	Cooled liquid, CO ₂
2	21	F	T12	Lamina	6	4	Laser	Air
3	19	M	L2	Articular process	6	4	Laser	Air
4	27	M	L2	Lamina	5	10	Laser	Cooled liquid
5	19	M	L3	Lamina	7	5	Laser	Air
6	44	M	L3	Pedicle	9	5	Laser	Cooled liquid, CO ₂
7	23	M	L4	Lamina	6	6	Laser	Cooled liquid
8	31	M	L5	Lamina	7	10	Laser	Air
9	12	M	S3	Lamina	15	7	Laser	Cooled liquid
10	33	M	C2	Base of dens	6	4	Laser	Cooled liquid, CO ₂
11	35	M	T2	Pedicle	7	2	Laser	CO ₂
12	34	M	T3	Vertebral body	12	1	Laser	CO ₂
13	39	F	C6	Lateral mass	9	1	Laser	CO ₂
14	12	F	T8	Articular process	14	2	Radiofrequency	Air, cooled liquid
15	21	M	L3	Lamina	14	3	Radiofrequency	Air, cooled liquid
16	22	M	C7	Pedicle	9	1	Radiofrequency	Air, cooled liquid
17	15	F	T12	Articular process	7	6	Radiofrequency	Air, cooled liquid
Mean	25.9				8.8	4.3		

^aSingle greatest dimension.

^bDistance between tumor and nearest neural structure in central canal or neural foramen.

Thermal Ablation of Spinal Osteoid Osteomas

with the closest neural elements was grade 1 (four patients), grade 2 (two patients), and grade 3 (11 patients).

Clinical Outcome

No immediate complications were reported. All 17 patients reported complete relief of their typical preprocedure pain within 48 hours with full return to normal activities. Findings from long-term follow-up (mean, 36.5 months; range, 2–84 months) were available for 11 of the 17 patients. All patients continued to be pain free without medication.

Discussion

Our results show that thermal ablation can be used effectively and safely to manage osteoid osteomas of the spine even when the lesion is within 1 cm of the adjacent neural elements or lacks a complete intervening rim of cortical bone. In the past, these techniques were avoided in the treatment of patients with spinal lesions because of the risk of thermal damage to the neural elements [9, 11–13]. Some authors have proposed alternative minimally invasive imaging-guided methods, including percutaneous trocar extraction and alcohol injection. Most patients, however, have undergone open excision, which can involve wide resection with the risks of postoperative instability and nerve damage [6, 9, 10].

In our series of 17 patients treated with laser (13 patients) or radiofrequency (four patients) ablation, the success rate was 100%, defined as postprocedure relief of osteoid osteoma–related pain and no complications. In long-term follow-up of 11 patients (mean, 36.5 months; range, 2–84 months), pain relief continued with no untoward side effects. Specifically, no patients had symptoms that could be construed as resulting from damage to neural structures. All of our patients had lesions within 1 cm of adjacent neural structures, and many had marked deficiency in intervening cortical bone at the interface between the tumor and the central canal or neural foramen.

We believe our cases constitute the largest published series of thermal ablations of spinal osteoid osteomas in general and of those close to the neural elements in particular. There have been reports [2, 5, 10, 19, 21, 24] of successful ablation of osteoid osteomas of the spine with both RFA and laser ablation. Many of these reports, however, involved lesions separated from the neural canal by an intact rim of cortical bone. Although Samaha et al. [18] reported on the use of RFA to manage three lesions of the neural

spinal ring that were “very close to the spinal canal” or “in direct contact with the nerve roots,” no measurements were provided.

Several publications [15–17] have focused on what are believed to be the major factors in heat transmission to the canal and perineural tissues during spinal ablation procedures. These factors have included proximity of the heat source, the possible insulating effect afforded by intervening medullary and cortical bone, and the length of the probe used. Dupuy et al. [15] performed in vivo experiments using a pig model and ex vivo experiments and found that both cancellous and cortical bone had an insulating effect. Those investigators also postulated a protective effect of epidural blood flow and CSF pulsation. This insulating effect of cortical bone was disputed in a study by Nour et al. [16] in which RFA on pigs resulted in several serious histologically confirmed neurologic injuries despite an intact intervening cortex. It should be noted, however, that the ablations in this study were performed with radiofrequency probes with 2-cm active tips maintaining a temperature of 90°C for 10 minutes. In experiments with pigs, Adachi et al. [17] found a significant difference in temperatures reached within the central canal during ablations with 1- and 2-cm active tips. These results would seem to imply that the length of the active tip may play a role in the frequency of neural injury.

Because of the conflicting results on the safety of ablation of spinal lesions both with and without an intact layer of cortical bone, it would seem prudent to use any and all means to achieve an additional margin of safety. Careful application of controlled radiofrequency or laser energy to selectively ablate the lesional tissue is mandatory, and the use of long active tips and cooled probes should be avoided if possible. Instead, small overlapping zones of ablation should be produced to avoid unnecessary deposition of energy in the surrounding tissues.

We believe that although it is impossible to substantiate in controlled human studies, an additional margin of safety is possible with the use of careful injection of insulating substances into the adjacent perineural space. Several publications support this contention. Gangi et al. [20] first reported the use of such a cool bath technique in a review of laser ablation of 114 osteoid osteomas. Klass et al. [22] reported on the successful ablation of seven spinal osteoid osteomas with radiofrequency and a similar technique.

Most radiologists who perform RFA are facile at the placement of needles under imaging guidance. Thus the additional step of placing a spinal needle into the epidural or periradicular space should not add much time to the procedure or result in added morbidity to the patient. In this series, initial insulation was achieved by injection of air or carbon dioxide to outline the epidural space, to create distance between the neural structures and the lesion, and to provide insulation. Additional insulation was produced by slow injection of room temperature or slightly cooled fluid during ablation.

Several limitations of this study should be noted. The study involved two academic centers using different techniques of thermal ablation. We believe, however, that this format gives the results more far-reaching implications. The study was not controlled, and for clinical and ethical reasons, no patients were randomly selected for treatment without the additional protective measures. For this reason, the added benefit of the techniques remains purely speculative. It would be useful to reproduce some of the in vivo animal experiments conducted by Dupuy et al. [15] and Nour et al. [16] using the additional protective techniques to see whether lower temperatures were registered within the perilesional soft tissues and the number of complications could be reduced. In addition, at institution 1, histologic proof of diagnosis was not available in 10 cases. We believe, however, that the diagnosis in these cases can be based on the typical imaging and clinical features and the patient response to treatment.

We maintain that percutaneous thermal ablation with RFA or laser ablation is a feasible and safe alternative to surgical excision in the management of osteoid osteomas of the spine, even in the care of patients in whom the lesion is less than 1 cm from an adjacent neural structure with no intact intervening cortex. We believe that thermal protection techniques, including instillation of epidural or periradicular gas or cooled fluid during ablation and the use of well-placed thermocouples for continuous temperature monitoring, may add an important margin of safety.

References

1. Jaffe H. “Osteoid osteomas,” a benign osteoblastic tumor composed of osteoid and atypical bone. *Arch Surg* 1935; 31:709–728
2. Hadjipavlou AG, Lander PH, Marchesi D, Katonis PG, Gaitanis IN. Minimally invasive surgery for ablation of osteoid osteomas of the spine. *Spine*

- 2003; 28:E472–E477
3. Ozaki T, Liljenqvist U, Hillmann A, et al. Osteoid osteomas and osteoblastoma of the spine: experiences with 22 patients. *Clin Orthop Relat Res* 2002; 394–402
 4. Pettine KA, Klassen RA. Osteoid-osteomas and osteoblastoma of the spine. *J Bone Joint Surg Am* 1986; 68:354–361
 5. Cove JA, Taminiau AH, Obermann WR, Vanderschueren GM. Osteoid osteomas of the spine treated with percutaneous computed tomography-guided thermocoagulation. *Spine* 2000; 25:1283–1286
 6. Faraj A, Byrne P, Mehdian H. Osteoid osteomas of the lateral mass of C5: should excision be combined with fusion? *Eur Spine J* 1998; 7:242–245
 7. Rosenthal DI, Springfield DS, Gebhardt MC, Rosenberg AE, Mankin HJ. Osteoid osteomas: percutaneous radio-frequency ablation. *Radiology* 1995; 197:451–454
 8. Zileli M, Cagli S, Basdemir G, Ersahin Y. Osteoid osteomas and osteoblastomas of the spine. *Neurosurg Focus* 2003; 15:E5
 9. Hempfing A, Hoffend J, Bitsch RG, Bernd L. The indication for gamma probe-guided surgery of spinal osteoid osteomas. *Eur Spine J* 2007; 16:1668–1672
 10. Laus M, Albisinni U, Alfonso C, Zappoli FA. Osteoid osteomas of the cervical spine: surgical treatment or percutaneous radiofrequency coagulation? *Eur Spine J* 2007; 16:2078–2082
 11. Rosenthal DI, Hornicek FJ, Torriani M, Gebhardt MC, Mankin HJ. Osteoid osteomas: percutaneous treatment with radiofrequency energy. *Radiology* 2003; 229:171–175
 12. Ghanem I. The management of osteoid osteomas: updates and controversies. *Curr Opin Pediatr* 2006; 18:36–41
 13. Lindner NJ, Ozaki T, Roedl R, Gosheger G, Winkelmann W, Wortler K. Percutaneous radiofrequency ablation in osteoid osteomas. *J Bone Joint Surg Br* 2001; 83:391–396
 14. Froese G, Das RM, Dunscombe PB. The sensitivity of the thoracolumbar spinal cord of the mouse to hyperthermia. *Radiat Res* 1991; 125:173–180
 15. Dupuy DE, Hong R, Oliver B, Goldberg SN. Radiofrequency ablation of spinal tumors: temperature distribution in the spinal canal. *AJR* 2000; 175:1263–1266
 16. Nour SG, Aschoff AJ, Mitchell IC, Emancipator SN, Duerk JL, Lewin JS. MR imaging-guided radiofrequency thermal ablation of the lumbar vertebrae in porcine models. *Radiology* 2002; 224: 452–462
 17. Adachi A, Kaminou T, Ogawa T, et al. Heat distribution in the spinal canal during radiofrequency ablation for vertebral lesions: study in swine. *Radiology* 2008; 247:374–380
 18. Samaha EI, Ghanem IB, Moussa RF, Kharrat KE, Okais NM, Dagher FM. Percutaneous radiofrequency coagulation of osteoid osteomas of the “neural spinal ring.” *Eur Spine J* 2005; 14:702–705
 19. Gangi A, Dietemann JL, Clavert JM, et al. Treatment of osteoid osteomas using laser photocoagulation: apropos of 28 cases [in French]. *Rev Chir Orthop Reparatrice Appar Mot* 1998; 84:676–684
 20. Gangi A, Alizadeh H, Wong L, Buy X, Dietemann JL, Roy C. Osteoid osteomas: percutaneous laser ablation and follow-up in 114 patients. *Radiology* 2007; 242:293–301
 21. Osti OL, Sebben R. High-frequency radio-wave ablation of osteoid osteomas in the lumbar spine. *Eur Spine J* 1998; 7:422–425
 22. Klass D, Marshall T, Toms A. CT-guided radiofrequency ablation of spinal osteoid osteomas with concomitant perineural and epidural irrigation for neuroprotection. *Eur Radiol* 2009; 19:2238–2243
 23. Gangi A, Basile A, Buy X, Alizadeh H, Sauer B, Bierry G. Radiofrequency and laser ablation of spinal lesions. *Semin Ultrasound CT MR* 2005; 26:89–97
 24. Woertler K, Vestring T, Boettner F, Winkelmann W, Heindel W, Lindner N. Osteoid osteomas: CT-guided percutaneous radiofrequency ablation and follow-up in 47 patients. *J Vasc Interv Radiol* 2001; 12:717–722