

# Role of Adjuvant Cryosurgery in Intralesional Treatment of Sacral Tumors

## Results of a 3–11-Year Follow-Up

Yehuda Kollender, M.D.<sup>1</sup>  
 Issac Meller, M.D.<sup>1</sup>  
 Jacob Bickels, M.D.<sup>1</sup>  
 Gideon Flusser, M.D.<sup>2</sup>  
 Josefin Issakov, M.D.<sup>3</sup>  
 Ofer Merimsky, M.D.<sup>4</sup>  
 Nissim Marouani, M.D.<sup>5</sup>  
 Alexander Nirkin, M.D.<sup>1</sup>  
 Avi A. Weinbroum, M.D.<sup>5</sup>

<sup>1</sup> National Orthopedic Oncology Unit, Tel-Aviv Sourasky Medical Center, Sackler Faculty of Medicine, Tel Aviv University, Tel Aviv, Israel.

<sup>2</sup> Department of Radiology, Tel-Aviv Sourasky Medical Center, Sackler Faculty of Medicine, Tel Aviv University, Tel Aviv, Israel.

<sup>3</sup> Department of Pathology, Tel-Aviv Sourasky Medical Center, Tel-Aviv Sourasky Medical Center, Sackler Faculty of Medicine, Tel Aviv University, Tel Aviv, Israel.

<sup>4</sup> Bone and Soft Tissue Oncology Unit, Tel-Aviv Sourasky Medical Center, Sackler Faculty of Medicine, Tel Aviv University, Tel Aviv, Israel.

<sup>5</sup> Post-Anesthesia Care and Acute Pain Control Unit, Tel-Aviv Sourasky Medical Center, Sackler Faculty of Medicine, Tel Aviv University, Tel Aviv, Israel.

The authors thank Esther Eshkol for her editorial assistance.

Address for reprints: Avi A. Weinbroum, M.D., Post-Anesthesia Care Unit, Tel Aviv Sourasky Medical Center, 6 Weizman Street, Tel Aviv 64239, Israel; Fax: (011) 972-3-6925749; E-mail: draviv@tasmc.health.gov.il

The authors declare that they have neither obligation to the manufacturers of the CRYO-HIT system, nor have they any financial interest, consultative agreement, stock or other interest in the company.

Received August 8, 2002; revision received January 30, 2003; accepted February 6, 2003.

**BACKGROUND.** Cryosurgery is an adjuvant surgical technique for the treatment of benign aggressive, low-grade malignant and metastatic tumors of long bones. It has been used rarely to treat sacral tumors, mainly because of potential damage to nerves, blood vessels, and intrapelvic organs. The authors described their experience with this procedure and provided medium and long-term follow-up results. **METHODS.** Fifteen procedures of cryosurgery of the sacrum were performed in 14 patients to improve the therapeutic outcome of a variety of tumors. The patient group included 7 males and 7 females with a mean age of  $42 \pm 24$  years. Three patients were younger than 20 years of age. The procedures were performed at the Tel Aviv Sourasky Medical Center between January 1991 and January 1999. There were seven benign aggressive lesions (four giant cell tumors and three aneurysmal bone cysts), one benign schwannoma, one low-grade chondrosarcoma, five metastatic carcinomas, and one high-grade Ewing sarcoma, all localized at level S<sub>2</sub> or higher. Eight of the bone tumors also involved significant anterior or posterior soft tissue. All patients had severe preoperative pain radiating to the buttocks, perineum, and lower limbs and 9 (64%) patients had bladder and/or rectal dysfunction. Invasive diagnostic procedures and radiation (if warranted) preceded surgery. Sacral posterior fenestration and burr drilling were followed by two-cycle cryosurgery using the open pour technique or the argon-helium-based heat-freeze system.

**RESULTS.** All interventions were performed under combined general and regional anesthesia and concluded uneventfully with moderate blood loss. Thirteen patients were discharged home after  $8 \pm 5$  days (one patient remained hospitalized for 30 days). Only two patients experienced local disease recurrence during a 3–11-year follow-up period: one was retreated successfully by cryosurgery and the other underwent sacrectomy and radiotherapy elsewhere, with a subsequent loss of visceral functions. No patient suffered chronic pain, deep wound infections, or significant neurologic deficits and all were satisfied with the esthetic outcome.

**CONCLUSIONS.** Cryosurgery is a conservative, feasible, and safe adjuvant technique in the treatment of sacral tumors. It is associated with minimal permanent neurologic and vascular injury compared with sacrectomy. *Cancer* 2003;97:2830–8.

© 2003 American Cancer Society.

DOI 10.1002/cncr.11383

**KEYWORDS:** cryosurgery, sacral tumors, intralesional, adjuvant.

**T**he early symptoms of sacral tumors, consisting mainly of localized or referred pain, are usually nonspecific and, therefore, the lesions are diagnosed at a late stage.<sup>1</sup> Bladder, rectal, and/or sexual dysfunction are symptoms of late-stage tumors. Sacral tumors are often overlooked on plain X-ray films.<sup>1</sup> The most common primary benign

tumor of the sacrum, a giant cell tumor (GCT), represents 70% of all sacral tumors.<sup>1,2</sup> Other benign tumors include aneurysmal bone cysts (ABC) and simple bone cysts.<sup>1,3</sup> Primary malignant bone tumors of the sacrum are rare, with chordoma accounting for 40% of all such malignancies.<sup>1,3</sup> Other primary malignant tumors of the sacrum include myeloma, chondrosarcoma, osteosarcoma, Ewing sarcoma, and lymphoma.<sup>1,2,4</sup> Metastatic tumors comprise the majority of malignant lesions in the sacrum.<sup>1,5,6</sup> Although rectal carcinoma can metastasize and directly involve the sacrum as a local recurrence, most sacral metastatic tumors are the result of hematogenously spread tumoral cells originating from carcinomas of the breast, lung, kidney, thyroid, and prostate.<sup>1,4</sup>

The sacral region is a major neurovascular crossroad, innervating and supplying blood to the lower part of the body. It also determines the functional state of delicate and complex sphincters of the rectum, bladder, and sexual organs, as well as the motor, sensory, and vasomotor functions of the lower limbs.<sup>4</sup>

There are currently three traditional methods for localized intervention in cases of sacral tumors. The first technique is bone resection, which is applicable to all types of sacral tumors. This is a high-risk procedure that bears a high rate of morbidity, including massive bleeding, infection, cerebrospinal fluid (CSF) leak, severe neurologic deficits (e.g., rectal and bowel incontinence and lower limb motor and sensory deficiency), and pelvic and spinal skeletal instability.<sup>4</sup> The other two approaches are radiotherapy and vascular angioembolization of the tumor. Radiotherapy is effective for Ewing sarcoma, GCT, and ABC. However, GCT and ABC may later evolve into postradiation sarcoma,<sup>2</sup> whereas radiation for Ewing sarcoma is only one part of the accepted comprehensive treatment protocol (chemotherapy, radiotherapy, and surgery). Both radiotherapy and vascular angioembolization may still result in a high rate of disease recurrence.<sup>4</sup> Therefore, these two approaches are considered to be palliative by intention.

Cryosurgery manifests its effects via direct injury to cells due to tissue ice crystal formation and the microcirculatory breakdown associated with thawing. As the temperature rises during thawing, these crystals coalesce and mechanically disrupt the cell membrane, causing cell death. This leads to tissue edema and an osmotic effect that causes microcirculatory failure.<sup>7</sup> An excellent review of the mechanism that is at the base of this biomolecular system was published by Gage and Baust.<sup>8</sup> Marcove and Miller<sup>6</sup> were the first to describe the method of cryosurgery for bone surgery in the late 1960s. Cryosurgery for bone tumors was improved and endorsed by Malawer et al.<sup>9</sup> Marcove

and colleagues<sup>2,6,10,11</sup> suggested the applicability of this method in cases of sacral bone metastasis. They later expanded the indication to cases of primary bone tumors as well, including GCT and sarcomas.<sup>2,6,10,11</sup> The then-used 'open system' methodology consisted of pouring liquid nitrogen into the bone cavity immediately after having performed curettage. To our knowledge, the use of cryosurgery as an integral, although adjuvant, part of sacral tumor treatment has been reported only twice during the last 20 years. In 1986, de Vries et al.<sup>3</sup> described their experience in 4 patients with chordoma and Marcove et al.<sup>2</sup> reported their experience with 7 patients with GCT of the sacrum. To our knowledge, there are no later reports on cryosurgery for sacral tumors, probably because of the surgeon's reluctance to risk injury to major nerves, impair the function of pelvic organs, or increase the incidence of complications.

The current study describes our 3–11-year experience with cryosurgery. The procedure was performed 15 times in the treatment of various sacral tumors in 14 patients. We discuss the surgical outcome and describe the patients' clinical results during this medium and long-term follow-up period and compare them with the results of other surgical approaches that are available in the literature.

## MATERIALS AND METHODS

Fourteen patients with various sacral tumors underwent bone curettage followed by cryosurgery between January 1991 and January 1999 (Table 1). There were 7 males and 7 females (age range, 14–74 years). Three patients were younger than age 20 years and 5 were age 60 years or older.

### Tumor Distribution

There were seven benign aggressive tumors: three GCTs (one of which was operated twice) and an ABC in each of another three. In addition, there was one benign schwannoma, one low-grade chondrosarcoma, five metastatic carcinomas (two metastases from colon carcinoma, two from renal cell carcinoma, and one from breast carcinoma), and one high-grade Ewing sarcoma.

### Anatomic Location, Medical History, and Preoperative Preparation

Four patients (Patients 1, 3, 4, and 13) had lesions that occupied the entire sacrum and 3 patients (Patients 6, 10, and 14) had lesions that occupied the midsacrum. Seven lesions (in Patients 2, 5, 7, 8, 9, 11, and 12) were localized in one of the sacral alae (Fig. 1). Ewing sarcoma (Patient 7) also involved the posterior iliac and sacral bones. All tumors reached the dermatome level

**TABLE 1**  
**Demographic and Pathologic Data (Chronologic Order of Surgery)**

Patient no.	Age (yrs)	Gender	Site of lesion	Diagnosis	Date of surgery
1	21	F	Whole sacrum	Giant cell tumor	May 1991, <sup>a</sup> December 1997, August 1998
2	74	F	Left sacrum	Chondrosarcoma	May 1992
3	69	M	Whole sacrum	Metastatic renal cell Carcinoma	October 1993
4	16	M	Whole sacrum	Aneurysmal bone cyst	September 1994
5	22	M	Right sacrum	Giant cell tumor	May 1995
6	55	F	Midsacrum	Metastatic renal cell carcinoma	April 1996
7	16	F	Left sacrum	Ewing sarcoma	June 1996
8	14	M	Right sacrum	Aneurysmal bone cyst	October 1996
9	25	M	Right sacrum	Giant cell tumor	May 1997, <sup>a</sup> June 1998 <sup>b</sup>
10	23	M	Midsacrum	Aneurysmal bone cyst	August 1998
11	51	F	Left sacrum	Metastatic carcinoma	August 1998
12	74	F	Left sacrum	Metastatic carcinoma	August 1998
13	71	F	Whole sacrum	Schwannoma	September 1998
14	60	M	Midsacrum	Metastatic colon Carcinoma	January 1999

<sup>a</sup> Local disease recurrence occurred 7 years after the first operation.

<sup>b</sup> Sacrectomy and radiotherapy done elsewhere.

of S<sub>2</sub> or higher. Because interventions to remove tumors at or below the level of S<sub>3</sub> are neurologically safe, they are not included in this study. Of the 14 study patients, 8 had tumoral masses that comprised large areas of the anterior or posterior (or both) soft tissues as well (see below).

All patients had suffered from severe and progressive pain for 4–18 months before surgery. The pain had originated and was localized within the tumoral site but sometimes also radiated to the buttocks, perineum, and lower limbs (sciatic pain). All patients required considerable amounts of nonsteroidal anti-inflammatory drugs (NSAIDs) and narcotics. Nine patients had bladder and/or rectal dysfunction as well, ranging from mild symptoms of urinary urgency or rectal soiling to complete urinary retention, incontinence and/or constipation, or involuntary defecation. Four of these nine patients underwent preoperative urinary and/or rectal digital examination, validated questionnaires, and manometry measurements to stage organ dysfunction. Neurogenic bladder and/or rectal dysfunction was present in all, and all declined to undergo a second round of objective tests following surgery because they had improved both subjectively and clinically.

All 14 patients underwent preoperative tumor staging studies, which included plain X-rays of the chest, pelvis, and sacrum, total body bone scan, and computed tomography (CT) and/or magnetic resonance imaging (MRI) scans of the sacrum and pelvic areas (Table 2, Fig. 1).

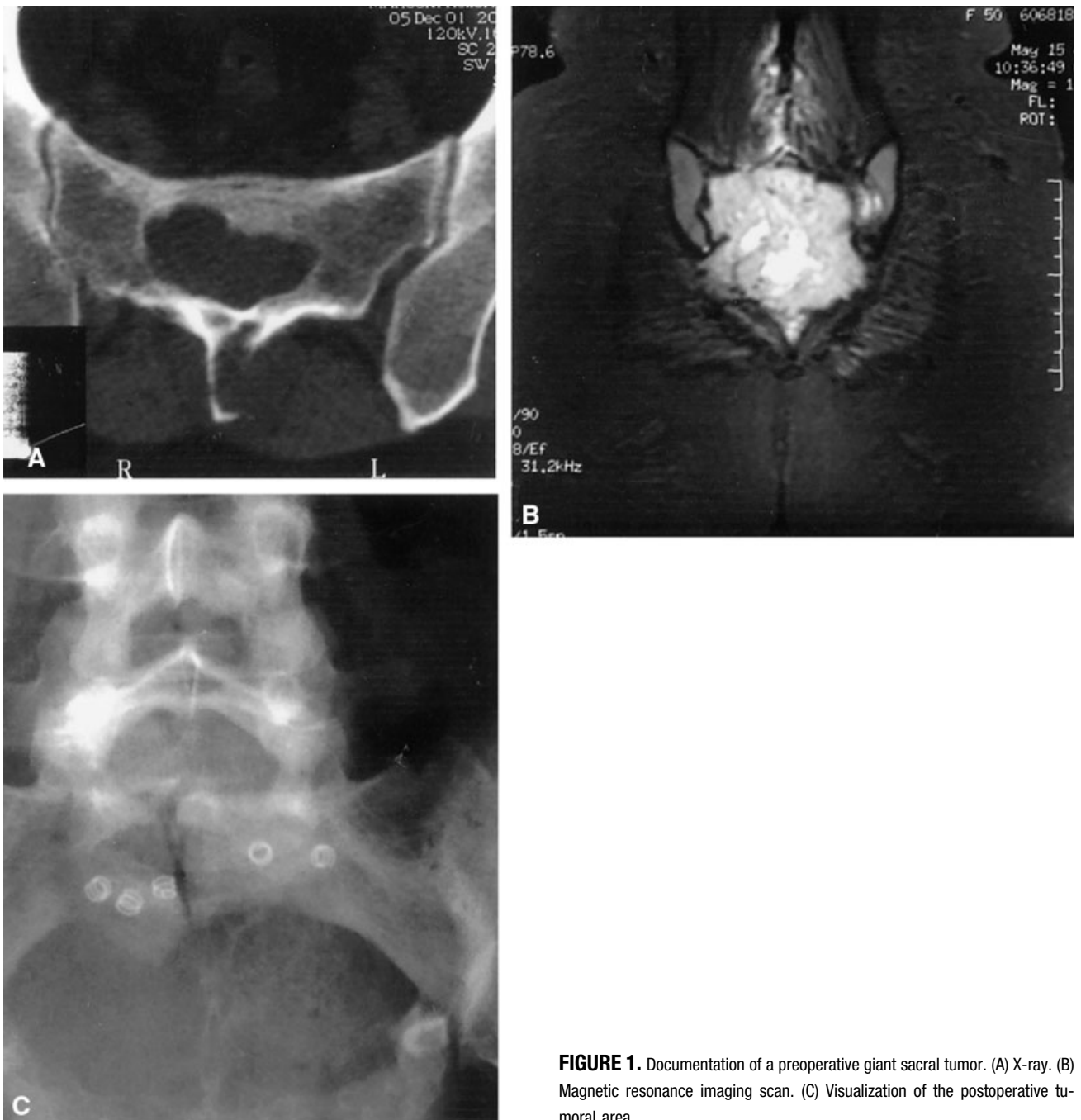Five patients (Patients 3, 6, 11, 12, and 14) who suffered from sacral metastatic lesions were referred

to the Orthopedic Oncology Unit (Tel-Aviv Sourasky Medical Center) after an unsuccessful course of radiotherapy (30–40 Gy). A CT scan showed disease progression in three of these patients. The patient who presented with Ewing sarcoma had been treated with a combination of neoadjuvant chemotherapy and radiotherapy (45 Gy) before being referred for surgery. Postoperatively, this patient received an additional 25 Gy (for a total of 70 Gy) of radiotherapy and neoadjuvant chemotherapy.

Seven patients (Table 2) underwent preoperative angiography to determine the best surgical strategy. Three of these patients underwent angioembolization of the supplying vessels to the tumor at the same session so that intraoperative blood loss would be minimized (Fig. 2) as demonstrated in a previous study.<sup>5</sup> This technique was especially useful when the tumors were associated with large soft-tissue components. Anterior masses were identified in two GCTs and in one metastatic renal cell carcinoma. Posterior soft-tissue components were diagnosed in one chondrosarcoma, one GCT, one Ewing sarcoma, and one ABC. Anterior and posterior masses were identified in the patient with metastatic colon carcinoma. Angioembolization was planned for all patients. However, it was not performed in patients who underwent angiography if this procedure was not justified by the radiologist, mainly due to lack of a major vascular supply to the tumor.

#### **Anesthesia and Perioperative Pain Control**

All patients were prepared well in advance of surgery by a team composed of the same surgeon, the same



**FIGURE 1.** Documentation of a preoperative giant sacral tumor. (A) X-ray. (B) Magnetic resonance imaging scan. (C) Visualization of the postoperative tumoral area.

anesthesiologist, an acute pain service physician, a nurse, and a social worker. Coagulation status, platelet count, and hemoglobin and blood electrolyte levels were evaluated for each patient. Echocardiography and multigated analysis using radiolabeled red blood cells (which subsequently enabled the calculation of the relative left ventricular ejection fraction and identification of myocardial wall motion abnormalities) were performed in patients who had undergone previous cardiotoxic chemotherapy (e.g., doxorubicin).

All patients underwent bowel preparation and perioperatively received cephalosporin-based antibiotics for 2 weeks. No patient received perioperative anticoagulants.

All patients received standardized combined general anesthesia and regional block. This combination allowed preemptive and better perioperative analgesia.<sup>12,13</sup> In the latter years of the study, continuous patient-controlled epidural analgesia became available to the patient for 72–96 hours postoperatively.

**TABLE 2**  
**Perioperative Data**

Patient no. <sup>a</sup>	Surgery (min)	Blood (units)	Preoperative staging studies	Immediate complications
1	230	8	X-ray, bone scan, CT, MRI, <sup>b</sup> angiography <sup>c</sup>	None
2	80	2	X-ray, bone scan, CT	None
3	110	1	X-ray, bone scan, CT, angiography <sup>c</sup>	Lower limb paresthesia
4	125	2	X-ray, bone scan, CT	Urinary incontinence
5	95	1	X-ray, bone scan, CT, angiography	None
6	160	4	X-ray, bone scan, CT, MRI, angiography <sup>c</sup>	None
7	65	2	X-ray, bone scan, CT, MRI	None
8	115	1	X-ray, bone scan, CT, MRI, angiography	None
9	125	2	X-ray, bone scan, CT, MRI, angiography	Wound dehiscence
10	100	2	X-ray, bone scan, CT, MRI, angiography	None
11	125	2	X-ray, bone scan, CT, MRI	None
12	120	2	X-ray, bone scan, CT, MRI	None
13	95	1	X-ray, bone scan, CT, MRI	Drain tear
14	120	2	X-ray, bone scan, CT, MRI	CSF leakage

CT: computed tomography scan; MRI, magnetic resonance imaging scan; CSF, cerebrospinal fluid.

<sup>a</sup> Patients 6–14 underwent MRI scans, which were not available for the first 5 patients.

<sup>b</sup> Patient underwent an MRI before the second procedure in 1997.

<sup>c</sup> Angiography was followed by angioembolization.

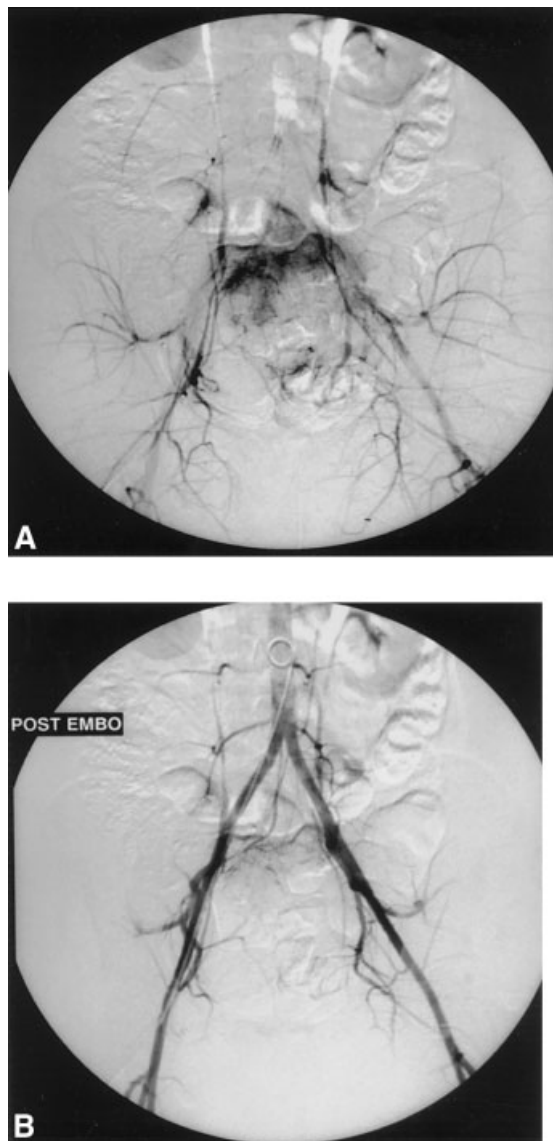
Intramuscular rescue NSAIDs and oral cyclooxygenase-2 inhibitors were also available upon patient request.

### Methodology of Cryosurgery

Patients were placed in the prone position. The surgeon approached the lesion from the back in a mid-longitudinal direction, making either a curved lateral incision when the tumor occupied one lateral side of the sacrum, a midlongitudinal incision at the level of L<sub>4</sub> down to the coccyx when the tumor was located at the center of the sacrum, or a T-shaped incision at the same level when the tumor occupied the entire bone. The first surgical step (Fig. 3) was fenestration of the posterior sacral wall (i.e., unroofing of the sacrum or sacral laminectomy), which was followed by bone curettage. Blunt finger debulking was used initially, especially for the anterior soft-tissue components of the tumors, followed by curettage with curettes and burr drilling. The curettage was performed until no macroscopic tumor was visible. During this step, the surgeon wore magnifying glasses to better visualize and preserve the nerve roots. In the procedures performed until August 1997, the third step, cryosurgery, consisted of the original open direct pour method that used liquid nitrogen.<sup>2,6,10,11</sup> The CRYO-HIT system (argon-helium-based probes in a gel medium; Galil Medical Ltd., Yokneam, Israel) was used thereafter.<sup>14,15</sup> Specifically, the CRYO-HIT system employs deep-freezing and heat argon and helium, respectively, separately contained in high-pressure contain-

ers. The release of either gas is computer controlled. The gas is conveyed to specially designed probes with diameters ranging from 3 to 30 mm to fit bone defects of different sizes. Argon is used for freezing the tissue (–150 °C) and helium is used for heating the tissue (+80 °C), thus obtaining total cell death in the vicinity of the probes.<sup>16,17</sup> Unlike the Marcove et al.<sup>2</sup> description of three consecutive cycles of freeze-thaw, we used two cycles for both the original and the newer technique, based on previous studies.<sup>7,15</sup> During the freezing step, a thermocouple was placed at the macroscopically normal-looking bone cavity margin, thereby detecting the actual temperature at that specific point. The absence of disease recurrence in 13 of 15 interventions in the current study further established the efficacy of two cycles of cryoadjuvant procedures in addition to angioembolization and radiotherapy (wherever applicable). The subsequent clinical signs and X-rays as well as CT scans of the surgical bed best evaluated the necrosis in the operated field caused by the two-cycle cryosurgery-associated procedures.

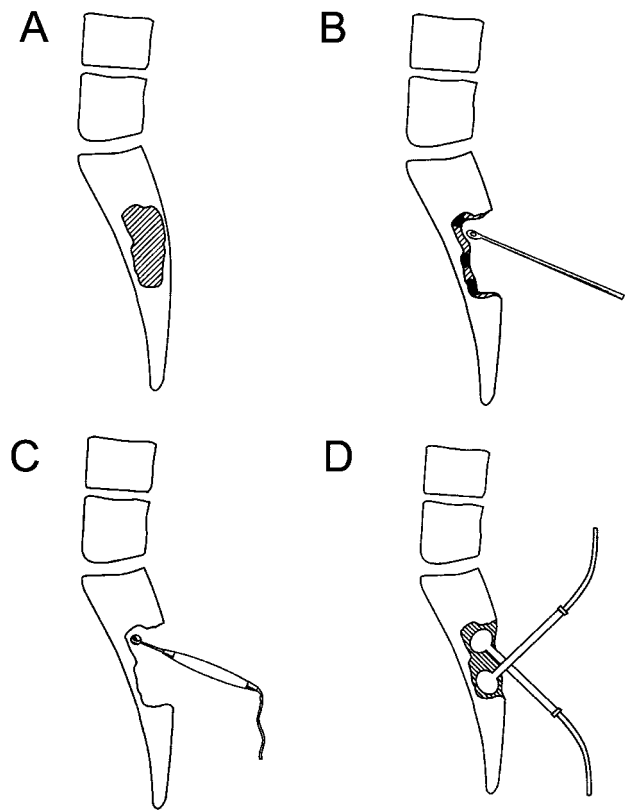
Unlike the classic surgical procedures in long bone tumors, there was no need for a reconstructive element of the sacral cavity in our patients, because the sacrum has no significant mechanical weight properties except for its rostral part (S<sub>1</sub>). This portion plays the role of a bridge between the lumbar spine and the pelvis and because it was always preserved, the mechanical properties remained intact. The cavity was filled with bone cement, which was also used as a



**FIGURE 2.** (A) Preangiogram and (B) postangiogram of the vascular supply to the tumoral area.

marker for future purposes (either for radiotherapy or for a better follow-up), in five patients (Patients 2, 3, 6, 11, and 13). To protect nerve roots and plexuses from eventual damage during the stage of bone cementation, they were wrapped carefully with gel foam.

Patients were scheduled to return to the Orthopedic Oncological Outpatient Service for follow-up every 3 months during the first 2 years and every 6 months thereafter. They also were encouraged to contact the attending physician whenever they felt a need to do so. X-rays, CT scans of the sacrum (and of the chest in the Ewings tumor patient), and MRI and bone scans also were performed during the scheduled follow-up visits (Table 3).



**FIGURE 3.** The cryosurgery (CRYO-HIT) adjuvant technique. Fenestration of the tumor (A), manual curettage (B), burr drilling (mechanical curettage, C), and cryosurgical procedure (D).

## RESULTS

### Intrasurgery and Immediate Postsurgery Data

The duration of surgery ranged from 1.1 to 4 hours, and blood loss ranged from 1 to 8 units per patient (Table 2). All patients awoke satisfactorily, and none required prolonged ventilation. All postoperative epidural blocks were usable as had been planned earlier.

No signs of deep wound infection, skin necrosis, or fractures *ex novo* were noted after surgery or before discharge from hospital. Patient 9 experienced delayed wound healing, and Patient 4 developed urinary incontinence, which resolved spontaneously less than 6 months after surgery. Patient 14 developed CSF leakage 5 days after surgery and was treated with proximal drainage; the leakage stopped within 2 weeks. The patients with sphincter dysfunction had return of function postoperatively.

Two patients (Patients 9 and 1) developed local recurrent tumors. Patient 9 was diagnosed with a recurrent GCT at the original site 1 year after surgery (Fig. 4). He declined to reundergo cryosurgery but underwent subtotal sacrectomy elsewhere, followed by radiotherapy. He remained disease free for 2 years

**TABLE 3**  
**Medium- and Long-Term Follow-Up**

Patient	Follow-up duration (yrs)	Follow-up imaging	Current oncologic status	Survival time
1	3-11	CT, bone scan, X-ray, MRI	NED	Indefinite
2	10	CT, bone scan, X-ray	NED	Indefinite
3	9	CT, bone scan, X-ray	Systemic metastasis; no local disease recurrence	36 mos
4	8	CT, bone scan, X-ray	NED	Indefinite
5	7	CT, bone scan, MRI, X-ray	NED	Indefinite
6	6	CT, bone scan, X-ray, MRI	Systemic metastasis; no local disease recurrence	Indefinite
7	6	CT, bone scan, MRI, X-ray, SPET scan	NED	Indefinite
8	6	CT, bone scan, X-ray	NED	Indefinite
9	4-5	CT, bone scan, MRI, X-ray	NED	Indefinite
10	4	CT, bone scan, MRI, X-ray	NED	Indefinite
11	4	CT, bone scan, X-ray	Systemic metastasis; no local disease recurrence	6 mos
12	4	CT, bone scan, X-ray	Systemic metastasis; no local disease recurrence	22 mos
13	4	Bone scan, MRI, X-ray	NED	Indefinite
14	3	CT, bone scan, X-ray	Systemic metastasis; no local disease recurrence	12 mos

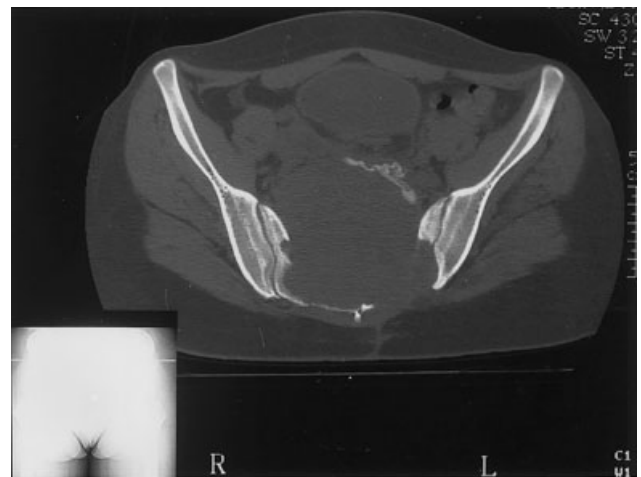
CT: computed tomography scan; MRI: magnetic resonance imaging scan; NED: no evidence of disease.

but had complete loss of urinary, rectal, and sexual functions. Patient 1, who had also presented with a GCT, developed a local recurrent tumor 5 years after the original surgery. This patient, a noncompliant Arabic village woman who did not return for follow-up care during the entire 5-year-period, developed a 35-cm anterior soft-tissue mass that occupied the entire pelvis and lower abdomen. After refusing treatment initially, she underwent a multistage surgical procedure consisting of anterior abdominal and pelvic debulking and a temporary colostomy followed by sacral debulking and cryosurgery (via a posterior approach). She underwent repeated surgical procedures (including closure of a colostomy) and prolonged physical and psychologic rehabilitation during the next 12-month period. The 3-year follow-up evaluation revealed neither local nor systemic disease nor loss of function of bladder or rectum. There was only a minimal motor deficiency in the left leg that improved over time.

Patient 7, an adolescent female, had Ewing sarcoma of the posterior ilium and part of the sacrum. The ilial part of the bone was resected, and cryosurgery was applied to the sacrum. This approach was chosen to avoid major functional and psychologic disturbances to the young girl.

#### Late Postsurgery Follow-Up

The maximum follow-up period was 11 years. The 7 patients (8 occurrences) who had suffered from benign tumors (Patients 1, 4, 5, 8, 9, 10, and 13) had no evidence of disease at the end of their follow-up periods. Patient 7 (the adolescent girl with Ewing sarcoma)



**FIGURE 4.** Computed tomography scan of a local recurrent tumor in Patient 9. The central area represents a recurrent giant cell tumor with an anterior large soft tissue component.

remained disease free for 4 years after the last postsurgery oncologic treatment. Of the 5 patients with metastatic tumors (Patients 3, 6, 11, 12, and 14), 4 (Patients 3, 11, 12, and 14) died 6-36 months after surgery due to a spread of the primary tumor but with no clinical or radiologic evidence of local or regional recurrence. The fifth patient (Patient 6), who had metastatic renal cell carcinoma, showed no evidence of recurrence in the sacrum or in its surrounding bones or soft tissues. However, there were clinical and imaging indications of a systemic spread of the primary malignancy into the body of the T<sub>4</sub> vertebra and within the lungs by the end of his 6-year follow-up period.

The perioperative emotional status of the patients was good, presumably because of the reassurance given to them regarding the esthetic preservation of the sacrum in addition to the anticipation of a high probability of cure and good functional outcomes. The rehabilitation principles were adapted from those of the pelvic girdle, because the sacrum is the posterior component of the pelvic ring.<sup>18</sup> The program of rehabilitation consisted of remaining in bed for 4–7 days, depending on the extent of surgery and the patient's age; learning to mobilize in bed (e.g., using the other limb or the torso); starting partial weight bearing with ambulatory aids for an average of 6–12 days (special techniques are taught when needed); and achieving full weight-bearing and normal walking within 4–12 weeks.

## DISCUSSION

Bone tumors in the sacral region have multiple origins. Their eradication is difficult but essential, not only to allow for cure but also to preserve essential organ function and lower body function and mobility, to maintain weight-bearing stability, and to minimize aesthetic repercussions. Cryosurgery, as an adjuvant technique to intralesional tumoral excision with or without angioembolization and radiotherapy, was effective in 87% (13 of 15) of patients diagnosed with primary and metastatic tumors. It achieved an overall medium- and long-term curative success rate of 92% of those 13 patients. This freeze-thaw technique was successful in reaching these objectives without inducing major somatic, visceral, or motor deficits and with complete patient satisfaction.

Compared with soft tissue tumors, bone tumors are more difficult to treat. To reach the tumoral site, it is necessary to open a cavity within the bone and curette the tumoral material. Only then, based on the appearance of the cavity, may cryosurgery be implemented.

The history of cryosurgery dates back to the 19th century.<sup>19</sup> As early as 1851, Archibald Arnott, a surgeon in the service of the East Indian Trade Company, described the use of ice-cold salt solution and crushed ice at temperatures ranging from  $-18^{\circ}\text{C}$  to  $-24^{\circ}\text{C}$  as an adjuvant treatment for advanced-stage breast or cervical carcinoma.<sup>19</sup> Since then, this concept has been applied to soft tissue and parenchymatous tumors in the liver, prostate, skin, breast, and cervix.<sup>20</sup> The technique has improved considerably in the last few decades with the introduction of liquid nitrogen into medicine. It enabled reaching a freezing point as low as  $-150^{\circ}\text{C}$ . Special extra-thin (diameter,  $< 10$  mm) probes now can limit the freezing effect to a finely delineated site without involving the surround-

ing tissues. This advancement significantly improved the ability to reach both hard to reach and deep tumoral locations and to target freezing damage and necrosis exclusively to the center of even small tumors.<sup>15</sup>

Primary and metastatic sacral tumors impose a surgical challenge due to their proximity to nerve roots and their branches, to large and small blood vessels, and to the complex rectal, bladder, and sexual functions. Although sacral tumors are treated successfully with sacrectomy,<sup>4</sup> rectal, bladder, and sexual functional outcomes are poor, especially if the lesion is located as high as S<sub>1-2</sub>. Permanent functional, sensory, and motor losses in the lower limbs also were reported in 30–100% of published cases of sacrectomy at these levels.<sup>4,21</sup> These disabilities were so serious, both physically and psychologically, that both surgeons and patients have become reluctant to opt for even careful and straightforward sacral surgery.

Cryosurgery for sacral tumors has been reported only twice, once in 1986 by de Vries et al.<sup>3</sup> for the eradication of sacral chordoma in four patients and later, in 1994, by Marcove et al.<sup>2</sup> who treated 7 patients for GCT of the sacrum. Although these authors did not encounter major postoperative dysfunctions, others have warned of a possible vascular and neurologic catastrophe to the neighboring intrapelvic organs.<sup>7</sup> Our current study of a relatively large cohort adds, we believe for the first time, valuable support to the two pioneering reports. We found that, from an oncologic and functional standpoint, the results are optimal for surgery that combines radiotherapy, burr drilling, and the two-cycle cryosurgery technique. We could conclude from the results of our 3–11-year follow-up, the longest of its kind, that cryosurgery-associated interventions resulted in no devastating postoperative complications. Although disease recurrence occurred at a low rate (15%; 2 of 13 patients) after the adjuvant cryosurgery procedure, the only patient in whom we observed an important loss of neurologically generated visceral functions was the one who underwent a subsequent subtotal sacrectomy elsewhere. The only literature data available to compare with our data are those of a long-term analysis of GCT of the extremities. In that study, Malawer et al.<sup>9</sup> reported that 2.3% of patients had cryosurgery-induced complications and 7.9% developed disease recurrence. We also documented, apparently for the first time, that cryosurgery was a beneficial adjuvant procedure in the complex treatment of primary and metastatic sacral lesions.

Because it is an 'intralesional' technique, cryosurgery is not an applicable adjuvant procedure for the treatment of high-grade primary bone tumors. The



treatment of choice for such tumors is wide resection. In the rare case where wide resection is not applicable, cryosurgery may be used as an adjuvant technique in association with intralesional resection and radiotherapy.<sup>22</sup> This was the approach chosen for Patient 7, who had Ewing sarcoma, a tumor that classically should be treated by wide resection and presurgery and postsurgery radiotherapy. Due to the young age of this patient, we chose to limit the destructive surgical field and preserve the complex regional architecture by using cryosurgery only at the sacral site and radiotherapy. The pelvic tumor, however, was resected, as is usually done in these cases. It is noteworthy that although cryosurgery causes ischemia and hypoxia, radiotherapy still was applicable in this patient. This is because the tumor, which occupied the posterior iliac bone and the sacrum, was resected but the radiotherapy was directed to the tumoral bed in the posterior ileum, a bone that was not treated by cryosurgery. Finally, although schwannomas are indolent and have smooth pushing borders that do not infiltrate bone, we found that the tumor had invaded and destroyed the bone in Patient 13. Therefore, we chose to use adjuvant cryosurgery as well.

In conclusion, cryosurgery for selected sacral tumors is a conservative, feasible, safe, and technically simple adjuvant in the treatment of sacral tumors. The risk of permanent neurologic deficits and damage to vessels or intrapelvic organs is much lower compared with the mutilating sacrectomy procedure. Large-scale studies are needed to confirm the adjuvant role of cryosurgery as a promising and safe procedure with an optimal oncologic outcome, preservation of organ functions and reflexes, as well as satisfactory aesthetic results.

## REFERENCES

- Llauger J, Palmer J, Amores S, Bague S, Camins A. Primary tumors of the sacrum: diagnostic imaging. *Am J Roentgenol*. 2000;174:417-424.
- Marcove RC, Sheth DS, Brien EW, Huvos AG, Healey JH. Conservative surgery for giant cell tumors of the sacrum. The role of cryosurgery as a supplement to curettage and partial excision. *Cancer*. 1994;74:1253-1260.
- de Vries J, Oldhoff J, Hadders HN. Cryosurgical treatment of sacrococcygeal chordoma. Report of four cases. *Cancer*. 1986;58:2348-2354.
- Wuisman P, Lieshout O, Sugihara S, van Dijk M. Total sacrectomy and reconstruction: oncologic and functional outcome. *Clin Orthop*. 2000;381:192-203.
- Kollender Y, Bickels J, Price WM, et al. Metastatic renal cell carcinoma of bone: indications and technique of surgical intervention. *J Urol*. 2000;164:1505-1508.
- Marcove RC, Miller TR. The treatment of primary and metastatic localized bone tumors by cryosurgery. *Surg Clin North Am*. 1969;49:421-430.
- Bickels J, Meller I, Malawer M. The biology and role of cryosurgery in the treatment of bone tumors. In: Malawer MM, Sugarbaker TH, eds. *Musculoskeletal cancer surgery. Treatment of sarcomas and allied diseases*. Dordrecht, The Netherlands: Kluwer Academic Publishers, 2001:135-145.
- Gage AA, Baust JG. Cryosurgery—a review of recent advances and current issues. *Cryoletters*. 2002;23:67-78.
- Malawer MM, Bickels J, Meller I, Buch RG, Henshaw RM, Kollender Y. Cryosurgery in the treatment of giant cell tumor. A long-term follow-up study. *Clin Orthop*. 1999;359:176-188.
- Marcove RC. A 17-year review of cryosurgery in the treatment of bone tumors. *Clin Orthop*. 1982;163:231-234.
- Marcove RC, Weis LD, Vaghaiwalla MR, Pearson R, Huvos AG. Cryosurgery in the treatment of giant cell tumors of bone. A report of 52 consecutive cases. *Cancer*. 1978;41:957-969.
- de Leon-Casasola OA, Parker B, Lema MJ, Harrison P, Massey J. Postoperative epidural bupivacaine-morphine therapy. Experience with 4,227 surgical cancer patients. *Anesthesiology*. 1994;81:368-375.
- Gottschalk A, Smith DS, Jobes DR, et al. Preemptive epidural analgesia and recovery from radical prostatectomy: a randomized controlled trial. *JAMA*. 1998;279:1076-1082.
- Meller I, Nirkin A, Kollender Y. The CRYO-HIT system: a new device for cryosurgery of bones: characteristics, technique and advantages by a series of the first 20 cases [abstract]. Proceedings of the 10th International Symposium of Limb Salvage, Cairns, Australia, April 11-14, 1999:60a.
- Bickels J, Witting JC, Kollender Y, Malawer MM, Meller I. Cryosurgical ablation of bone tumors with argon probes [abstract]. Proceedings of the 11th International Symposium of Limb Salvage, Birmingham, October 10-12, UK, 2001:123a.
- Gage AA, Greene GW Jr., Neiders ME, Emmings FG. Freezing bone without excision. An experimental study of bone-cell destruction and manner of regrowth in dogs. *JAMA*. 1966;196:770-774.
- Malawer MM, Marks MR, McChesney D, Piasio M, Gunther SF, Schmookler BM. The effect of cryosurgery and polymethylmethacrylate in dogs with experimental bone defects comparable to tumor defects. *Clin Orthop*. 1988;226:299-310.
- Oren R, Zagury A, Katzir O, Kollender Y, Meller I. Principles of rehabilitation after limb-sparing surgery for cancer. In: Malawer MM, Sugarbaker TH, eds. *Musculoskeletal cancer surgery. Treatment of sarcomas and allied diseases*. Dordrecht, The Netherlands: Kluwer Academic Publishers, 2001:583-593.
- Gage AA. History of cryosurgery. *Semin Surg Oncol*. 1998;14:99-109.
- Mazur P. Cryobiology: the freezing of biological systems. *Science*. 1970;168:939-949.
- Xu W, Song XW. Primary bone tumors of sacrum: surgical treatment of two hundred patients [abstract]. Proceedings of the 10th International Symposium of Limb Salvage, Cairns, Australia, April 11-14, 1999:53a.
- Marcove RC, Abou Zahr K, Huvos AG, Ogihara W. Cryosurgery in osteogenic sarcoma: report of three cases. *Compr Ther*. 1984;10:52-60.