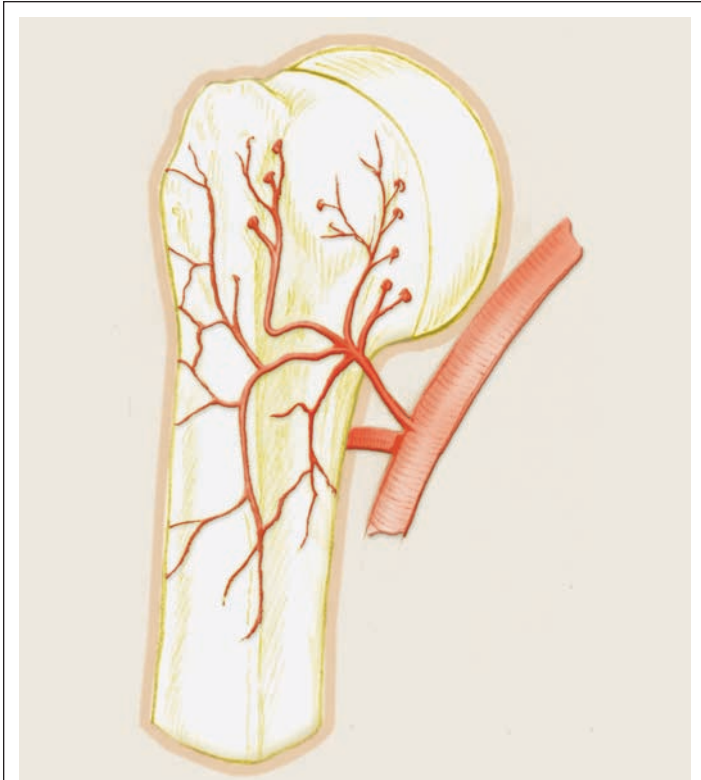
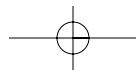
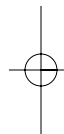
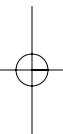


Neoplasia and Infection

VIII





Tumors of the Shoulder Girdle

37

Martin M. Malawer James C. Wittig Kristen Kellar Graney

INTRODUCTION 1158

Three Phases of Surgical Resection 1158

CLASSIFICATION OF SHOULDER-GIRDLE RESECTIONS 1158

TUMOR GROWTH AND ANATOMY 1158

INTRA- VERSUS EXTRAARTICULAR TUMOR EXTENSION 1160

CLINICAL EVALUATION 1160

History and Physical Examination 1160

Specialist Referral 1161

Unique Anatomic and Surgical Considerations 1161

PREOPERATIVE EVALUATION AND IMAGING STUDIES 1162

Computed Tomography 1162

Magnetic Resonance Imaging 1162

Bone Scan 1162

Angiography 1163

Venography 1164

Biopsy 1164

INDICATIONS AND CONTRAINDICATIONS FOR SHOULDER-GIRDLE RESECTION 1165

Utilitarian Shoulder-Girdle Incision 1166

PAIN CONTROL 1166

REHABILITATION AFTER SHOULDER-GIRDLE RESECTION 1167

TUMORS OF THE PROXIMAL HUMERUS 1168

Specific Tumors of the Proximal Humerus 1168

CRYOSURGERY 1174

TECHNIQUE OF TYPE I RESECTION AND RECONSTRUCTION 1175

TECHNIQUE OF EXTRAARTICULAR PROXIMAL HUMERAL RESECTION AND PROSTHETIC RECONSTRUCTION (TYPE VB) 1176

Resection 1176

Proximal Humerus Prostheses 1180

TECHNIQUE OF RECONSTRUCTION WITH MODULAR SEGMENTAL PROSTHESIS (MRS) 1180

TECHNIQUE OF TOTAL HUMERAL RESECTION 1182

Resection 1182

TECHNIQUE OF RECONSTRUCTION WITH TOTAL HUMERAL ENDOPROTHETIC REPLACEMENT 1183

Rehabilitation 1185

TUMORS OF THE SCAPULA AND PERISCAPULAR AREA 1185

Clinical Characteristics 1185

Specific Tumors of the Scapula 1185

TECHNIQUE OF TIKHOFF-LINBERG (TYPE IVB) RESECTIONS 1186

1158 **Part VIII: Neoplasia and Infection****TECHNIQUE OF TOTAL SCAPULECTOMY 1187****TECHNIQUE OF PARTIAL SCAPULECTOMY 1190****TECHNIQUE OF SCAPULA ENDOPROSTHETIC RECONSTRUCTION 1191**

Types of Prostheses 1191

Technique of Constrained Total Scapula

Endoprosthesis Reconstruction 1191

AXILLARY TUMORS 1192

Overview 1192

Unique Anatomic Considerations 1192

Radiographic Evaluation 1194

Biopsy 1194

Surgical Management 1194

CLAVICLE TUMORS 1195**AMPUTATION 1198****INTRODUCTION**

Each bone of the shoulder girdle—the proximal humerus, the scapula, and the clavicle—can give rise to a primary bone tumor or be involved by an adjacent soft tissue sarcoma.¹ The proximal (upper) humerus is one of the most common sites for high-grade malignant bony tumors in both adults and children, and it is the third most common site for osteosarcomas. Chondrosarcomas also commonly involve the shoulder girdle, often arising from the scapula or the proximal humerus. The bones of the shoulder girdle may also be involved secondarily by high-grade soft tissue sarcomas or metastatic tumors that often require resections similar to those used in the treatment of high-grade primary bony sarcomas. Metastatic tumors often involve the shoulder girdle, and because of the extent of bony destruction and the presence of large extraosseous components, the treatment is sometimes similar to that for primary malignant bony sarcomas. For example, hypernephromas (renal cell carcinomas) have a unique propensity to involve the proximal humerus, often as a solitary metastasis. They commonly result in extensive bony destruction with a large soft tissue component.

Three Phases of Surgical Resection

The surgical treatment of a malignant bony tumor involving the shoulder girdle consists of three stages: (a) wide surgical resection of the tumor, (b) reconstruction of the skeletal defect, and (c) multiple muscle transfers to provide soft tissue coverage, stabilize the shoulder girdle, and restore function to the upper extremity.

The aim is to provide a stable shoulder and preserve a functional elbow and hand. Each of the various surgical

techniques currently in use for reconstruction of a segmental defect of the humerus or shoulder girdle offer some degree of stability, function, durability, range of motion, and preservation of motor power.

CLASSIFICATION OF SHOULDER-GIRDLE RESECTIONS

Malawer et al. have developed a six-stage surgical classification system.³ This system is based on current concepts of surgical margins, the relationship of the tumor to anatomic compartments (i.e., intracompartmental vs. extracompartmental), the status of the glenohumeral joint (intraarticular vs. extraarticular), the magnitude of the individual surgical procedures, and the presence or absence of the abductor mechanism (deltoid muscle, rotator cuff muscle, or both).

The six-stage classification is as follows (Fig. 37-1):

Type I: Intraarticular proximal humeral resection

Type II: Partial scapular resection

Type III: Intraarticular total scapulectomy

Type IV: Intraarticular total scapulectomy and humeral head resection

Type V: Extraarticular humeral and glenoid resection

Type VI: Extraarticular humeral and total scapular resection

Each of the six types is further modified according to a major variable: the presence or absence of the main motor group, the abductor mechanism (i.e., deltoid and rotator cuff muscles). The abductors are either present (subtype A) or partially or completely resected (subtype B). The abductor mechanism is almost always resected when there is extraosseous extension of a bone tumor in this area. The loss of any component of the abductor mechanism tends to create a similar functional disability. Regardless of histology or primary bone involvement, subtype A generally entails an intracompartmental resection, and subtype B an extracompartmental resection (Table 37-1).

TUMOR GROWTH AND ANATOMY

Sarcomas, which arise from mesenchymal tissues (mesodermal embryonic layer), grow in a centripetal manner and form ball-like masses and compress surrounding muscle into a pseudocapsule layer. Sarcomas typically respect fascial borders and generally grow along the path of least resistance. This growth pattern is in contrast to that of carcinomas, which are invasive and usually penetrate compartmental borders. The pseudocapsule layer contains microscopic, finger-like projections of tumor referred to as satellite nodules. Sarcomas spread locally along the path of least resistance. Surrounding fascial layers resist tumor penetration and provide boundaries to local sarcoma growth. These boundaries

SURGICAL CLASSIFICATION OF SHOULDER-GIRDLE RESECTIONS

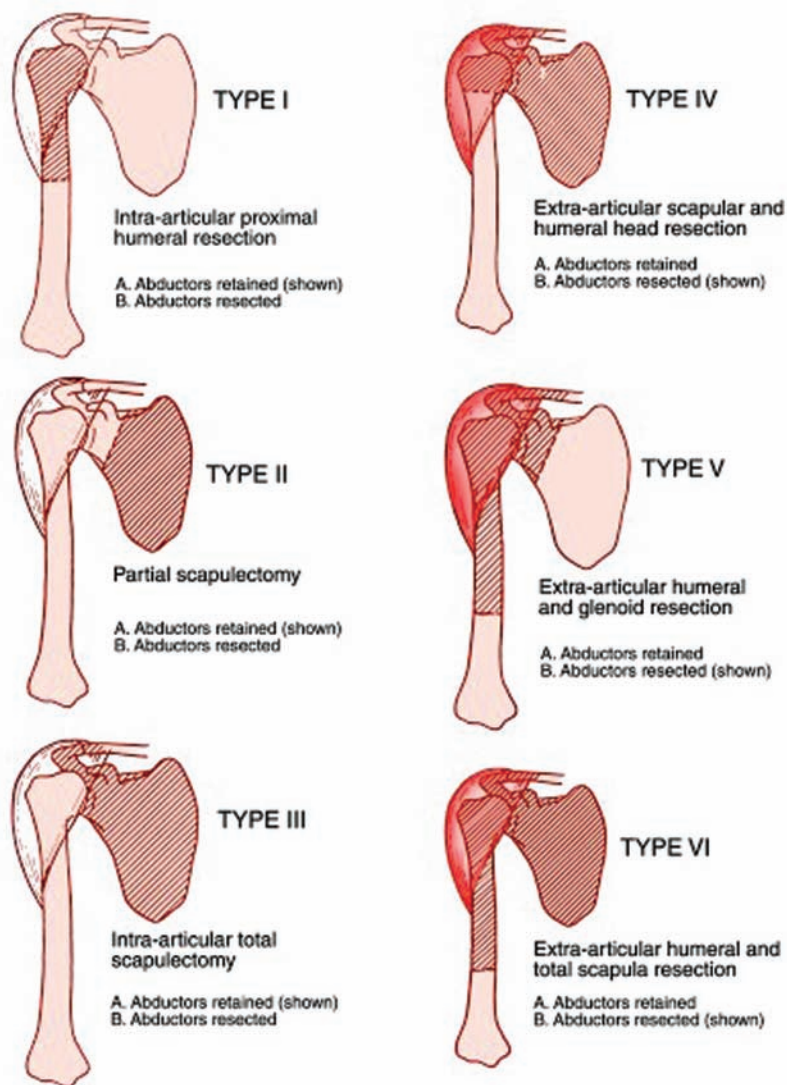


Figure 37-1 Surgical classification of shoulder girdle resections. Shoulder girdle resections are classified as type I to type VI. In general, types I to III are performed for benign or low-grade tumors of the shoulder girdle, whereas types IV to VI are performed for high-grade malignant tumors. In the schematic key, A = abductor muscles retained, whereas B = abductor muscles resected. The main abductors of the shoulder girdle include the rotator cuff musculature and the deltoid muscle. In general, these muscles are resected with high-grade tumors but are retained with low-grade tumors. (From Malawer MM, Meller I, Dunham WK. A new surgical classification system for shoulder-girdle resections. Analysis of 38 patients. *Clin Orthop* 1991;(267):33-44.)

form a compartment around the tumor. A sarcoma will grow to fill the compartment in which it arises; only rarely does a sarcoma extend beyond its compartmental boundaries. With reference to bony sarcomas that extend beyond the cortices into the surrounding soft tissues, the term "functional anatomic compartment" refers to the investing muscles that are compressed into a pseudocapsular layer. These muscles provide the fascial borders of the compartment, which has important surgical implications. A wide resection (i.e., compartmental resection) of a bone sarcoma entails removal of the entire tumor and pseudocapsular layer and must therefore encompass the investing normal muscle layers.

The functional compartment surrounding the proximal humerus consists of the deltoid, subscapularis, and remaining rotator cuff musculature, latissimus dorsi, brachialis, and portions of the triceps.

High-grade sarcomas that extend beyond the bony cortices of the proximal humerus involve and compress the investing muscles that form the compartmental borders and pseudocapsular layer. They grow along the path of least resistance and therefore are directed toward the glenoid and scapular neck by the rotator cuff and the glenohumeral joint capsule. Anteriorly, the tumor is covered by the subscapularis, which bulges into and displaces the neurovascular bundle (axillary vessels and brachial plexus). Only rarely does a proximal humerus sarcoma extend beyond the compartmental borders. In these instances, the tumor usually protrudes through the rotator interval. A wide resection for a high-grade sarcoma must therefore include the surrounding muscles that form the pseudocapsular layer, the axillary nerve, the humeral circumflex vessels, and the glenoid (extraarticular resection).

TABLE 37-1**TYPE OF RESECTION, TYPE OF RECONSTRUCTION, AND FUNCTIONAL OUTCOMES OF 134 TUMORS TREATED BY A LIMB-SPARING RESECTION OF THE SHOULDER GIRDLE**

Resection Type	n	Proximal Humerus Prosthesis	Scapular Prosthesis	Humeral Head Suspension	Function			
					Excellent	Good	Moderate	Poor
IA	29	29			20	5	4	
IB	7	7			3	3	1	
IIA	5				4	1		
IIB	12				8	4		
IIIA	1			1		1		
IIIB	15		3	12	6	3	4	2
IVA	0							
IVB	8	4	4		4	2	1	1
VA	1					1		
VB	53	53			4	31	11	7
VIA	0							
VIB	3		2			1	2	
Total	134	92	9	13	49	52	23	10

From Bickels J, Wittig JC, Kollender Y, Kellar-Graney K, Meller I, Malawer MM, Limb-sparing resections of the shoulder girdle. *J Am Coll Surg* 2002;194(4):422-435.

Most high-grade scapular sarcomas arise from the region of the scapular neck and body. The compartment consists of all of the muscles that originate on the anterior and posterior surfaces of the scapula. Although not one of the compartmental borders, the deltoid, which attaches to a narrow region of the scapular spine and acromion, may be involved secondarily by a large soft tissue extension. In most cases, the deltoid is protected by the rotator cuff muscles. Because the anatomic origin of most tumors is in the neck, the rotator cuff muscles are compressed into a pseudocapsular layer by sarcomas that arise from the scapula. The subscapularis also protects the neurovascular bundle from tumor involvement. The head of the proximal humerus is contained within the compartment surrounding the scapula. The tumor follows the path of least resistance and typically crosses the glenohumeral joint, grossly or microscopically, to involve the humeral head. Direct tumor extension through joints or articular cartilage is rare and typically occurs as the result of a pathologic fracture. Because of the small size of the glenohumeral joint, the tumor almost always involves the capsule or the synovium. The long head of the biceps tendon, which is intraarticular, is another pathway by which the tumor may cross the joint. Wide resection of a high-grade scapula sarcoma must therefore include the rotator cuff and, in most instances, the humeral head.

INTRA- VERSUS EXTRAARTICULAR TUMOR EXTENSION

The shoulder joint appears to be more prone than other joints to intraarticular or pericapsular involvement by

high-grade bone sarcomas. Figs. 37-2 and 37-3 show the mechanisms of tumor spread. Direct capsular extension, direct tumor tracking along the long head of the biceps, a poorly planned biopsy, and pathologic fracture are mechanisms of glenohumeral contamination and make intraarticular resection for high-grade sarcomas a higher risk than extraarticular resection for local recurrence. A local recurrence in this region often requires a forequarter amputation and may compromise patient survival. (This is in contrast to most clinical experience with resections of the distal femur, which tend to be intraarticular.) Therefore, extraarticular resection is recommended for most high-grade sarcomas of the proximal humerus and scapula.

CLINICAL EVALUATION

History and Physical Examination

Patients with bone sarcomas typically present to their primary care physician with complaints of a dull, aching pain of several months' duration. They often seek medical intervention because the pain has become more severe. This increased pain can be correlated with tumor penetration of cortical bone, irritation of the periosteum, or pathologic fracture. Severe night pain in the affected extremity is common. Some patients may describe regional tenderness, difficulty in moving the arm, or a palpable swelling or mass. Physical examination of the extremity usually confirms the presence of a mass or regional swelling and deformity. Children are especially susceptible to referred pain; for this reason, all regional joints should be examined.

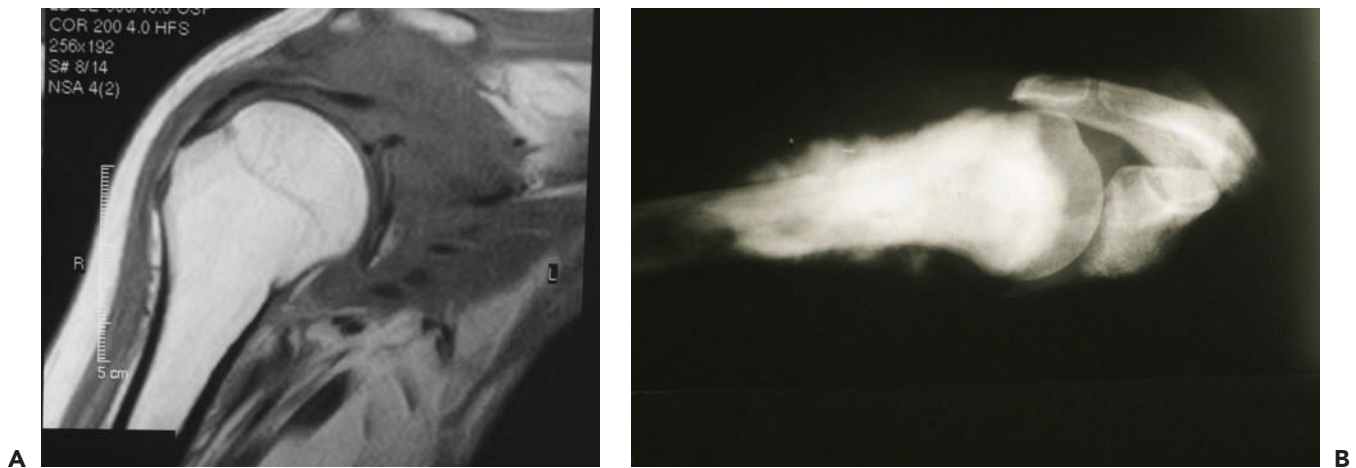


Figure 37-2 (A) Magnetic resonance imaging (MRI) scan showing gross tumor involvement within the joint (T1-weighted MRI image). (B) Radiograph of an extraarticular resection of the proximal humerus for osteosarcoma. Note that the proximal humerus, glenoid, and distal one-third of the clavicle have been resected en bloc. This procedure is classified as a type VA resection (Malawer classification). Extraarticular resection is often required for high-grade sarcomas of the proximal humerus.

The presenting symptoms for a soft tissue sarcoma are different and nonspecific. Typically, the mass presents as a slow-growing, painless lesion. Tumors arising in the upper extremity are more palpable and identified earlier than those in the lower extremity.

Specialist Referral

All patients with suspected malignancies should be referred to an orthopedic oncologist or a cancer center. A multidisciplinary team approach for patients with malignant tumors is essential to providing the best possible clinical outcome. Patients with aggressive benign tumors (i.e.,

giant cell tumor, chondroblastoma, or enchondroma) should also be referred.

Unique Anatomic and Surgical Considerations

The local anatomy of a sarcoma determines the extent of the operative procedure required. The following discussion addresses unique considerations of shoulder girdle anatomy that are relevant to surgery in this area.

- The glenohumeral joint generally does not serve as an effective barrier to tumor spread. A lesion may cross the joint by direct extension or indirect mechanisms, as

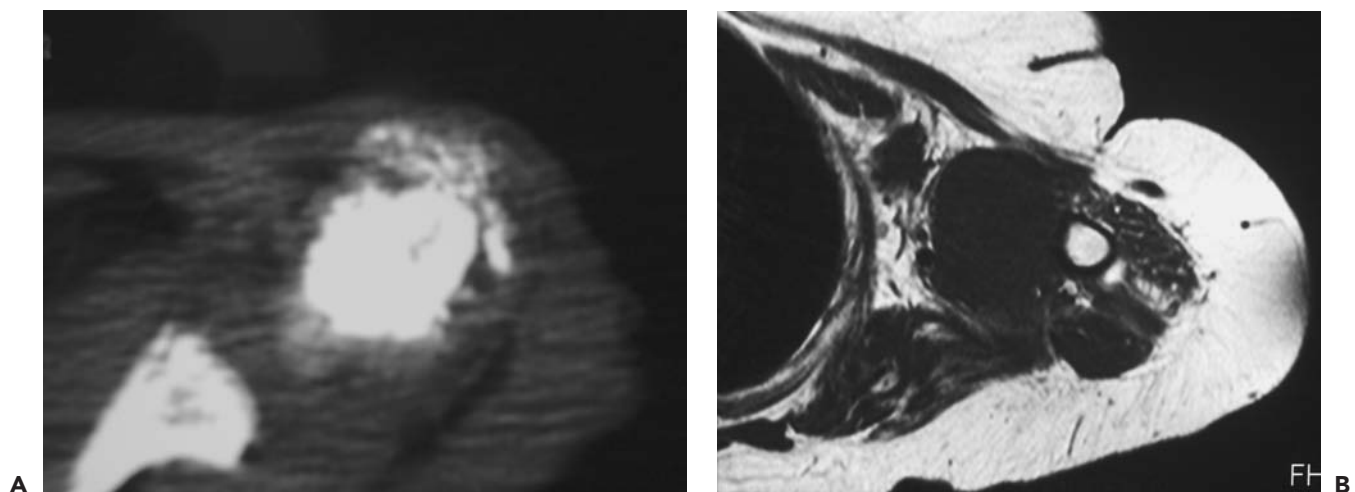


Figure 37-3 (A) Computed tomography scan of the glenohumeral joint showing destruction of the glenohumeral joint by tumor. The typical mechanism of intraarticular involvement by tumor is via direct extension and by capsular involvement. (B) Magnetic resonance imaging (MRI) scan demonstrating large tumor component adjacent to the proximal humerus with an adjacent skip nodule or enlarged axillary lymph node. MRI scans of the shoulder girdle are essential in evaluation of neoplastic lesions.

shown (Figs. 37-2 and 37-3). It is often necessary to perform an extraarticular resection for high-grade bone sarcomas of the proximal humerus or the scapula (glenoid region).

- The three major cords of the brachial plexus are in close proximity to the subscapularis muscle, glenohumeral joint, and proximal humerus. Tumors involving the upper scapula, the clavicle, and the proximal humerus often displace the infraclavicular component of the brachial plexus. It may be necessary to sacrifice some of the major nerves if they are encased by neoplasm, or a forequarter amputation may be required.
- The musculocutaneous and axillary nerves are often in contact with or in close apposition to tumors around the proximal humerus, and before proceeding with resection it is necessary to clearly identify both. It is crucial to preserve the musculocutaneous nerve to preserve a functional elbow. The musculocutaneous nerve generally comes from beneath the coracoid and passes through the conjoined tendon or coracobrachialis muscle within a few centimeters of its origin. The position of this nerve does vary, however, and it may lie within 2 to 8 cm of the coracoid. It then passes through the short head of the biceps and into the long head of the biceps before innervating the brachialis muscle.
- The axillary nerve is closest to most large tumors of the proximal humerus. It arises from the posterior cord and, along with the circumflex vessels, courses around the subscapularis muscle and the head and neck of the humerus to innervate the deltoid posteriorly. In patients who have large malignant tumors of the proximal humerus, the axillary nerve usually must be resected because of tumor proximity or involvement, and because it is necessary to remove the deltoid muscle and glenoid to provide a satisfactory margin. With large stage IIB bone sarcomas of the proximal humerus, the axillary nerve and deltoid muscles can rarely be preserved. In contrast, the axillary nerve is usually not involved by scapular tumors and therefore can be preserved along with the deltoid muscle. This allows for functional anatomic reconstruction of the scapula with a prosthetic replacement.
- The brachial artery is surrounded by the three major cords of the brachial plexus and is tethered to the proximal humerus by the anterior and posterior circumflex vessels. A presurgical angiogram is extremely useful to localize the brachial artery and identify the level of the circumflex vessels. Occasionally, one finds anomalous brachial and axillary arteries that would be difficult to identify and explore if not recognized preoperatively. In general, the circumflex vessels are ligated during the initial dissection; this allows the entire axillary artery and the vein and brachial plexus to fall away from the tumor mass. Early ligation of the circumflex vessels is key to the resection of proximal humeral sarcomas.
- The radial nerve courses along the posterior aspect of the axillary sheath and exits from the posterior cord at the inferior border of the latissimus dorsi muscle. Fortunately, most sarcomas are located in the proximal third of the humerus and do not involve this nerve. However, to avoid injury the radial nerve must be isolated and protected prior to tumor resection. Sacrifice of the radial nerve is rarely necessary.

PREOPERATIVE EVALUATION AND IMAGING STUDIES

Appropriate imaging studies are crucial to successful resection of tumors of the shoulder girdle (Fig. 37-4). The most useful preoperative evaluations are computed tomography (CT), magnetic resonance imaging (MRI), arteriography, and three-phase bone scans. For large tumors of the proximal humerus, a venogram may be warranted if there is clinical evidence of distal obstruction.

Computed Tomography

CT is more useful than MRI in determining cortical bone changes, and it is considered complementary to MRI in evaluating the chest wall, clavicle, and axilla. CT is useful for determining the planes of tumor resection. Subtle cortical erosions by adjacent soft tissue sarcomas are better visualized on CT than on MRI. The amount of tumor necrosis can be determined. Often, a reactive rim of calcification can be visualized surrounding tumors that have had a good response to preoperative chemotherapy.

Magnetic Resonance Imaging

MRI is used to determine the extent of soft tissue involvement, especially around the glenohumeral joint, along the chest wall, and into the axillary space. It is often difficult to visualize the suprascapular area in patients with large tumors, which may infiltrate below the subscapularis muscle and exit near the coracoid. MRI is especially useful in identifying the extent of intraosseous tumor, which is necessary to determine the length of the resection. Skip metastases can also be identified, although they rarely occur in this area. MRI is not useful for determining the preoperative tumor response to induction chemotherapy. MRI and bone scan studies accurately demonstrate the soft tissue extension as well as the intraosseous extent of the tumor.

Bone Scan

Bone scintigraphy is routinely used to assess the presence of metastatic and polyostotic bone disease as well as involvement of a bone by adjacent soft tissue sarcomas.

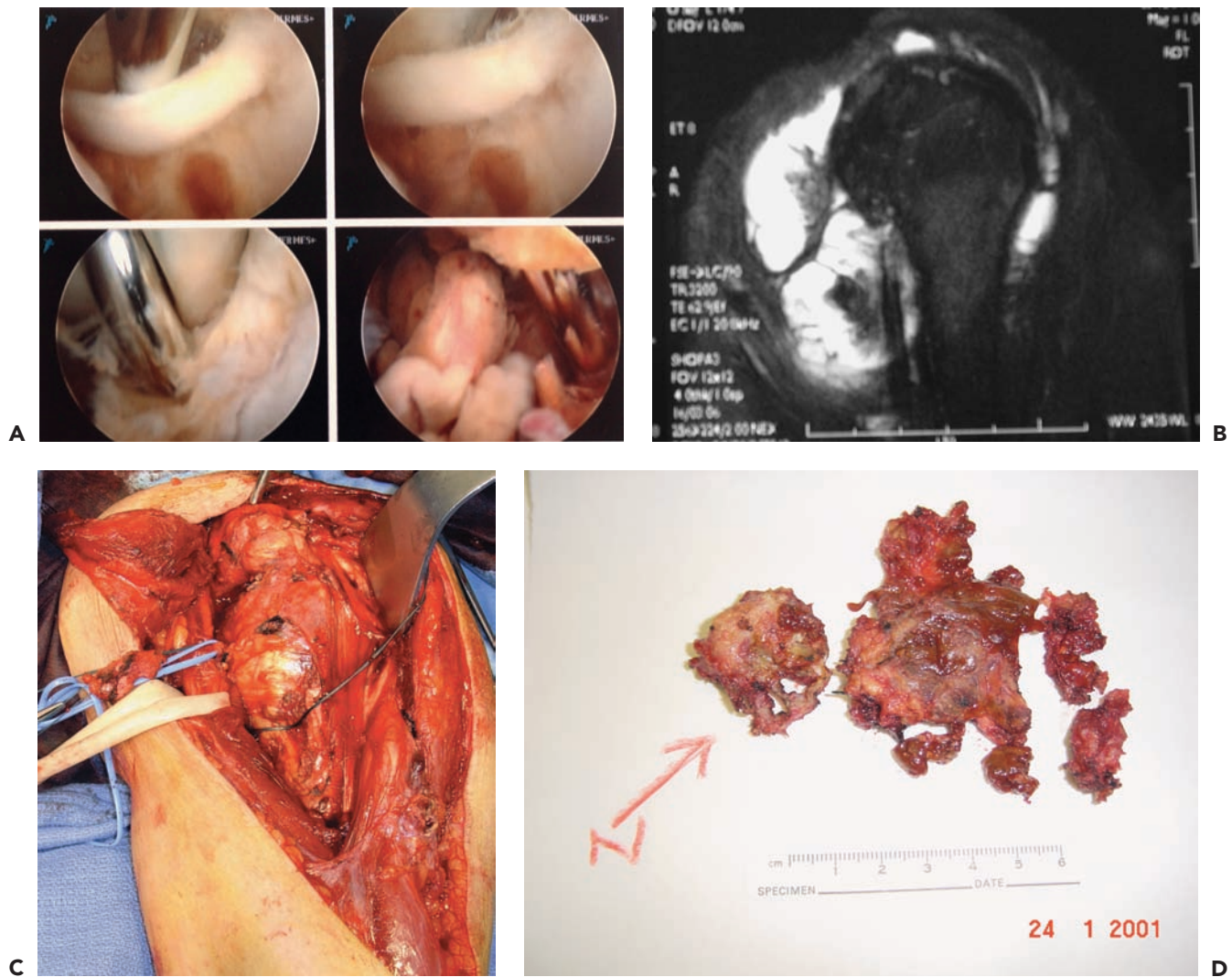


Figure 37-4 Pigmented villonodular synovitis (PVNS) or aggressive synovitis of the shoulder. **(A)** This photograph shows an arthroscopic view of the shoulder joint. Note the brownish pigmentation of the synovium. **(B)** Magnetic resonance imaging scan (T2-weighted fat suppressed) showing a marked distended joint with blood (white area) and bulky synovial disease. **(C)** Intraoperative photograph showing the proximal humerus following detachment of the pectoralis major muscle. Note the large soft tissue mass surrounding the proximal humerus. **(D)** Gross specimen following curettage and resection of tumor (PVNS). Note the brownish pigmentation, which is consistent with hemosiderin deposits and marked histiocytic proliferation.

The appearance of a bone lesion in the flow and pool phases, when assessed by a three-phase bone scan, is useful in determining the biologic activity of the tumor, which may be helpful in determining a diagnosis. Some surgeons utilize the bone scan following induction chemotherapy as an indirect measurement of evaluating tumor response.

Angiography

Angiography is extremely useful and should be done with the arm abducted to determine the relationship of the axillary and brachial vessels to the major tumor, the

level of the circumflex vessels, and the presence of any anomalies (Fig. 37-5). The axillary vessels and brachial plexus are often displaced by large tumors in this area. Angiography is also the most reliable means of determining the response to neoadjuvant chemotherapy. The absence of vessels in the tumor or a decrease in tumor vascularity indicates tumor necrosis. If there is a very good angiographic response (i.e., decrease in or absence of tumor blush), it is indicative of a good response to the preoperative chemotherapy. This information is important for determining the extent of surgical margins and also provides prognostic information. For instance, if the tumor has had a good response, it is safe to proceed with

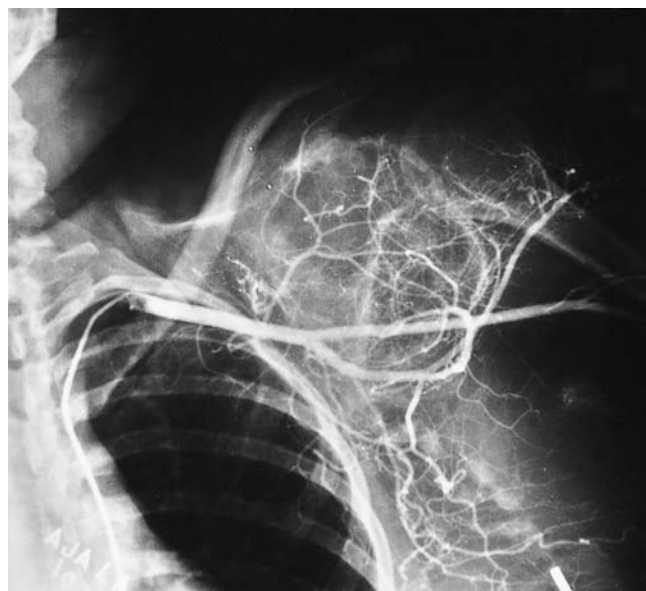

Figure 37-5 Angiogram of a large scapular sarcoma. Angiograms are essential for evaluation of bulky tumors of the shoulder girdle. This scan demonstrates the relationship of the artery to the tumor and the marked vascularity of most tumors. In general, prior to surgery, vascular tumors are embolized.

a limb-sparing resection. The margins may be narrower with less soft tissue resected. If the tumor has had a poor response, the surgeon may elect to take a wider soft tissue margin or perform an amputation. The venous flow phase is useful to demonstrate venous occlusion or

tumor thrombi. If there is any suggestion of occlusion, a brachial venogram should be performed (Fig. 37-6A).

Venography

If venous thrombosis or a mural thrombosis is expected, venography should be performed. The most suspicious finding is extremity edema. Axillary vein thrombosis or occlusion is most common with large shoulder osteosarcomas and chondrosarcomas. It is indicative of encasement of the vascular structures by neoplasm and therefore indirectly reflects brachial plexus involvement because of the intimacy of the brachial plexus and the axillary vessels. This finding suggests that the tumor is unresectable (Fig. 37-6B).

Biopsy

Because 95% of bone sarcomas have a soft tissue component, a small needle, or core, biopsy is possible (Figs. 37-7 and 37-8). One exception may be the young patient with a suspected round cell tumor from whom more tissue may be required for cytogenetic and immunohistochemical stains. Another exception would be an older patient in whom a solitary metastatic lesion is suspected and the pathology supports either metastatic carcinoma or a spindle cell sarcoma. This differentiation most often occurs with metastatic renal cell carcinoma. In such a case, a significant amount of tissue may be required to obtain

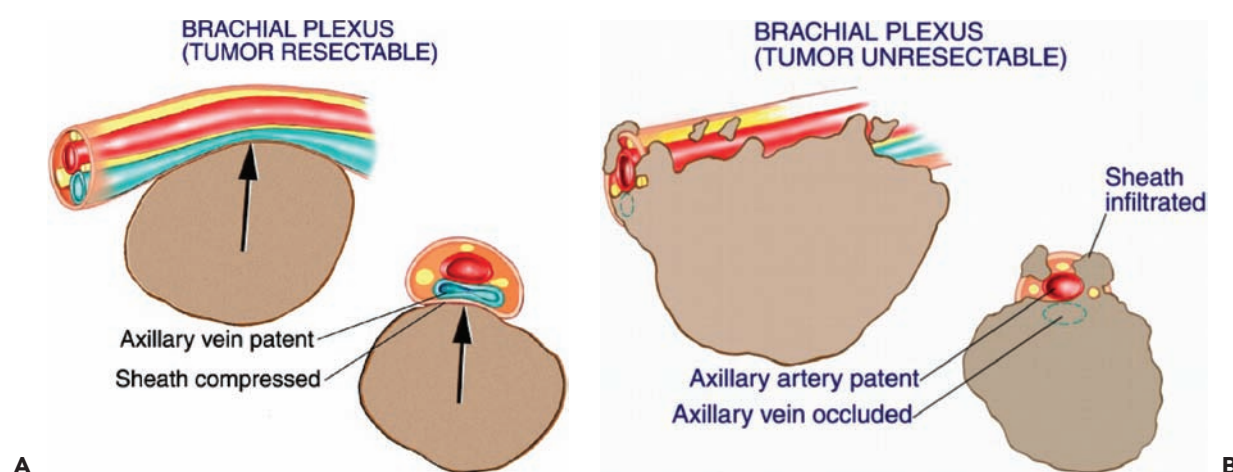


Figure 37-6 (A) Schematic diagram showing the relationship of the axillary vessels to tumors arising within the axillary space, either from the scapula, proximal humerus, or axillary space itself. The infraclavicular portion of the brachial plexus is often displaced by a tumor mass. The axillary artery and vein can be seen on angiography and axillary venography, respectively. These vessels are both patent but may be compressed. The clinical implication is that there is no nerve involvement and therefore these tumors are usually resectable. (B) Schematic diagram showing an unresectable tumor due to infiltration of the infraclavicular portion of the brachial plexus. An angiogram would still demonstrate a patent artery in this situation, but most importantly, the axillary vein would be occluded and thus the surrounding nerves are infiltrated. Axillary venography has proven to be very important in determining tumor resectability. (From Malawer M, Wittig JC. Resections of the shoulder girdle. In: Malawer MM, Sugarbaker PH, eds. *Musculoskeletal cancer surgery: treatment of sarcomas and allied diseases*. Dordrecht, Netherlands: Kluwer Academic Publishers, 2001:193.)

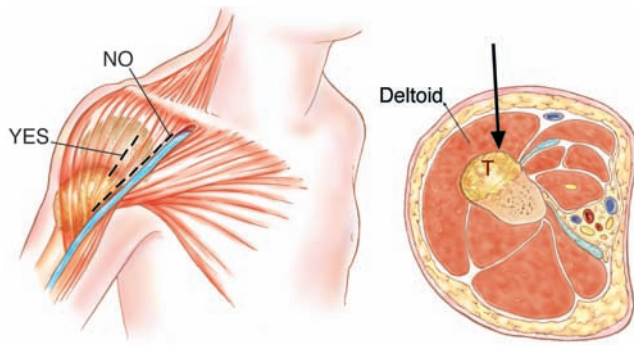


Figure 37-7 Schematic of the shoulder girdle and the preferred site of a needle or a small incisional biopsy for bony tumors. Biopsy should be performed through the anterior one-third of the deltoid to avoid contamination of the pectoralis major and therefore the brachial vessels underneath. A biopsy should never be performed through the deltopectoral interval. Approximately 95% of bony tumors can be correctly identified with multiple cores obtained through a single puncture site performed under computed tomography guidance. (From Malawer M, Wittig JC. Resections of the shoulder girdle. In: Malawer MM, Sugarbaker PH, eds. *Musculoskeletal cancer surgery: treatment of sarcomas and allied diseases*. Dordrecht, Netherlands: Kluwer Academic Publishers, 2001:194.)

immunohistochemical stains that will differentiate the metastatic tumor from a primary sarcoma.

Planning the Biopsy

It is essential to plan and perform the biopsy carefully, because an inappropriate biopsy is a common cause of fore-quarter amputation. In a patient with a tumor of the proximal humerus, a core biopsy through the anterior third of the deltoid muscle is recommended (see Fig. 37-8). Open biopsies are rarely required and may lead to excessive local contamination. If there is a soft tissue component, which occurs 95% of the time, there is no need to enter the bone. Several

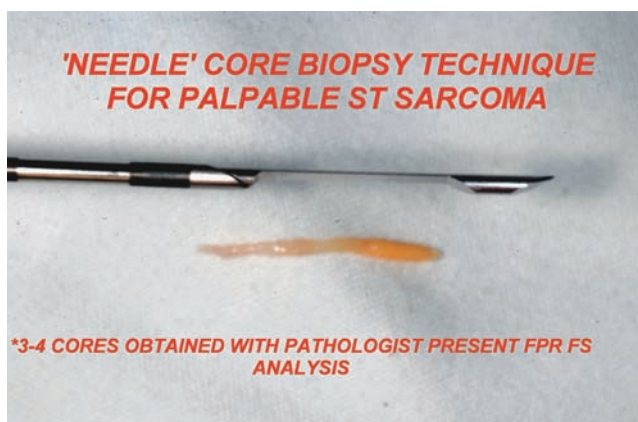

Figure 37-8 Core biopsy showing the needle and specimens that can be obtained. Approximately four or five cores are obtained from the tumor through the same puncture wound by changing the angle of the approach.

samples may be taken from different areas through a single puncture site. Care must be taken to avoid the deltopectoral groove. Contamination of this groove leads to contamination of the pectoralis muscle and, potentially, of the brachial vessels and axillary space (see Fig. 37-7).

Biopsy Technique

The biopsy site is a crucial factor in determining the final operative procedure. For tumors arising within the body of the scapula, a posterior needle biopsy or a biopsy along the axillary border of the scapula is recommended. With lesions involving the scapula and neck, a posterior approach directly through the teres minor is recommended. If an open biopsy is required, a small longitudinal incision in line with the incision that will be used for resection is recommended. Most operative approaches involve an incision along the axillary border of the scapula.

A biopsy of the proximal humerus should be performed through the anterior third of the deltoid, not through the deltopectoral interval. A biopsy through the anterior third of the deltoid results in a limited hematoma that is confined by the deltoid muscle and can be resected with the tumor en bloc (see Fig. 37-7). The axillary nerve innervates the deltoid muscle posteriorly, so the anterior portion of the muscle can be partially resected with minimal loss of function if the remaining deltoid is to be preserved. On the other hand, an open biopsy through the deltopectoral interval will contaminate the pectoralis major muscle and provide a plane for the hematoma to dissect to the chest wall along the brachial vessels. This makes a local resection more difficult and increases the possibility of local recurrence.

Clavicle tumors are biopsied along the length of the clavicle. Unless there is a soft tissue component, a small biopsy is advisable because a needle in this location could injure the brachial plexus and the neurovascular bundle.

Most shoulder-girdle soft tissue sarcomas are easily palpable. Multiple core needle biopsies performed through one puncture site under local anesthesia are recommended. If the mass is not palpable, core biopsies should be performed under fluoroscopic or CT guidance. To obtain multiple specimens from different areas, the surgeon should reintroduce the needle through the same puncture site, varying the angle. Cultures should be obtained routinely, regardless of the suspected diagnosis, because infection may simulate any malignancy. Touch-preps, frozen sections, or both confirm that lesional tissue has been obtained.

INDICATIONS AND CONTRAINDICATIONS FOR SHOULDER-GIRDLE RESECTION

Approximately 95% of high-grade shoulder-girdle malignancies can now be treated safely by limb-sparing surgeries;

1166 Part VIII: Neoplasia and Infection

forequarter amputation is now rare. The decision to proceed with limb-sparing surgery is based on the location of the cancer and a thorough understanding of its natural history.

Major contraindications for limb-sparing techniques are tumor involvement of either the neurovascular bundle or the chest wall. Relative contraindications include:

- pathologic fracture,
- extensive involvement of the shaft of the humerus,
- infection, and
- tumor contamination of the operative area from hematoma following biopsy or unwise placement of the biopsy incision.

These contraindications are described later in greater detail. General comments on contraindications are as follows:

- A pathologic fracture that has healed during the course of induction chemotherapy is not a contraindication to limb-sparing surgery. The arm is immobilized during this treatment period. With proper surgical treatment, the local recurrence rate is acceptably low and survival rates are not altered.
- The brachial artery is rarely involved by a tumor, although it may be in close proximity to it. The subscapularis, coracobrachialis, and short head of the biceps muscles often separate tumors of the proximal humerus and scapula from the vascular structures and brachial plexus. Occasionally, however, the brachial veins are directly invaded by a tumor and may be the site of tumor thrombi.
- Involvement of the musculocutaneous nerve by the tumor is rare, as is involvement of the three major cords to the brachial plexus, which follow the brachial vessels. The axillary nerve is often involved by tumors arising from the proximal humerus and is therefore resected. Direct tumor extension of the brachial plexus requires a forequarter amputation. Such extension into the plexus occurs most often with axillary or chest wall sarcomas, or metastatic carcinomas or melanoma to axillary lymph nodes.

If an inappropriate biopsy has contaminated the shoulder girdle, limb-preserving resection is often inadvisable. Today, one of the major causes for amputation of the shoulder girdle is inappropriate biopsy resulting in contamination of the pectoralis major, the chest wall, and the neurovascular structures.

- Infection is a contraindication to limb-preserving surgery. Even with adequate resection, reconstruction of an infected field by arthrodesis, prosthesis, or allograft replacement is extremely risky, considering that all patients with high-grade sarcomas must receive postoperative adjuvant chemotherapy. If an infection cannot be eradicated with the primary resection, amputation is advisable.

- Previous surgeries affect the feasibility of a limb-sparing procedure. The local recurrence rate is increased if a wide resection is attempted following a previous resection around the shoulder girdle.
- On rare occasions, tumors of the scapula or proximal humerus with large soft tissue components invade the chest wall and intermingle with the intercostal muscles and the ribs. This situation usually requires a resection of the adjacent chest wall, but it is not an absolute indication for forequarter amputation because limb-sparing resection may be combined with chest wall resection.
- In the rare instance of lymph node involvement documented by biopsy, a forequarter amputation may be the best way to remove all the axillary nodes as well as the proximal sarcoma. On the other hand, it is not unreasonable to proceed with a limb-sparing resection and an axillary node dissection. This method can provide long-term cure and local control.

Utilitarian Shoulder-Girdle Incision

The utilitarian shoulder-girdle incision was developed by the senior author (MM) to serve as a basic incision for use in all types of shoulder tumors and in all anatomic locations. This incision permits adequate exploration of the bony structures and soft tissues and complete exposure of the axillary vessels and infraclavicular brachial plexus. It consists of three components (Fig. 37-9):

1. Anteriorly, the incision begins at the junction of the medial and middle thirds of the clavicle. This incision extends medial to the coracoid, along the deltoid pectoral interval across the axillary fold, and courses distally along the anteromedial aspect of the arm.
2. The posterior incision begins over the midclavicular region of the anterior incision and travels inferiorly over the lateral aspect of the scapula and curves posteriorly at its tip. Large fasciocutaneous flaps are elevated anteriorly and posteriorly.
3. An incision into the axillary fold can be extended for proximal humerus tumors with axillary extension, for isolated axillary tumors, or for those rare instances when a limb-sparing resection cannot be performed and the procedure must be converted to a forequarter amputation.

PAIN CONTROL

A unique method developed for the postoperative management of pain in patients undergoing major tumor surgery is the use of perineural catheters. This technique involves the direct placement of a silastic (epidural type) catheter within the nerve sheath of the brachial plexus prior to

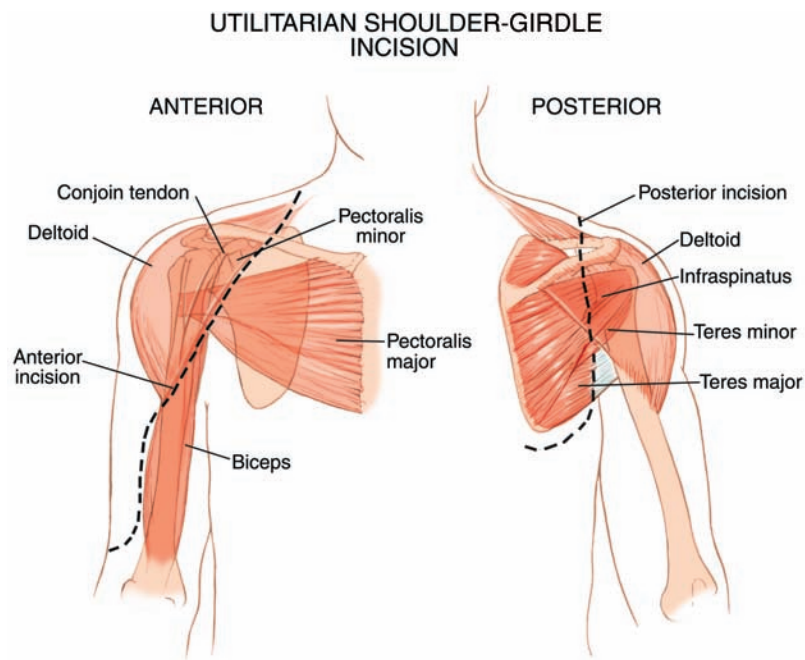


Figure 37-9 Utilitarian shoulder girdle incision. The utilitarian shoulder incision consists of three components: (1) A long deltopectoral incision from the midthird of the clavicle through the deltopectoral interval and distally along the medial aspect of the arm. (2) A curved incision along the axillary border of the scapula, which permits a large posterior fasciocutaneous flap to be developed to expose the scapula and the periscapular musculature. (3) An axillary incision that permits a forequarter amputation in conjunction with the first two incisions. (From Malawer M, Wittig JC. Resections of the shoulder girdle. In: Malawer MM, Sugarbaker PH, eds. *Musculoskeletal cancer surgery: treatment of sarcomas and allied diseases*. Dordrecht, Netherlands: Kluwer Academic Publishers, 2001:191.)

closure of the wound (Fig. 37-10). Twenty milliliters of 0.25% of Marcaine is perfused initially, and then a continuous infusion of 2 to 4 mL/hr of .025% for the immediate postoperative period is given. This technique reduces the postoperative narcotic requirements by about 90%.

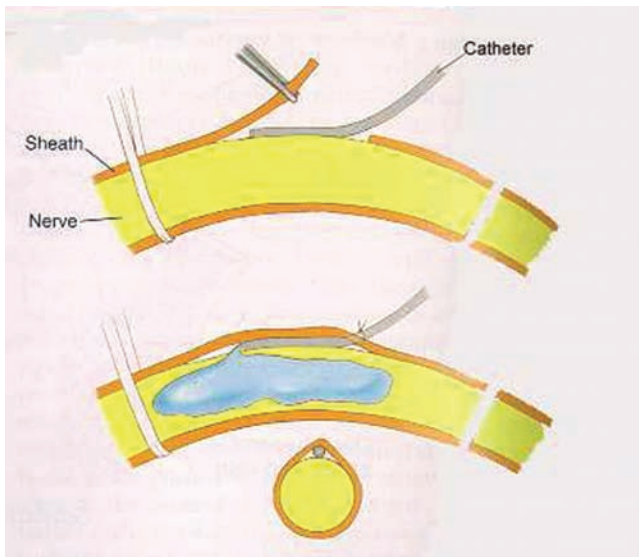


Figure 37-10 Schematic diagram of the perineural catheter utilized for perioperative pain control following most shoulder-girdle resections. At the time of surgery, a small Silastic catheter is placed in the nerve sheath of the brachial plexus. Twenty milliliters of 0.25% bupivacaine are bloused prior to wound closure, and then 4 to 8 mL/hr are infused over the next 48 to 72 hours. This provides excellent pain control for most shoulder-girdle procedures. (From Sugarbaker PH, Bickels J, Malawer M. Above-knee amputation. In: Malawer MM, Sugarbaker PH, eds. *Musculoskeletal cancer surgery: treatment of sarcomas and allied diseases*. Dordrecht, Netherlands: Kluwer Academic Publishers, 2001:360.)

REHABILITATION AFTER SHOULDER-GIRDLE RESECTION

From a rehabilitation perspective, the outcome of resection is clearly superior to that of a forequarter amputation or shoulder disarticulation. Patients undergoing shoulder-girdle resection retain hand function and good elbow function, but they lose some shoulder function, mainly abduction. Shoulder-girdle resection is less disfiguring than amputation and is associated with only minimal pain and edema. Generally, patients' acceptance of the outcome of their surgery is good to excellent.

Rehabilitation begins with an orientation program that often features pictures of patients who have undergone the procedure and demonstrations of what one can do postoperatively. Preoperatively, a shoulder mold is fashioned using the involved shoulder, provided its contours are not distorted. The cosmetic shoulder helps preserve the symmetry and appearance of the shoulder contour and can support a bra strap or heavy overcoat.

The patient uses a sling postoperatively, and motion is restricted until the incision is healed. The sutures are removed about 2 weeks after surgery. Edema is controlled with an elasticized glove or elastic stockinet. Active motion of the elbow and hand is initiated to preserve strength and range of motion and to help minimize edema.

If the incision heals per primam, assistive elbow motion is started within the confines of the sling as soon as the suction catheters have been removed. At about 2 weeks, the sling is removed for passive shoulder range of motion (ROM) and pronation and supination of the wrist. The patient should continue to use the sling intermittently after the incision is healed, primarily for upright activities

in which arm support increases comfort. Once the arm is out of the sling, full ROM of elbow (flexion, extension, pronation, and supination) is performed. Passive ROM to the shoulder (flexion, abduction, and external and internal rotation and pendulum exercise) with the help of a family member or physical therapist is recommended.

Rehabilitation depends on the type of reconstructive technique. In general, patients with endoprosthetic intraarticular allografts or composite allograft reconstruction undergo the same rehabilitation program. Those treated by arthrodesis, allograft, or autograft are immobilized for 4 to 5 weeks to allow early bony union to take place.

TUMORS OF THE PROXIMAL HUMERUS

Despite the complexity of these cases, limb-sparing surgery for both high- and low-grade sarcomas of the proximal humerus is possible in approximately 95% of cases. Forequarter amputation is indicated mainly for large, fungating tumors, tumors with secondary infections, cases in which there is chest wall involvement, and patients who have had a failed attempt at limb-sparing resection. Preoperative neoadjuvant chemotherapy may allow fracture healing if there is significant tumor necrosis.

Most low-grade sarcomas of the proximal humerus can be treated by type I excision with minimal functional deficit. High-grade sarcomas require a modified Tikhoff-Linberg resection (type V). Intraarticular and synovial involvement is more common with high-grade chondrosarcomas and with osteosarcomas of the shoulder girdle than with such tumors at other anatomic sites. Thus, extraarticular, rather than intraarticular, resections are recommended for high-grade tumors of the proximal humerus. Prosthesis, allograft, or allograft prosthetic composite can be used for reconstruction following a marginal resection (type I) for a low-grade lesion. Arthrodesis is rarely performed today. Following resection of a high-grade lesion (stage IIB), the aim is to provide a stable shoulder that will preserve function in the elbow and hand. Regardless of the type of reconstruction planned, the magnitude of the surgical resection depends on the grade of the tumor and its anatomic extent.

A major consideration in the preoperative evaluation and surgical planning is the intraosseous extension of the tumor within the bone marrow. The humerus is shorter than the femur and tibia, the two most common sites of sarcomas, and large tumors of the humerus often require resection of a significantly larger portion of the bone. It is not unusual to resect 50% to 80% of the humerus. Tumors arising within the diaphysis may require a total humeral resection and replacement of the glenohumeral and elbow joints. The surgeon must have various lengths and diameters of intramedullary stems at hand. The final decision about the extent of resection needed is made at the time of surgery.

The abductor mechanism (i.e., the deltoid muscle and the rotator cuff) normally covers the shoulder joint. These structures are usually resected in patients with high-grade proximal humeral sarcomas. Following the resection, joint coverage and stability are essential to eliminate dead space, decrease the risk of infection, and maintain good elbow and hand function. The key muscle transfers in the reconstruction are the pectoralis major, the biceps, and the latissimus dorsi; these must be identified and preserved during the resection.

Specific tumors of the Proximal Humerus (Table 37-2)

Benign Tumors

Giant Cell Tumor

Giant cell tumor (GCT) is a locally aggressive tumor with a low metastatic potential. It occurs slightly more often in females than in males. This tumor is thought to arise in the metaphyseal-epiphyseal junction, and large tumors may extend into the metaphysis or, more rarely, the diaphysis. The descriptor "benign" was first applied to GCT to differentiate it from other bony malignancies that required amputation. GCT is now considered a benign aggressive lesion, although 3% to 5% are primarily malignant or will undergo malignant transformation either after radiation therapy or following several local recurrences (Fig. 37-11).

GCTs are eccentric lytic lesions without matrix formation. They have well-defined borders and a sharp transition between the tumor and host bone. Periosteal elevation is rare unless accompanied by a pathologic fracture. The typical GCT comprises two basic cell types. The stroma consists of polygonal to somewhat spindle-shaped cells. Scattered diffusely through the stroma are benign osteoclast-like giant cells. Extensive hemorrhage, fracture, or previous surgery can alter the usual pathologic picture of GCT and make it resemble that of a primary bone sarcoma. Cystic areas with surrounding hemosiderin pigment and xanthoma cells correspond to the grossly observed cyst. Approximately 5% of all GCTs occur around the shoulder girdle.

Treatment of GCT is surgical removal (curettage) along with administration of an adjuvant cytotoxic agent such as phenol, zinc chloride, alcohol, hydrogen peroxide, or carbolic acid, or, as the authors prefer, curettage and application of a physical adjuvant such as cryosurgery. Treatment of GCT with curettage, burr drilling, and application of cryosurgery has achieved a local recurrence rate of less than 5% (see Cryosurgery section). Type I resection for GCTs is rarely necessary and is reserved for those tumors in which there is insufficient bone remaining for reconstruction with polymethylmethacrylate (cementation). We recommend the treatment of GCT of the proximal humerus with curettage and cryosurgery.

TABLE 37-2**HISTOGENESIS AND ANATOMIC SITE OF TUMORS IN 72 PATIENTS TREATED BY LIMB-SPARING SURGERY OF THE SHOULDER GIRDLE**

Type of Tumor	Scapula	P. Humerus	Total
Chondrosarcoma	4	13	17
Osteosarcoma	4	24	28
Ewing's sarcoma	1	1	2
Giant cell tumor	1	0	1
Osteochondroma	2	0	2
Fibrosarcoma	2	0	2
Fibromatosis	3	0	3
Hemangiopericytoma	2	0	2
Synovial sarcoma	0	1	1
Leiomyosarcoma	0	1	1
Malignant fibrous histiocytoma	1	3	4
Hypernephroma	1	3	4
Hemangiosarcoma	0	1	1
Pleomorphic sarcoma	1	1	2
Paget's sarcoma	0	1	1
Osteoblastoma	0	1	1
TOTAL	22	50	72

Presented at Surgical Grand Rounds at Georgetown University Medical Center May 2001. Washington DC (not published)

Chondroblastoma (Codman's Tumor)

Chondroblastoma is a benign aggressive tumor that shows a marked predilection for the epiphysis of the bone. This tumor was originally described by Codman as occurring in the proximal humeral epiphysis (thus named Codman's tumor). It is composed of round and spindle cells, some of which resemble immature chondrocytes or chondroblasts, hence the name *chondroblastoma*. Chondroblastomas account for less than 1% of all bone tumors.

They are one-fifth as common as GCTs. Most patients are skeletally immature when this tumor occurs: 95% of patients are between 5 and 25 years of age, and most of these tumors occur in teenagers. If a chondroblastoma occurs after skeletal maturity, one must be very suspicious of a clear cell chondrosarcoma. Males are affected twice as often as females. Patients usually present with mild pain that may have been present for several months. About one-third of patients have a joint effusion or fluid

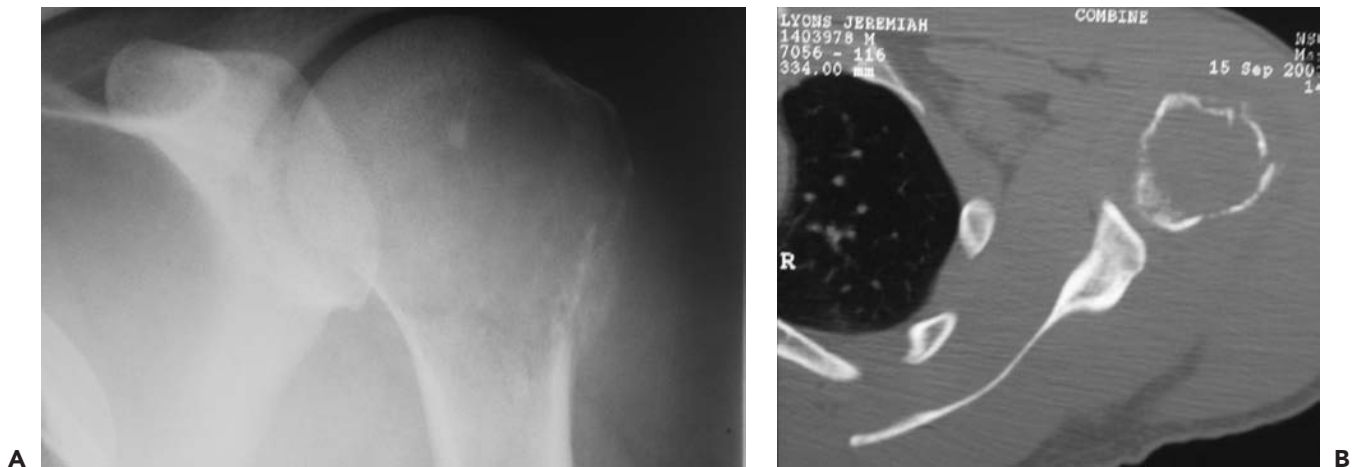


Figure 37-11 Giant cell tumor of the proximal humerus. **(A)** Plain radiograph demonstrating a lytic lesion of the proximal humerus with poorly defined borders and with cortical destruction. There is no matrix formation. **(B)** Computed tomography scan showing marked cortical thinning and destruction. Needle biopsy showed a giant cell tumor. Giant cell tumors of the proximal humerus are very rare and represent less than 1% to 2% of all giant cell tumors.

in the joint, and swelling and limitation of the joint may occur.

Ninety-eight percent of chondroblastomas are located in the epiphysis of the bone. Mature cartilage is present only focally in some tumors. Chondroblastomas are almost always confined to the original bone, but on rare occasions they can penetrate the cortex and enter the joint or the soft tissues. Chondroblastomas may also undergo aneurysmal changes with secondary aneurysmal bone cyst (ABC) formation. In this setting, the tumor undergoes necrosis with hemorrhage and large cystic spaces that are filled with bloody fluid compose a significant portion of the tumor. Since they are aggressive, these tumors can cause extensive destruction of the bone. Treatment is similar to that of GCT and includes a thorough curettage of the tumor and tumor cavity.

Cryosurgery is recommended to eradicate microscopic tumor cells. The tumor cavity may be packed with cement and/or bone graft and may require metallic internal fixation. There have been rare reports of chondroblastoma metastasizing to the lungs; however, patients can still be cured with metastasectomy. In some cases, metastases do not appear for up to 30 years following the initial diagnosis. There are reported cases of chondroblastomas treated with radiation that have later undergone malignant transformation to fibrosarcomas and osteosarcomas. Thus, one should refrain from using radiation to treat this type of tumor. The first procedure should be undertaken with great care to ensure local control of this tumor.

Enchondroma

An enchondroma (sometimes called a central chondroma) is a benign intramedullary tumor of cartilage. It accounts for about 10% of all benign bone tumors. These tumors are believed to arise from cartilaginous nests of cells that are displaced from the growth plate during development. Enchondromas occur in persons of virtually all ages, but 60% of patients are between 15 and 40 years of age. Some patients complain of pain due to stress fractures through the area of the tumor. In other cases, the tumors are asymptomatic and are discovered incidentally on radiographs taken for other reasons. The tumors may also appear as hot spots in patients undergoing a skeletal scan for other reasons. Increased uptake on a bone scintigraphy is not a sign of malignancy but of enchondral ossification, which normally occurs in enchondromas. The proximal humerus is commonly affected.

Enchondromas must be differentiated from chondrosarcomas, and it is particularly difficult to differentiate a low-grade chondrosarcoma (also known as an enchondrosarcoma) from an enchondroma. Special clinical and radiographic criteria are used to differentiate the two entities. In general, low-grade chondrosarcomas are greater than 5 cm in size and cause endosteal cortical erosion

through the cortex of the bone. They also typically occur in more-proximal locations than enchondromas do. The presence of pain and the absence of fracture should be regarded as highly suspicious for a low-grade chondrosarcoma. Tumors arising in the digits are rarely malignant. Chondrosarcomas, however, can arise from enchondromas. Thus, enchondromas should be followed with yearly radiographs and treated if they begin to cause pain, to erode into the inner cortex, or to increase to a size that suggests malignancy. Biopsy does not help distinguish a low-grade chondrosarcoma from an enchondroma. Most enchondromas are treated with bone graft and/or polymethylmethacrylate (PMMA). This tumor should not be biopsied because it is pathologically very difficult to distinguish between a low-grade chondrosarcoma and an enchondroma. The two lesions look very similar under a microscope, and if a biopsy from a small area of the lesion is performed, the results will be inconclusive. Thus, the entire tumor should be curetted if there is pain and endosteal scalloping. If radiographic and clinical information suggest that this may be a low-grade chondrosarcoma, then cryosurgery may be performed. The bone may require reconstruction with cement and/or bone graft and stabilization with intramedullary pins. Rarely is a primary prosthetic replacement required.

Unicameral Bone Cysts

A unicameral bone cyst (UBC) is a benign cavity of bone that is filled with clear or bloody fluid. Other terms for this lesion include benign bone cyst and simple bone cyst. UBCs constitute 3% of all primary bone lesions. Most occur in the proximal or midhumerus. UBC does not appear to be a true tumor, and its cause is unknown. It may occur secondarily to intraosseous hypertension and failure of venous outflow in the region of the bone. There is a male predilection of 3:1. Sixty-five percent of UBCs occur in teenagers, and 20% occur in the first decade of life. The patient usually presents with pain. Despite popular belief, fracture of the bone cyst usually does not result in permanent healing. Preferred treatment is aspiration of the cyst followed by high-pressure injection with cortisone and Renografin. The procedure is performed under fluoroscopy to ensure that the entire cavity is filled and that the fluid enters the venous outflow, thus restoring circulation in the area of the cyst. The procedure is done under general anesthesia. The majority of cysts are cured following the first injection; however, some require several injections. Two-thirds of patients are cured with three injections or less. Patients who are not cured in this manner can be treated with curettage and bone grafting or bone-filling substitute. Patients with fractures through the area of the cyst are immobilized until the fracture heals and are then treated with aspiration and injection. Aspirated bone marrow or growth factors may be injected into the cyst to aid with healing (Fig. 37-12).

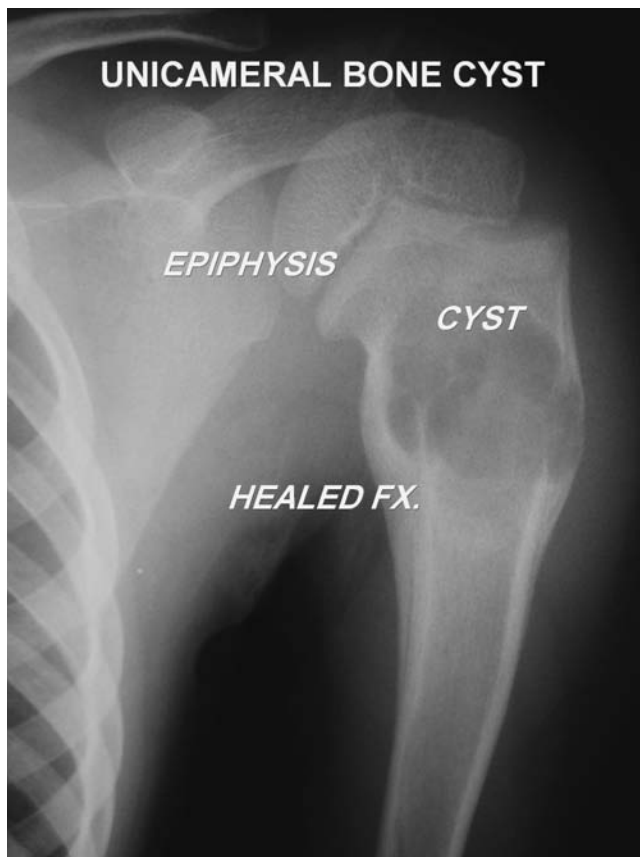


Figure 37-12 Healed unicameral bone cyst (UBC) of the proximal humerus. UBCs are typically asymptomatic until a fracture occurs. Surgical treatment is postponed until the fracture is healed. UBC can be treated by several modalities including aspiration and injection with methylprednisolone, curettage, and filling of the defect with one of many bone substitutes. Alternatively, autogenous bone graft can be utilized.

Malignant Tumors

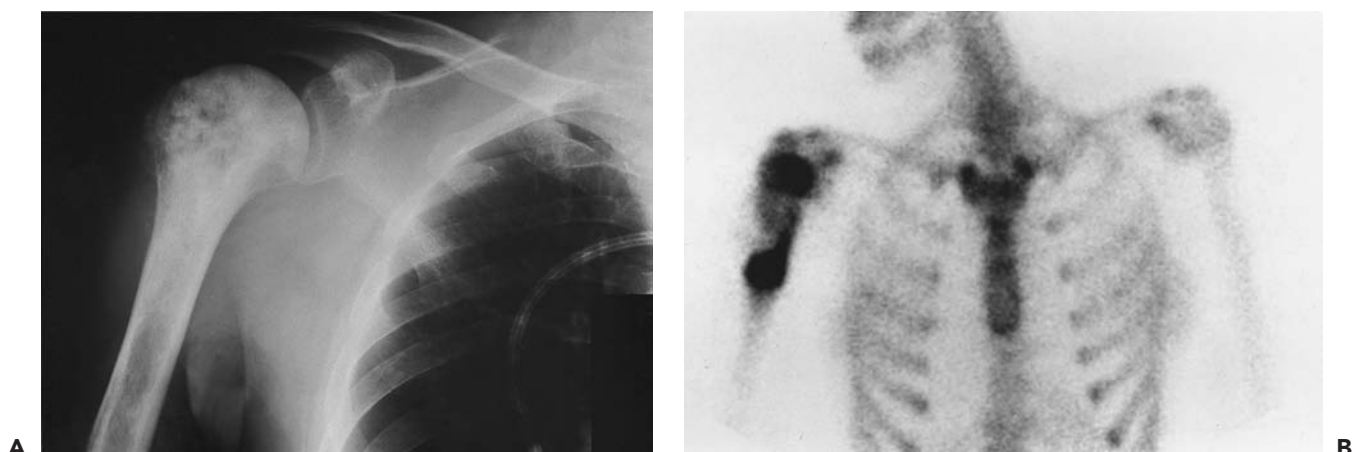
Osteosarcoma

Osteosarcoma is a high-grade, malignant spindle cell tumor that most often arises within a bone. Its distinguishing characteristic is the production of “tumor” osteoid or immature bone directly from a malignant spindle cell stroma.

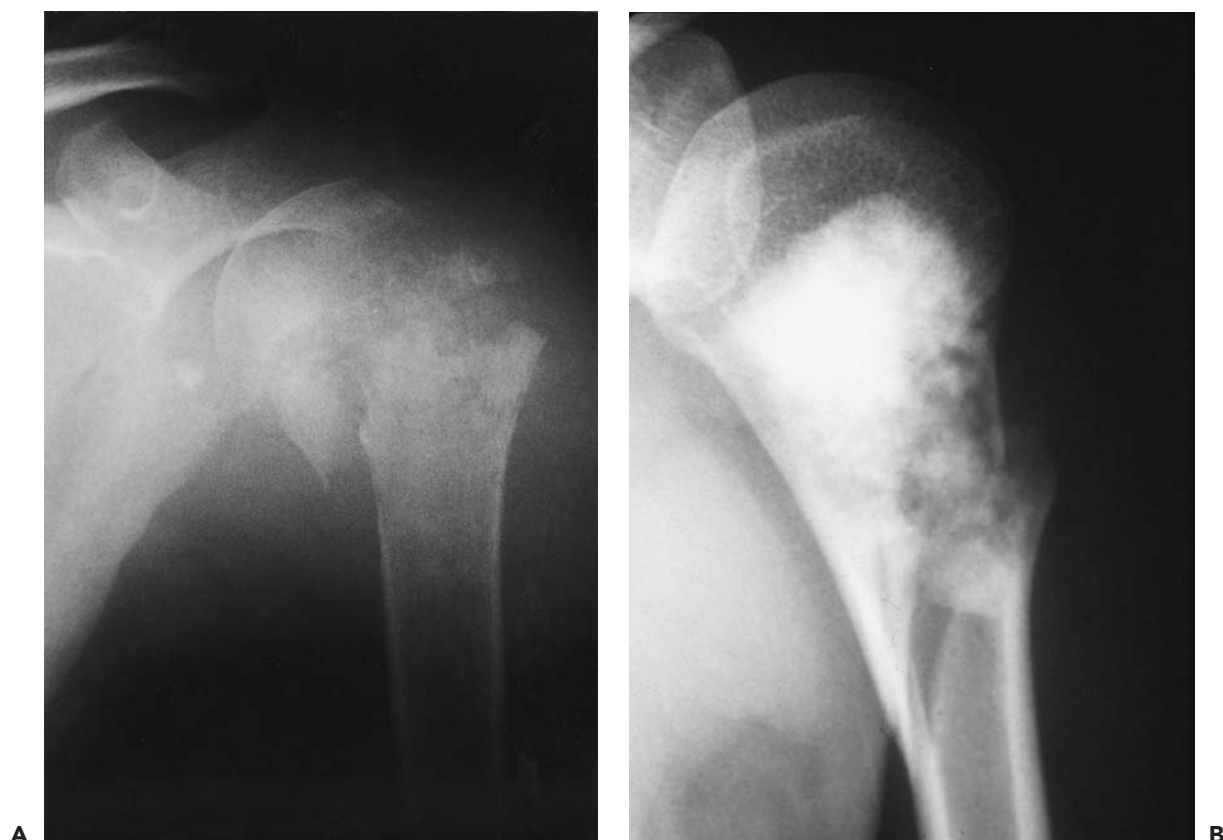
Osteosarcoma typically occurs during childhood or adolescence, with the peak incidence to be between 10 and 19 years of age. The overall incidence is 2.1 cases per million people per year. When osteosarcoma occurs in patients older than 40 years, it is usually associated with a preexisting condition, such as Paget’s disease, irradiated bones, multiple hereditary exostosis, or polyostotic fibrous dysplasia.

Bones of the knee joint and the proximal humerus are the most common sites, accounting for 50% and 25%, respectively, of all osteosarcomas. Between 80% and 90% of osteosarcomas occur in the long tubular bones, and the axial skeleton is rarely affected. With the exception of serum alkaline phosphatase (AP) levels, which are elevated in 45% to 50% of patients, laboratory findings are usually not helpful. Furthermore, elevated AP per se is not diagnostic, because it is also found in association with other skeletal diseases. Pain is the most common complaint. Night pain gradually develops and is a hallmark of skeletal involvement. Physical examination demonstrates a firm, soft mass fixed to the underlying bone with slight tenderness. No effusion is noted in the adjacent joint, and motion is normal. Incidence of pathologic fracture is less than 1%. Systemic symptoms are rare.

The proximal humerus is the third most common site for osteosarcoma. Osteosarcomas in this area tend to have a poorer prognosis than those around the knee, and most have significant extraosseous components (Figs. 37-13 and 37-14). Plain radiographs suggest the correct diagnosis. All



Figures 37-13 Osteosarcoma of the proximal humerus. **(A)** Plain radiograph showing marked sclerosis of the proximal one-third of the humerus with cortical destruction. The tumor extends from the proximal one-third of the diaphysis to the subchondral bone. **(B)** Bone scan (late phase) of the proximal humerus showing marked bony uptake. This bone scan alone is not characteristic of an osteosarcoma, but it is indicative of the extension of the lesion. Note that there is only minimal extraosseous component demonstrated.



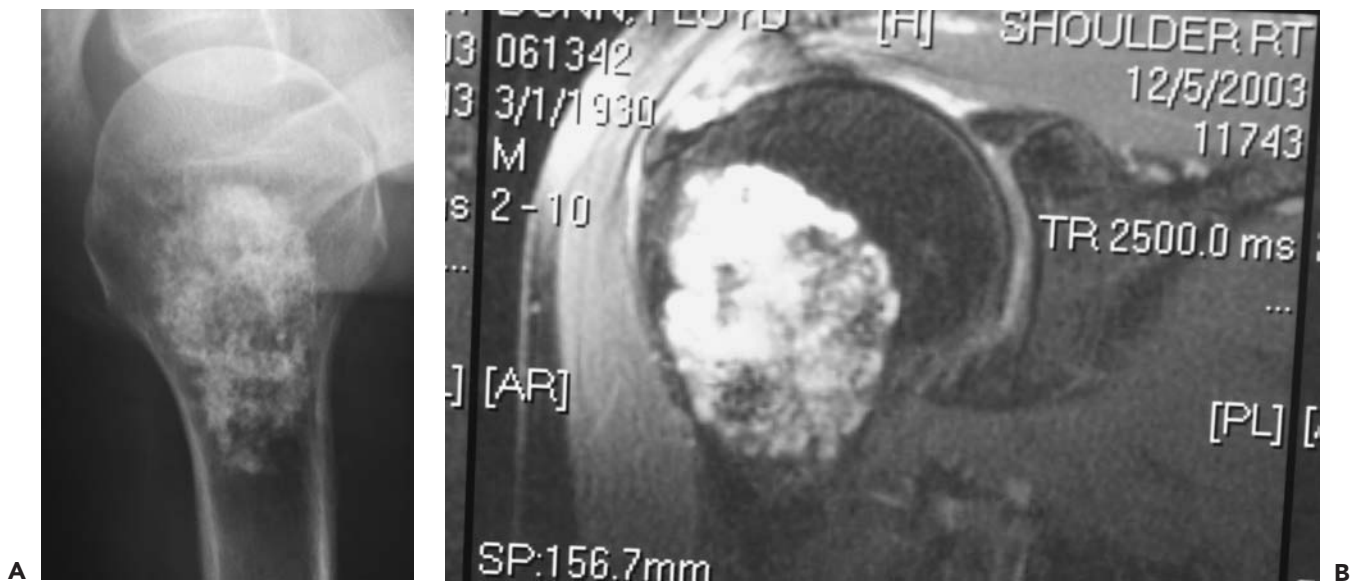
Figures 37-14 Osteosarcoma of the proximal humerus with a pathologic fracture. (A) Plain radiograph showing a pathologic fracture prior to treatment with induction chemotherapy. (B) The same patient following 4 months of induction chemotherapy, prior to attempted limb-sparing surgery. Note that the pathologic fracture has healed and that the tumor has undergone ossification (both positive prognostic indicators). Pathologic fracture through an osteosarcoma classically required a forequarter amputation. Today, with induction chemotherapy, most pathologic fractures will heal, indicating significant tumor necrosis.

staging studies are performed prior to biopsy. If the axillary vessels are free of tumor, a limb-sparing procedure, preferably an extraarticular resection, is generally indicated. A modified Tikhoff-Linberg procedure (type VB) provides adequate resection of the proximal humerus for high-grade sarcomas. This includes en bloc removal of 15 to 20 cm of the humerus and shoulder joint, with the deltoid, rotator cuff, and portions of the biceps and triceps muscles. Reconstruction involves suspension of the arm, motor reconstruction, and provision of adequate soft tissue coverage.

Extraarticular resection of the glenohumeral joint by medial scapulectomy is safer than intraarticular resection. A modular prosthesis is used for reconstruction. Soft tissue reconstruction and suspension are essential to stabilize the shoulder, prevent infection, and avoid postoperative pain, instability, and fatigue. Static suspension of the prosthesis is accomplished with Dacron tape. Dynamic suspension is accomplished by transferring the biceps tendon to the clavicle. The prosthesis is covered with the pectoralis major and latissimus muscles. Hand and wrist function is normal after resection. Shoulder abduction

and flexion is minimal; however, rotation is preserved. Latissimus dorsi transfer and scapulothoracic motion permit external rotation. The pectoralis major enables internal rotation. Cosmesis is acceptable and can be enhanced with the use of a shoulder pad.

Alternatively, resection of the proximal humerus for osteosarcomas can be performed by an intraarticular resection that preserves the glenoid and the adjacent deltoid muscle. The problems associated with this procedure include significant local recurrence and instability of the reconstructed prosthesis or allograft. When the glenoid and deltoid are preserved in this procedure, minimum margins are obtained along the shoulder joint, deltoid muscle, and axillary nerve. Because of this serious drawback, this technique is not recommended by the surgical author (MM). Less than 5% of osteosarcomas of the proximal humerus (usually those without an extrasosseous component [stage IIA]) can be treated by an intraarticular resection. When an intraarticular resection is performed, the senior author recommends reconstruction of the glenohumeral ligaments with a Gore-Tex aortic graft.



Figures 37-15 Chondrosarcoma (enchondrosarcoma) of the proximal humerus. **(A)** Plain radiograph of the proximal humerus showing a large area of calcification with adjacent cortical thinning and destruction. There is a lytic component in addition to the calcified component. **(B)** Magnetic resonance imaging scan showing typical calcification appearance. Calcification is often described as small nodules and curly cues.

Chondrosarcoma

Primary (central) and secondary (peripheral) chondrosarcomas commonly occur in the proximal humerus. Peripheral lesions tend to be large but low grade, whereas central lesions tend to be higher grade. Stage I tumors of the proximal humerus can be treated by excision (type I) with minimal functional deficit (Fig. 37-15).

High-grade sarcomas require a modified Tikhoff-Linberg resection (type V) or, rarely, a forequarter amputation. Intraarticular and synovial involvement with high-grade cartilaginous lesions are more common in this location than in other sites. A prosthesis is recommended for reconstruction following a marginal resection (type I) for a low-grade sarcoma.

Ewing's Sarcoma

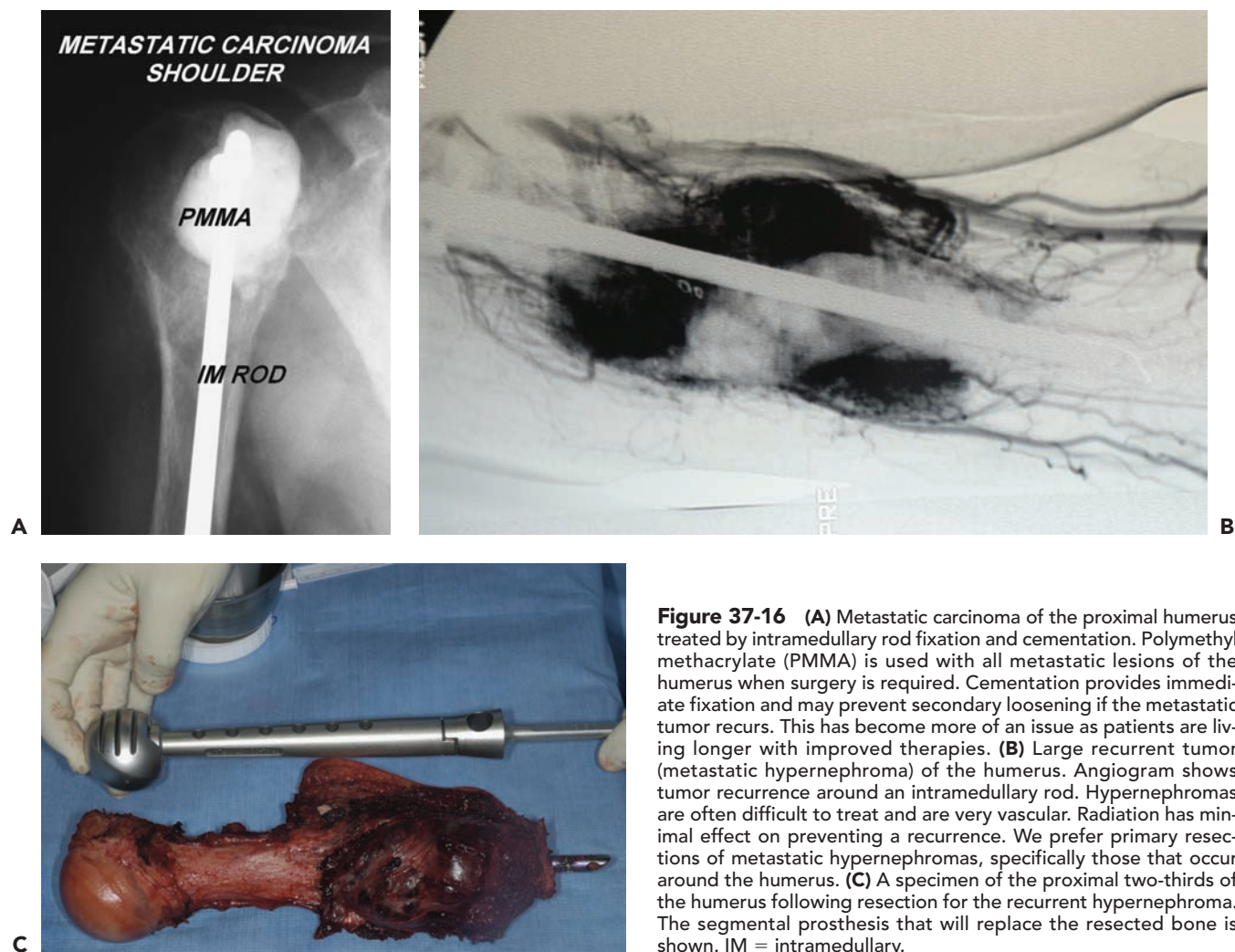
Treatment of Ewing's sarcoma follows the guidelines for other high-grade bone sarcomas of the humerus, even though fewer than 10% of Ewing's sarcomas involve the proximal humerus. The flat bones, specifically the scapula and clavicle, are the most common sites for Ewing's sarcoma. Ewing's sarcomas often decrease dramatically in size following preoperative chemotherapy, in which case the deltoid and axillary nerve may be preserved. Surgery should never precede induction chemotherapy. Often, there is no detectable soft tissue component; in such cases, a type I resection may be indicated. Ewing's sarcomas may dramatically decrease in size following induction chemotherapy. For this reason, intraarticular resections (type I) are

recommended. Radiation therapy is not recommended in patients treated with a prosthesis or an allograft because it often leads to severe local complications, such as restriction of motion, infection, severe lymphedema, and secondary amputation.

Metastatic Carcinomas

All carcinomas can metastasize to the proximal humerus (Fig. 37-16). Many large metastatic tumors with marked bony destruction may be resected by a primary resection and prosthetic replacement. Hypernephroma, which is extremely vascular and has a predilection for this location, may present a unique problem of uncontrollable bleeding. Radiography often reveals marked destruction and ballooning, much like that seen in ABCs and primary sarcomas. Simple biopsy may lead to severe hemorrhage. Preoperative angiography with embolization is recommended. The anterior and posterior circumflex vessels should be ligated prior to any surgical procedure. If curettage and cementation are not feasible because of severe bony destruction, an intraarticular resection with prosthetic replacement (type I) is indicated.

Most metastatic carcinomas of the proximal humerus can be treated with radiation therapy rather than surgery. If there is a pathologic fracture, then curettage through a deltopectoral interval should be performed. The defect is reconstructed with PMMA, intramedullary pins, an intramedullary rod, or a long-stem hemiarthroplasty. Bone graft is not used to fill a defect if a metastatic carcinoma is present.



CRYOSURGERY

Cryosurgery extends the margin of curettage and makes it equivalent to that of wide resection. Compared with other techniques, cryosurgery with composite fixation (PMMA combined with intramedullary rods) not only preserves joint function, but also significantly decreases the rate of local tumor recurrence. Although a relatively simple procedure, cryosurgery can cause a significant morbidity if performed inappropriately. Effective and safe procedures must follow these consecutive steps: (1) adequate exposure of the tumor, (2) meticulous curettage and burr drilling, (3) soft tissue mobilization and protection before introduction of liquid nitrogen to the tumor cavity, (4) internal fixation of the tumor cavity, and (5) protection of the operated bone throughout the healing period (Fig. 37-17).

The technique for curettage and cryosurgery is as follows:

- All gross tumor is removed with hand curettes.
- After the tumor tissue is curetted away from the inner wall of the lesion, the reactive wall reveals an irregular

contour. This irregularity makes it virtually impossible to remove all the tissue; therefore, high-speed burr drilling is achieved using a Midas Rex or Black Max.

- Liquid nitrogen is applied to the cavity utilizing liquid nitrogen or argon probes or, more often, the Marcove direct-pour method. All bony perforations are identified and sealed, and the surrounding skin, soft tissues, and neurovascular bundle are protected by mobilization and shielding with Gelfoam.
- Using the direct-pour method, liquid nitrogen is poured through a stainless steel funnel into the tumor cavity. Care is taken to fill the entire cavity. The Gelfoam immediately freezes and forms a seal around the funnel. Thermocouples are used to monitor the freezing effect within the bone cavity, cavity wall, and adjacent soft tissue, as well as the rim of bone 1 to 2 cm from the periphery of the cavity. The surrounding soft tissues are continuously irrigated with warm saline solution to decrease the possibility of thermal injury. The liquid nitrogen is left to evaporate, and then spontaneous thaw is allowed to occur over 3 to 5 minutes. Once the

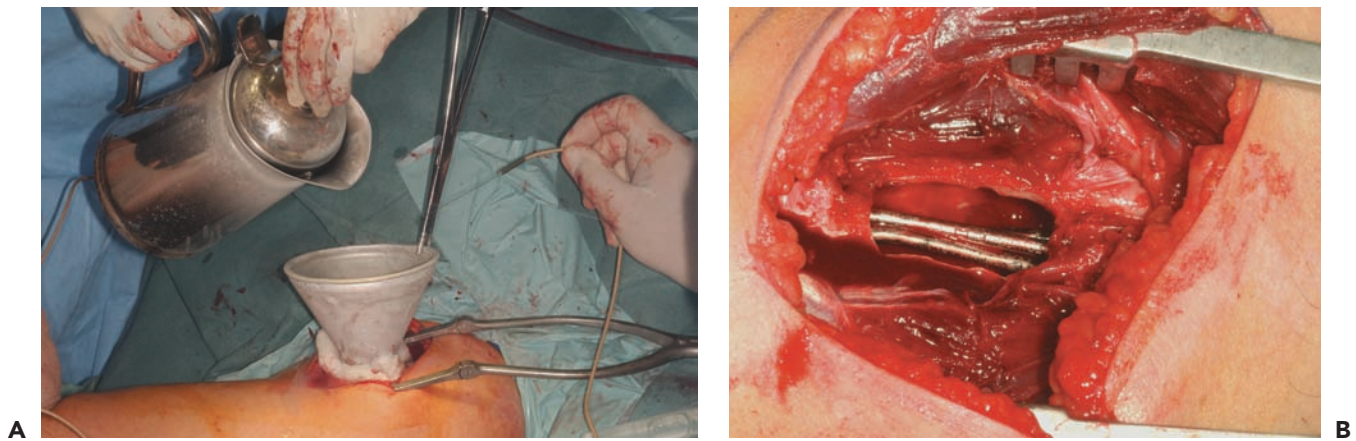


Figure 37-17 Cryosurgery. **(A)** This operative photograph shows the early technique of cryosurgery as developed by Dr. Ralph Marcove using the direct-pour method of liquid nitrogen directly within the tumor cavity. Presently, we use cryoprobes for smaller lesions and the direct-pour method for larger lesions of bone. **(B)** Reconstruction of the curetted defect. It is necessary to reconstruct large defects following curettage resection, especially for giant cell tumors and chondrosarcomas. We prefer the technique of composite reconstruction using Steinmann pins to support the cavity with polymethyl methacrylate cementation.

temperature of the cavity rises above 0°C , the cycle is considered complete. Two to three freeze-thaw cycles are administered, with a saline irrigation occurring between cycles.

Reconstruction is achieved utilizing PMMA, internal fixation, and subchondral bone graft, which provides immediate stability and structural support for large defects and allows early rehabilitation of the adjacent joint.

- To reconstruct the defect, a Gore-Tex aortic graft is sutured to the remaining portion of the glenoid with Dacron tape.
- The humeral head of the prosthesis is inserted within the Gore-Tex and then sutured through holes in the prosthesis using Dacron tape.

TECHNIQUE OF TYPE I RESECTION AND RECONSTRUCTION

If an intraarticular (type I) resection is to be performed, the axillary nerve and the deltoid muscle must not be invaded by tumor and must be preservable (Figs. 37-18 to 37-21):

- The utilitarian shoulder incision is utilized.
- The pectoralis major is detached and retracted to expose the axillary vessels and nerves.
- The neurovascular bundle must be dissected out carefully and retracted away from any soft tissue component of the tumor.
- The musculocutaneous nerve, radial nerve, and axillary nerve must all be preserved to ensure optimal hand, arm, and elbow function.
- The pectoralis major muscle is detached and reflected toward the chest wall.
- The pectoralis minor muscle and the conjoint tendon are then released from the coracoid.
- The proximal humerus is now exposed and resection can take place.

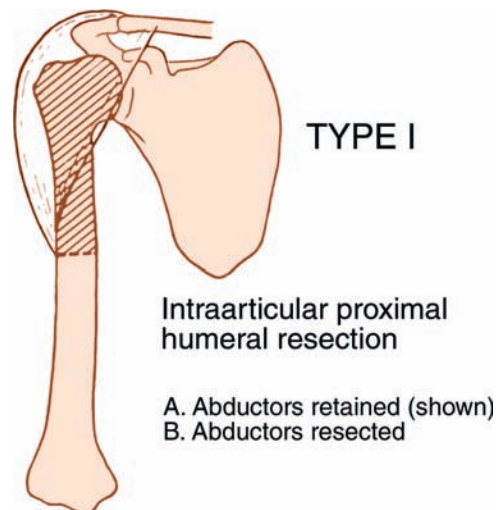


Figure 37-18 Type I shoulder girdle resection. Intraarticular proximal humeral resection with preservation of the deltoid muscle. Type I resections are usually performed for low-grade malignant tumors, such as chondrosarcomas and aggressive giant cell tumors. In general, type I resections are not performed for high-grade sarcomas. (From Malawer M, Wittig JC. Resections of the shoulder girdle. In: Malawer MM, Sugarbaker PH, eds. *Musculoskeletal cancer surgery: treatment of sarcomas and allied diseases*. Dordrecht, Netherlands: Kluwer Academic Publishers, 2001:184.)

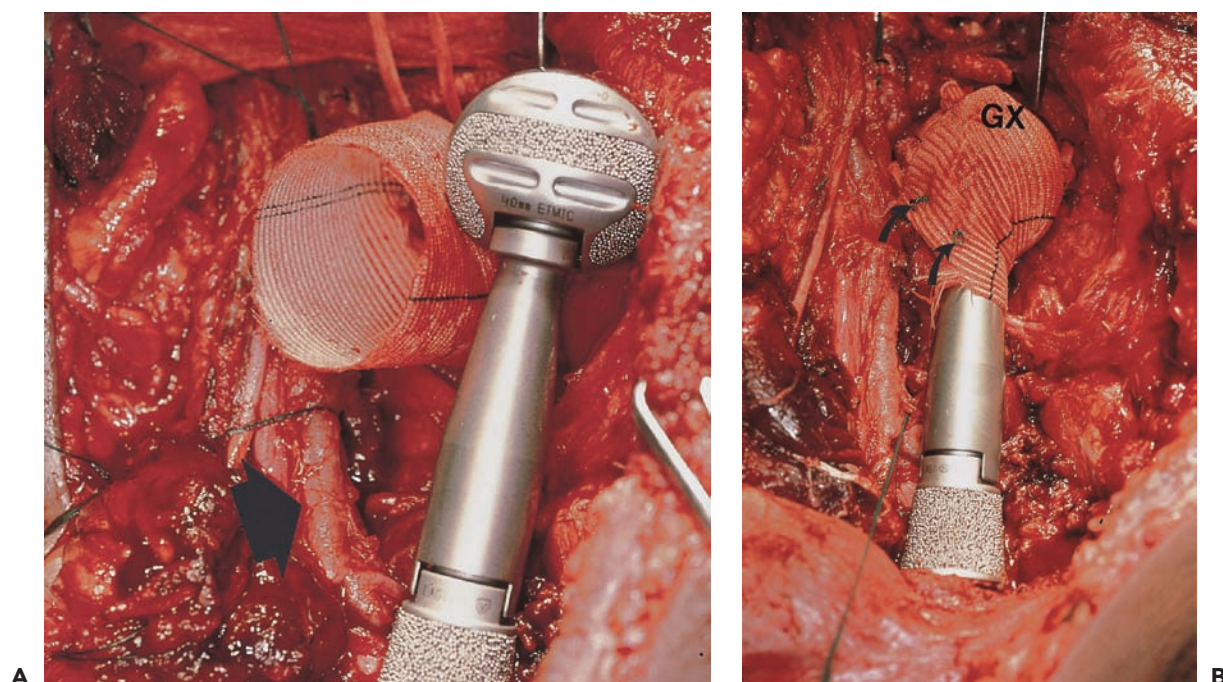


Figure 37-19 Gore-Tex reconstruction in conjunction with a proximal humeral replacement following a type I resection. Gore-Tex graft reconstruction of the capsule is essential to reconstruct shoulder stability. **(A)** The Gore-Tex is sutured to the remaining glenoid rim with Ethibond and Dacron tape. The prosthesis is then placed within this graft and sutured in place with Dacron tape through the Gore-Tex and the holes on the prosthesis. **(B)** Completion of Gore-Tex graft capsular reconstruction. Note the close relationship of the axillary nerve and the infraclavicular portion of the brachial plexus.

- The remaining capsular structure is sutured to the Gore-Tex to reinforce the capsule and the rotator cuff, as well as to prevent shoulder dislocation or subluxation.

TECHNIQUE OF EXTRAARTICULAR PROXIMAL HUMERAL RESECTION AND PROSTHETIC RECONSTRUCTION (TYPE VB)

The technique of extraarticular proximal humeral resection and prosthetic reconstruction may be modified for an intra-articular resection. We recommend an extraarticular (type VB) resection (Fig. 37-22). In general, the deltoid muscle and axillary nerve cannot be preserved for high-grade sarcomas. The anterior and posterior components of the utilitarian shoulder-girdle incision are utilized (see previous text). Three osteotomies are required for an extraarticular resection.

Resection (Figs. 37-23 and 37-24)

- Place the patient in a lateral position, allowing some mobility of the upper torso.
- Prepare the skin down to the level of the midline anterior and posterior to the umbilicus, and cranially past the hairline.

- Start the incision over the junction of the inner and middle thirds of the clavicle, continue along the deltopectoral groove, and then move down the arm over the medial border of the biceps muscle.
- Excise the biopsy site, leaving a 2- to 3-cm margin of normal skin. Do not open the posterior incision until the anterior dissection is complete.
- For exploration of the axilla, open the skin through the superficial fascia.
- Dissect the skin flap anteriorly off the pectoralis major muscle to expose its distal third, and uncover the short head of the biceps muscle. The key to exposure of the anterior shoulder girdle and axilla is the detachment and mobilization of the pectoralis major muscle with partial mobilization medially toward the chest wall.
- Dissect the pectoralis major muscle overlying the axilla free of fat, so that its insertion on the humerus can be visualized. Divide this muscle just proximal to its tendinous insertion on the humerus, and use a suture to tag the portion of muscle remaining with the patient.
- Identify the axillary sheath and visualize the coracoid process. To expose the axillary sheath along its full extent, divide the pectoralis minor, the short head of the biceps, and the coracobrachialis muscles at their insertion on the coracoid process. Tag all proximal muscles with a suture for later identification and use in reconstruction.

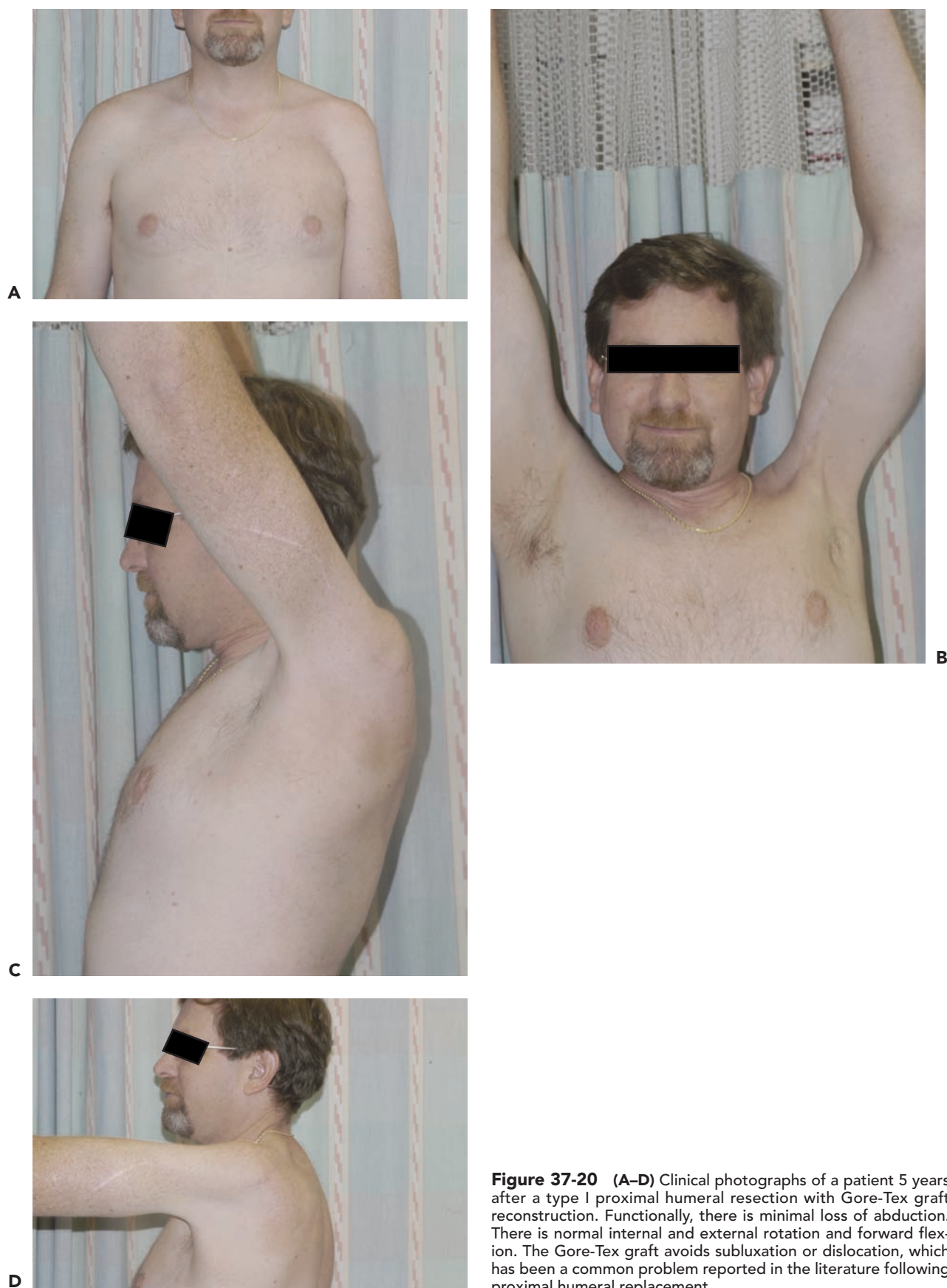

Figure 37-20 (A-D) Clinical photographs of a patient 5 years after a type I proximal humeral resection with Gore-Tex graft reconstruction. Functionally, there is minimal loss of abduction. There is normal internal and external rotation and forward flexion. The Gore-Tex graft avoids subluxation or dislocation, which has been a common problem reported in the literature following proximal humeral replacement.

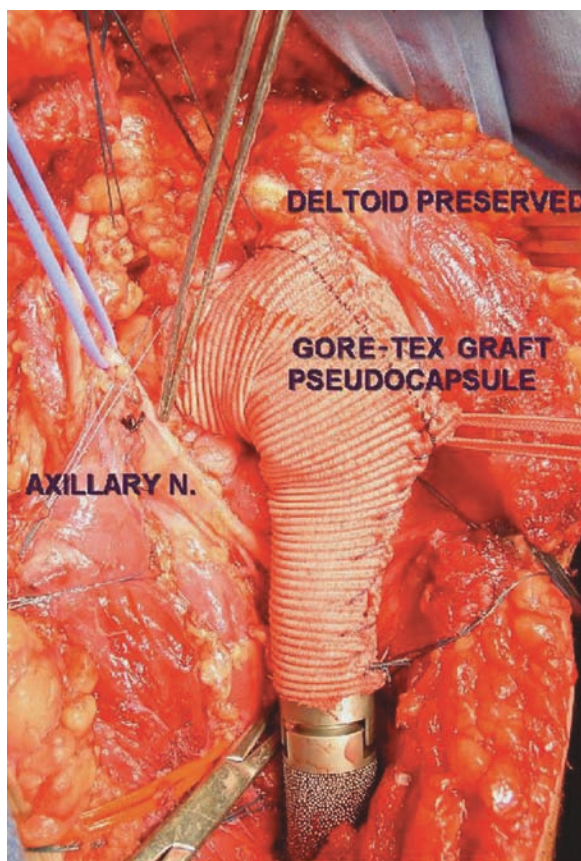


Figure 37-21 Intraoperative photograph showing Gore-Tex reconstruction of the shoulder joint capsule following an intraarticular resection of the humerus. The segmental prosthesis can be seen. The Gore-Tex is sutured to the glenoid and then to fixation holes on the proximal humerus. Gore-Tex reconstruction is always utilized following an intraarticular resection to prevent secondary subluxation or dislocation of the prosthesis.

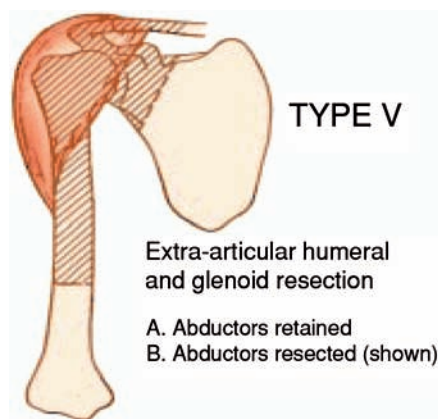


Figure 37-22 Schematic diagram of a type VB shoulder girdle resection. This represents an extraarticular humeral and glenoid resection with removal of the abductor muscles. (From Malawer M, Wittig JC. Resections of the shoulder girdle. In: Malawer MM, Sugarbaker PH, eds. *Musculoskeletal cancer surgery: treatment of sarcomas and allied diseases*. Dordrecht, Netherlands: Kluwer Academic Publishers, 2001:185.)

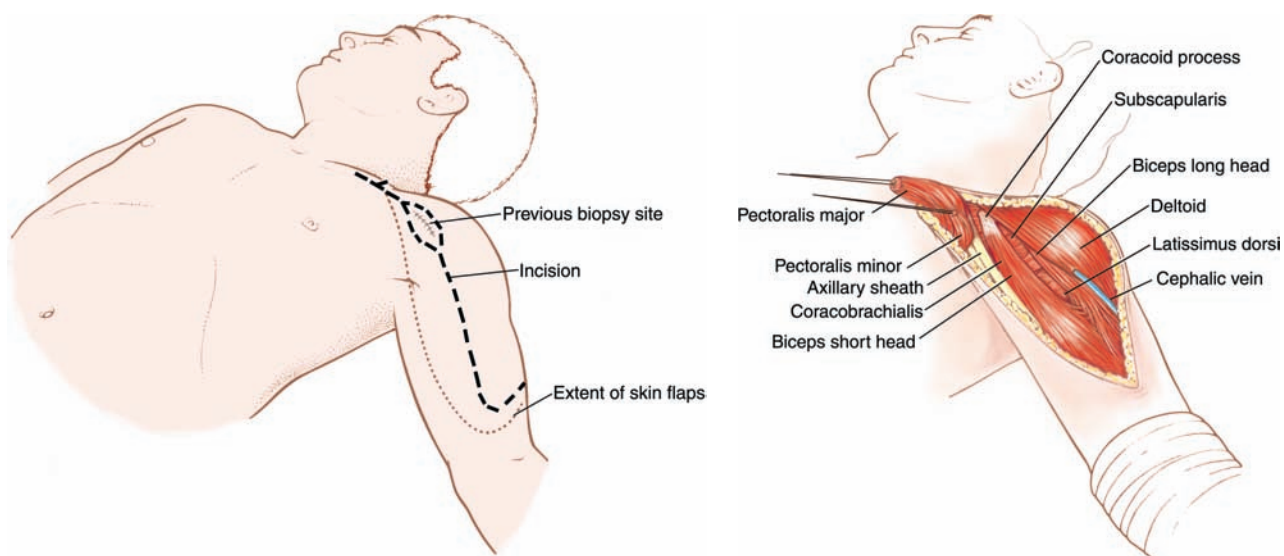


Figure 37-23 Surgical technique of a proximal humeral resection (see text). **(A)** Anterior incision extends from the midclavicle, through the deltopectoral interval, and down the arm as shown. (From Malawer M, Wittig JC. The Tikhoff-Linberg procedure and its modifications. In: Malawer MM, Sugarbaker PH, eds. *Musculoskeletal cancer surgery: treatment of sarcomas and allied diseases*. Dordrecht, Netherlands: Kluwer Academic Publishers, 2001:531.) **(B)** The important first step is identification of and release of the pectoralis major from the proximal humerus and reflecting it upon the chest wall. This exposes the axillary structures. It is important to carefully dissect and identify the infraclavicular portion of the brachial plexus and the nerves (axillary and musculocutaneous) prior to ligation. (From Malawer MM. Tumors of the shoulder girdle, technique of resection and description of a surgical classification. *Orthop Clin N Am* 1991;22:7-35.)

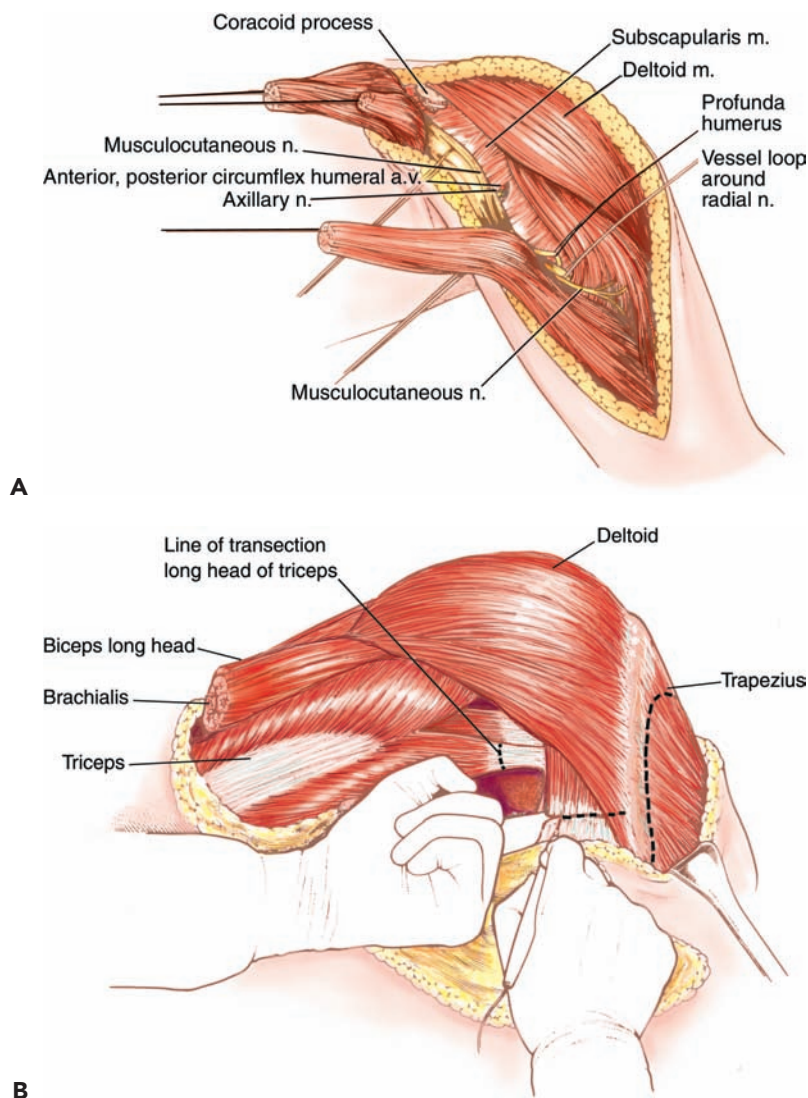


Figure 37-24 (A) Second stage of release of musculature of the axillary space. The coracobrachialis is released from the coracoid and the pectoralis minor is released and reflected toward the chest. This exposes the axillary fascia and the axillary vessels. Care is needed to dissect out the individual nerves prior to ligation. The axillary nerve is ligated as well as the anterior and posterior circumflex vessels at the lower border of the subscapularis muscle. The radial nerve is identified, mobilized, and preserved. Radial nerve resection is rarely required. (From Malawer M, Wittig JC. *The Tikhoff-Linberg procedure and its modifications*. In: Malawer MM, Sugarbaker PH, eds. *Musculoskeletal cancer surgery: treatment of sarcomas and allied diseases*. Dordrecht, Netherlands: Kluwer Academic Publishers, 2001:532.) (B) Posterior view showing identification and mobilization of the posterior aspect of the glenoid in which the glenohumeral joint is resected with a Gigli saw (see text). (From Wittig JC, Kellar-Graney KL, Malawer MM, Bickels J, Meller I. Limb-sparing surgery for high-grade sarcomas of the proximal humerus. *Tech Shoulder Elbow Surg*; 2(1):54-69.)

- Before exploring the neurovascular bundle, develop the skin flaps just minimally. If the tumor is found unsuitable for limb-salvage surgery, more-extensive flap dissection would lead to tumor contamination of the skin needed for forequarter amputation.
- In dissecting the neurovascular bundle, pass vessel loops around the neurovascular bundle near the proximal and distal ends of the dissection. Medial traction on the neurovascular bundle allows visualization of the axillary nerve, the posterior circumflex humeral artery, and the anterior circumflex humeral artery. (It is rare to preserve the axillary nerve in large stage IIB sarcomas of the proximal humerus, but if the tumor is small and intraosseous, the nerve can be preserved.) Ligate and divide these three structures.
- If the neurovascular bundle is tumor free, proceed with dissection for a limb-salvage procedure.
- Isolate and preserve the musculocutaneous nerve. It is rarely necessary to sacrifice this nerve to preserve tumor-free margins of resection.
- Divide the deep fascia between the short and long heads of the biceps muscle; this permits easy visualization of the musculocutaneous nerve.
- Identify the radial nerve at the lower border of the latissimus dorsi muscle, where it passes around and behind the humerus in its midportion (spiral groove) into the triceps muscle group.
- Pass a finger around the humerus to move the nerve away from the bone.
- Trace the ulnar nerve down the arm. Divide the intermuscular septum between the biceps and the triceps over the nerve to see it clearly.
- If performing an extraarticular resection, divide the muscle groups anteriorly to expose the neck of the scapula. Separate the short and long heads of the biceps to expose the humerus. Determine the site for the humeral osteotomy, and transect the long head of the biceps and brachialis muscles at this level.
- Identify the inferior border of the latissimus dorsi muscle and make a fascial incision that makes it possible to

pass a finger behind the latissimus dorsi and teres major muscles several centimeters from their insertion.

- Transect the latissimus dorsi and teres major muscles using electrocautery.
- Rotate the humerus externally to expose the subscapularis muscle, which is transected at the level of the coracoid process. Take care not to enter the joint space. Tag the portions of these muscles that will remain with the patient for future reconstruction. Transecting these muscles exposes the anterior portion of the neck of the scapula.
- Now move to the posterior aspect of the patient. Rotate the table, if desired, to provide better visualization.
- Begin the posterior incision anteriorly over the junction of the middle and lateral thirds of the clavicle. Continue down over the lateral third of the scapula past the lower edge of this bone.
- Develop a skin flap by dissecting the skin and subcutaneous tissue between the anterior and posterior incisions from the underlying deltoid muscle down to the level of the midhumerus.
- If removing the entire scapula (type VI resection), make the posterior incision longer and curve it posteriorly to allow the skin flap to expose muscle over the entire scapula.
- Divide the posterior muscle group. Divide the thick fascia that joins the posterior border of the deltoid muscle to the infraspinatus muscle and scapular spine. Leave the deltoid muscle intact to cover the tumor mass.
- Transect the trapezius muscle from its insertions on the scapular spine and acromion.
- Pass the index finger beneath the teres minor up to the area of the planned scapular osteotomy. Transect the supraspinatus, infraspinatus, and teres minor muscles over the neck of the scapula, thus allowing the plane of transection through the neck of the scapula to be exposed. Tag all transected muscles proximally.
- While shielding the radial and ulnar nerves, transect the triceps muscles at the level selected.
- Perform clavicular, scapular, and humeral osteotomies as follows (Fig. 37-25)
 - (a) Divide the clavicle at the junction of its middle and inner thirds. This is usually accomplished with a Gigli saw.
 - (b) Divide the scapula through its surgical neck medial to the coracoid process, also using a Gigli saw.
 - (c) Perform the clavicular and scapular osteotomies before the humeral osteotomy.
 - (d) Remove the entire specimen, taking care to protect all the neurovascular structures at each osteotomy site.
- If resecting the entire scapula, take the skin flap back to the medial edge of the scapula. Divide the rhomboid, levator scapula, and trapezius muscles from their insertions on the scapula. It is unnecessary to divide the teres major, teres minor, supraspinatus, infraspinatus, and subscapularis muscles when performing a full scapular resection.

- Transect the humerus 4 to 6 cm distal to the tumor, as determined by preoperative bone scan.
- Obtain frozen sections of tumor margins and touch preparations for cytologic examination of the marrow at the site of the osteotomy.

Proximal Humerus Prostheses

A modular replacement prosthesis is used for large segments of the proximal humerus. The design features of this device are summarized below.

Proximal Humeral Endoprosthesis (MRS, Stryker Orthopedics, Mahwah, NJ)

- Modular components, including stem, body, and humeral head
- Polished intramedullary stems for cement fixation available in multiple diameters and lengths
- Facing reamer to create a perfect seat for the stem–bone interface that protects the stem from bending stresses
- Porous coating (circumferential) at the prosthesis–bone junction for ingrowth of extracortical bone graft and soft tissue to seal the bone–cement–stem interface. Incorporation of extracortical bone graft also protects the prosthetic stem by sharing bending and loading stresses.
- Humeral heads (available in two sizes) with porous coating and metal loops or holes to facilitate muscle and tendon attachment and soft tissue ingrowth

The coracoid and acromion are not recreated on the prosthesis since they serve no function.

TECHNIQUE OF RECONSTRUCTION WITH MODULAR SEGMENTAL PROSTHESIS (MRS)

Endoprosthetic replacement, which has been in use since 1973, is the most common technique for reconstructing large proximal humeral defects (Figs. 37-26 to 37-29). It may be used for both intraarticular and extraarticular defects (i.e., when retaining the glenoid as well as when resecting it with the tumor). Alternatives (although not recommended by the senior author) to reconstructing the defects include allografts, allograft/prosthesis composites, dual fibulas, and vascularized fibulas. Only endoprosthetic replacement will be described in this chapter.

Originally, each patient received a custom-made prosthesis. In 1988, Howmedica (Rutherford, NJ) developed the modular replacement system (MRS), which has since undergone several improvements (see Fig. 37-27). The first MRS prosthesis placed in this location was performed in 1988 in Washington, D.C., for a large stage IIB osteosarcoma of the proximal humerus.

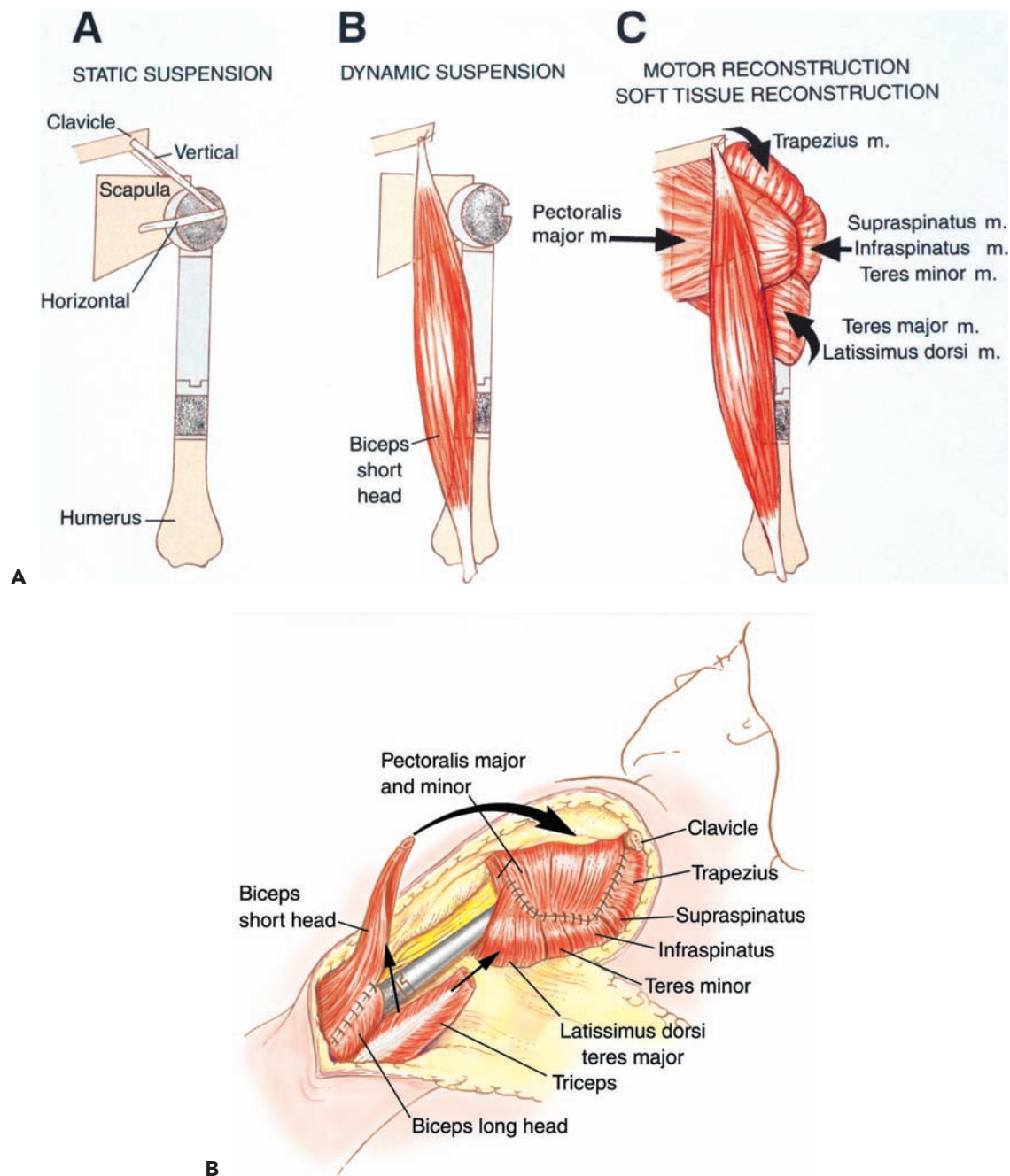


Figure 37-25 Schematic showing the three phases of reconstruction. **(A)** Schematic diagram showing the intraoperative reconstruction of the shoulder girdle musculature. The pectoralis major is sutured to the osteotomized end of the scapula. A prosthesis is placed anterior to the scapula and is covered by the pectoralis major muscle. The remaining muscles are sutured to the pectoralis major, reconstructing the shoulder girdle. The biceps and triceps are tenodesed together and to the muscles. **(B)** The pectoralis major has been sutured to the scapula following prosthetic reconstruction with Dacron tape. The biceps and triceps are then tenodesed to each other to complete the reconstruction. (From Rubert CK, Malawer MM, Kellar KL. Modular endoprosthetic replacement of the proximal humerus. Indications, surgical technique, and results. *Semin Arthroplasty* 1999;10(3):142-153.)

An MRS is used for both intra- and extraarticular reconstructions. The reconstruction is combined with multiple muscle transfers to reconstruct the resected soft tissues. For high-grade bone sarcomas, the deltoid and axillary nerve, along with the glenohumeral joint, are routinely removed

(type VB resection). Low-grade tumors are treated with an intraarticular resection and preservation of the abductor mechanism.

Soft tissue reconstruction is essential to cover the prosthesis and create shoulder stability. This is accomplished

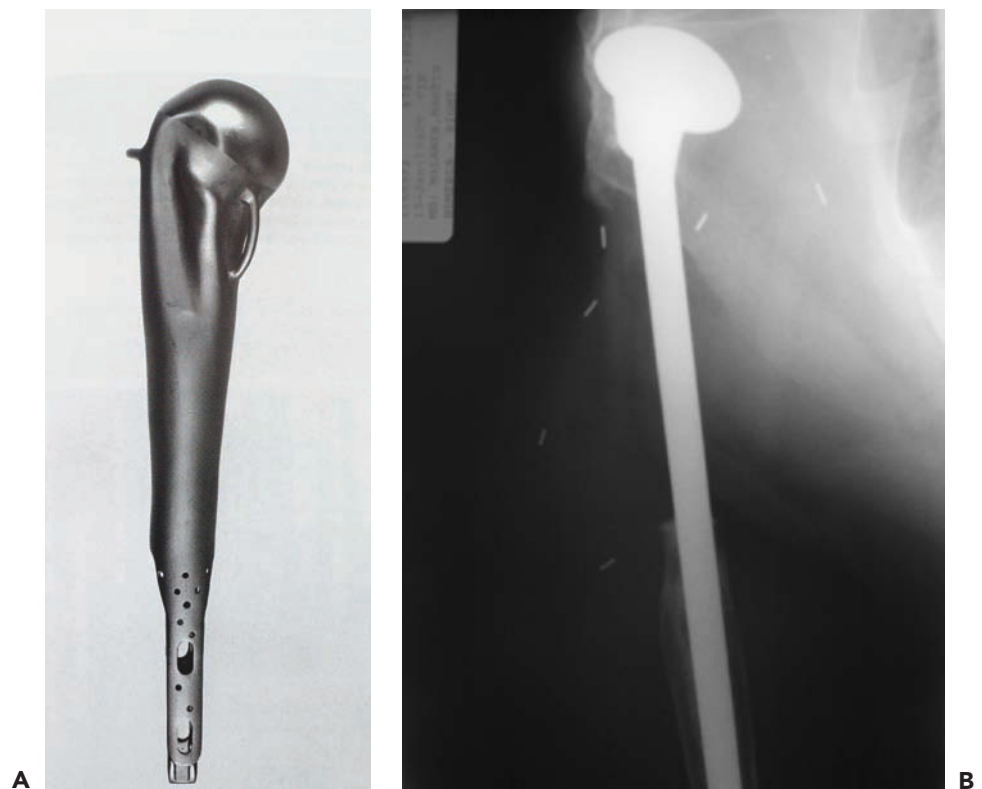


Figure 37-26 Historical prosthetic devices utilized for proximal humeral reconstruction. **(A)** Custom prosthesis with external phalanges for the proximal humerus utilized during the 1960s and 1970s. **(B)** A custom long-stemmed Neer prosthesis utilized by Dr. Ralph Marcove for proximal humerus reconstructions in the 1970s.

through a technique of dual suspension that entails static and dynamic reconstruction. Dacron tape is used to secure the prosthesis horizontally to the scapula and vertically to the clavicle through drill holes. The two sets of Dacron tape provide mediolateral and craniocaudal stability. Dynamic suspension, provided by transfer of the short head of the biceps muscle to the stump of the clavicle, allows elbow flexion. This also restores elbow flexion. Transfer of the trapezius also provides for vertical suspension.

Preservation and transfer of the pectoralis major, trapezius, supraspinatus, infraspinatus, teres minor, teres major, and latissimus muscles provide mobility of the shoulder. These muscle groups offer dynamic support, assist in suspension of the prosthesis, and provide soft tissue coverage, which is essential in preventing skin problems and secondary infection.

Endoprosthetic replacement is highly predictable and successful. There are minimal problems with subluxation following adequate soft tissue reconstruction. Malawer et al.,³ who have the most extensive experience with replacing the proximal humerus with the MRS, report 95% survival of the prosthesis as determined by Kaplan-Meier analysis at 10 years.

TECHNIQUE OF TOTAL HUMERAL RESECTION

Total humeral resection (i.e., removal of the shoulder and elbow joints) and replacement is an unusual procedure. It

is indicated when the tumor involves a large component of the medullary shaft.

Anatomic considerations relative to the proximal humeral component are similar to those previously described. Considerations relating to the midshaft and distal humerus center on the relationship of the tumor to the brachial artery and nerves. Angiography is required to determine the relationship to the brachial vessels medially and the antecubital fossa. MRI and bone scan are used to identify the extent of the humeral involvement, which, in turn, determines whether total humeral resection is required. The entire humerus should be removed in patients who have round cell tumors of the humerus and diaphysis.

The surgical approach is similar to that of a type V resection using multiple muscle transfers and Dacron tape. The resection is similar to that used for lesions of the proximal humerus but continues down to the elbow joint, which is opened anteriorly after mobilizing the brachial vessels and the median nerve through the antecubital fossa (Fig. 37-30).

Resection

- Explore the vessels proximally, release the circumflex vessels proximally, and identify the musculocutaneous, axillary, and radial nerves.
- Mobilize the brachial vessels throughout the length of the arm into the antecubital space to protect them and



Figure 37-27 Modular segmental replacement prostheses. These prostheses consist of three components: a stem of varying diameter, bodies of varying lengths, and humeral heads of various circumferences. Prostheses shown are the trials (holes within the bodies, not to be implanted).

the accompanying medial nerve. The ulnar nerve passes posteriorly through the intramuscular septum and can easily be identified in the midarm.

- Identify the radial nerve as it passes around the humerus and into the interval between the biceps and brachioradialis muscle, where it becomes the posterior interosseous nerve. Identify and preserve all these nerves, as well as the brachial artery and vein.
- Keep the triceps tendon attached to the olecranon.
- Perform anterior exposure of the elbow joint.
- Explore and identify the brachial vessels and the median nerve.
- Open the capsule of the elbow joint circumferentially; this makes it possible to fit the elbow component and seat it into the olecranon. Avoid a posterior approach to the elbow. Detach the flexor and extensor muscles from their origins on the humeral condyles. Retract the biceps, but do not detach it from its insertion onto the radial tuberosity.

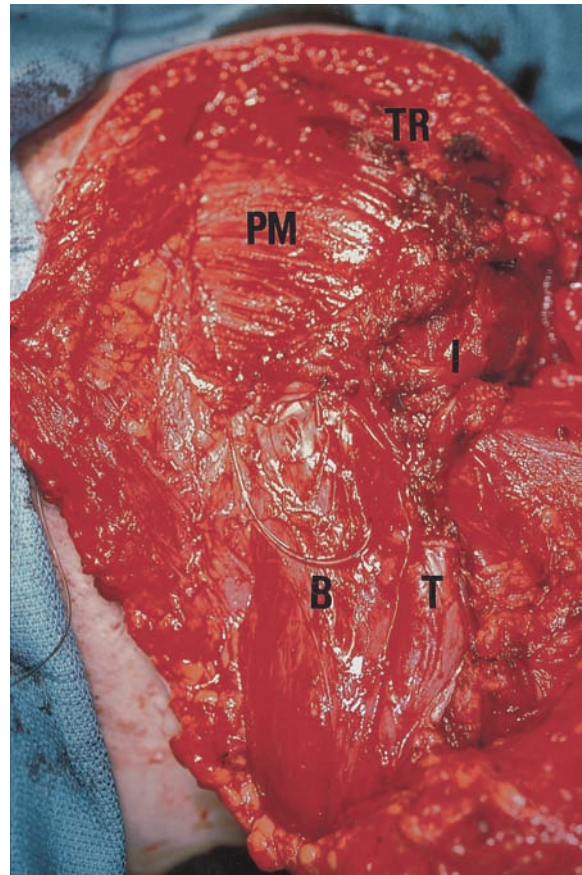


Figure 37-28 Operative photograph showing a completed reconstruction following an extraarticular reconstruction. The prosthesis is covered by muscle. The pectoralis major is the main muscle in the reconstruction and is sutured to the osteotomized scapula. The biceps and triceps are tenodesed to themselves and to the pectoralis major. The remaining musculature of the rotator cuff is tenodesed to the pectoralis major. The trapezius muscle is mobilized and brought down and sutured to the pectoralis major. Intraoperative photograph of completed reconstruction of the proximal humerus. B = biceps; I = infraspinatus; PM = pectoralis major; T = triceps; TR = trapezius.

TECHNIQUE OF RECONSTRUCTION WITH TOTAL HUMERAL ENDOPROSTHETIC REPLACEMENT

The senior author recommends total humeral endoprosthetic reconstruction utilizing an MRS with a custom elbow component.

- Use one of the several elbow devices available. An intramedullary stem fixation with PMMA is widely preferred.
- Reattach the forearm flexor and extensor muscles to holes in the prosthesis.
- Transpose the ulnar nerve anteriorly to avoid irritation from the prosthesis. Repair the biceps to the adjacent soft tissue.
- Take care to interpose the capsule between the prosthesis and the neurovascular structures anteriorly.

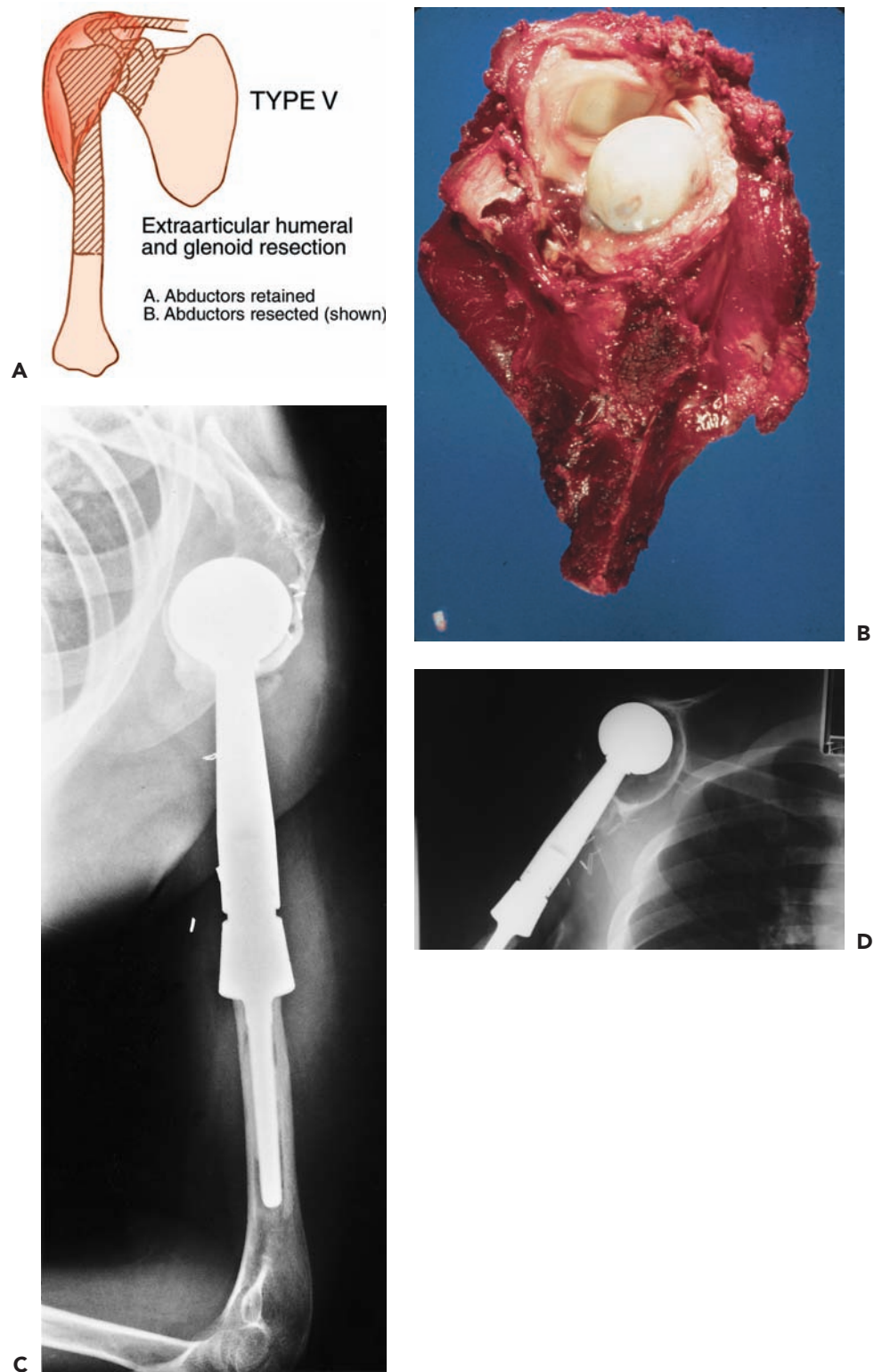


Figure 37-29 (A) Schematic of type V resection. This is the most common type of resection for high-grade sarcomas of the proximal humerus. (From Malawer M, Wittig JC. Resections of the shoulder girdle. In: Malawer MM, Sugarbaker PH, eds. *Musculoskeletal cancer surgery: treatment of sarcomas and allied diseases*. Dordrecht, Netherlands: Kluwer Academic Publishers, 2001:186.) (B) Gross specimen following an extraarticular resection. Note that the glenohumeral joint has been opened. (C) Plain radiograph following an extraarticular resection approximately 5 years postoperatively. Note the new (pseudo) glenoid bone formation around the humeral head. This is a typical finding. (D) Plain radiograph following a type VB proximal humeral resection and reconstruction with a modular segmental prosthesis. Note that the prosthesis is placed anterior to the scapula (see reconstructive technique). This is a typical resection for high-grade sarcomas of the proximal humerus. OR Plain radiograph at 5 years follow-up showing metaplastic bone forming a new glenoid. This is a common finding.

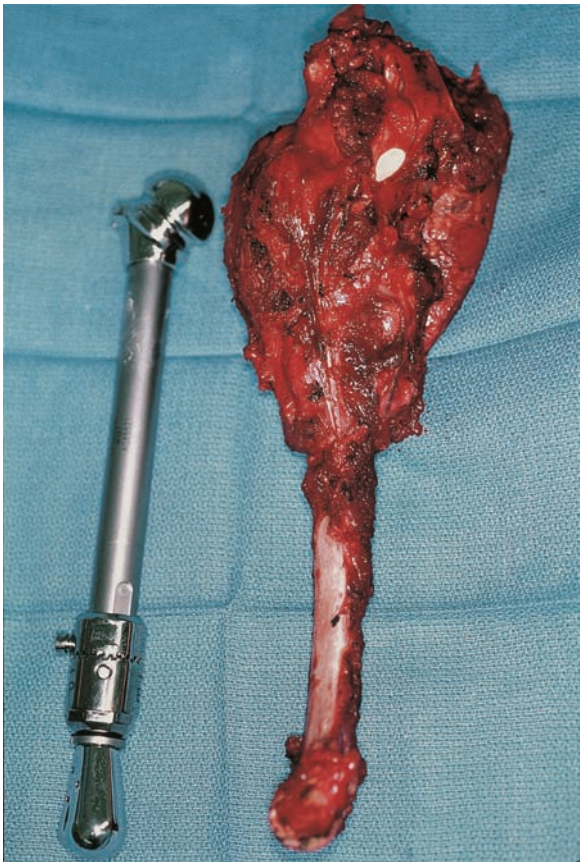


Figure 37-30 Total humeral resection for a large osteosarcoma with intramedullary extension.

Experience with total humeral prostheses is limited, but the duration of these prostheses is reliable. The most critical considerations following total humeral replacement are the potential for arterial thrombosis and occlusion, nerve compression, or neurapraxia.

Rehabilitation

A sling or plaster splint must be worn longer following these procedures than following proximal humeral resections. This is because of the need to allow for soft tissue healing around the elbow and the shoulder girdle. Elevation is required for the first 72 hours. Rehabilitation must focus on both the shoulder and the elbow joints. Fortunately, it is possible to preserve most of the musculature of the shoulder girdle, which allows for an extremely stable shoulder girdle as well as preservation of most of the elbow musculature.

TUMORS OF THE SCAPULA AND PERISCAPULAR AREA

Clinical Characteristics

Tumors of the scapula present with pain, a mass, or both, and they may become quite large before they are brought

to the surgeon's attention. Chondrosarcoma is the most common primary malignancy of the scapula. Secondary chondrosarcomas occur from an underlying osteochondroma, but fewer than 2% of osteosarcomas arise from the scapula. In children, the most common malignant scapular tumor is Ewing's sarcoma. Soft tissue sarcomas may involve the suprascapular or the infraspinous musculature and, secondarily, the scapula. Most soft tissue sarcomas of the scapular region occur in adults. In very rare cases, radiation sarcomas of the scapula develop secondary to radiotherapy for breast carcinoma.

Among the unique anatomic considerations associated with this area is that during the early stages of development, a cuff of soft tissue surrounds tumors arising within the scapula. As sarcomas enlarge, they may develop a large axillary component and invade the axillary vessels and brachial plexus. Tumors arising from the neck or glenoid usually involve the periscapular tissue and the glenohumeral joint; this is especially true of chondrosarcomas, osteosarcomas, and Ewing's sarcomas. Important anatomic areas to evaluate for extension are the chest wall, axillary vessels, proximal humeral and periscapular tissues, and rotator cuff. The axillary lymph nodes should be carefully examined, even though they are usually negative. Large suprascapular tumors extend into the anterior and posterior triangles of the neck, making resection difficult or contraindicated, except for palliation.

It is usually possible to satisfactorily treat soft tissue sarcomas arising in the periscapular musculature by removing the adjacent tissue en bloc while preserving the scapula, then following with radiotherapy. Occasionally, a soft tissue sarcoma arising from the deeper structures will involve or encase the scapula, requiring combined scapular resection. If the tumor is distal to the scapular spine, a partial (type IIB) or total (type IIIB) scapulectomy may be adequate. Involvement of the suprascapular musculature or rotators requires an extraarticular resection (type IV).

Specific Tumors of the Scapula

Certain tumors of the scapula and periscapular area require special management (Fig. 37-31). Chondrosarcomas, for example, commonly arise from the scapula; for this reason, any large cartilaginous lesion of the scapula in an adult should be approached with a high index of suspicion. These lesions tend to be low grade and have a large extraosseous component. Cartilage tumors approaching the glenohumeral joint may directly involve the joint space and readily implant on the articular cartilage. In such cases, an extraarticular resection is generally recommended, with no attempt to perform an intraarticular resection. A Tikhoff-Linberg resection (type IV) usually is curative.

Osteosarcomas, of which about 1.5% occur in the scapula, require a limb-sparing resection (type IV) or a forequarter amputation. The limiting factors in performing a limb-sparing procedure are the size and extent of the

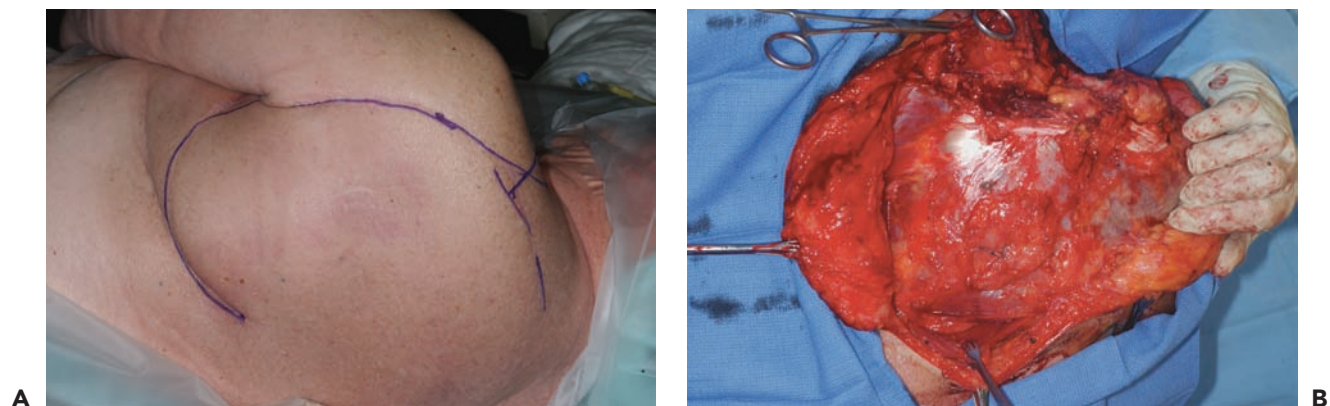


Figure 37-31 (A) A large periscapular tumor involving the body of the scapula. A long curvilinear incision is utilized to develop a posterior fasciocutaneous flap to expose the scapula, chest wall, and the supraclavicular area. (B) Intraoperative view following fasciocutaneous flap development. A large scapular mass is seen involving the teres and infraspinatus muscles.

extraosseous component. Neurovascular involvement requires a forequarter amputation. Chest wall involvement should be determined before surgery; if present, a partial chest wall resection en bloc with ablation of the primary tumor is necessary.

The traditional treatment for Ewing's sarcoma arising in the scapula has been radiation therapy and chemotherapy, and it has produced excellent functional results. However, the treatment of Ewing's sarcoma is undergoing reevaluation. Recently, total scapulectomy (type IIIA or B), with or without prosthetic replacement, has been recommended in lieu of radiation therapy. Surgery has become increasingly common with the hope of increasing local control, decreasing the morbidity of radiation (especially of late secondary osteosarcomas), and increasing patient survival. The surgery should be planned after induction chemotherapy. Staging should be done in the same manner as in patients with other high-grade sarcomas.

GCTs and ABCs often cause marked ballooning and destruction of the scapula. Small lesions may be treated by intralesional curettage. If the neck of the scapula is not involved, it is possible to perform a partial scapulectomy with minimal loss of function. Large lesions should be treated with total scapulectomy (type IIIA) while preserving most adjacent muscles. Reconstruction involves suspending the scapula from the clavicle by a static and dynamic reconstruction. This is an excellent indication for scapular prostheses, which have recently been developed.

TECHNIQUE OF TIKHOFF-LINBERG (TYPE IVB) RESECTIONS

The Tikhoff-Linberg procedure (extraarticular total scapular proximal humeral resection, type IV) consists of en bloc removal of the scapula, distal clavicle, and proximal humerus and preservation of the arm. The Tikhoff-Linberg

procedure was the first true limb-sparing procedure of the upper extremity. The original description was published in English in 1928 and was performed for periscapular soft tissue sarcomas.² Today, the indications for this procedure are low- and high-grade scapular (bony) sarcomas and periscapular and suprascapular soft tissue sarcomas (Fig. 37-32).

Careful preoperative evaluation is imperative. CT and MRI can help determine possible chest wall involvement, and angiography is crucial to determine axillary vessel involvement (Fig. 37-33). Contraindications to the Tikhoff-Linberg procedure are involvement by the tumor of the neurovascular bundle and of the chest wall, both of which require forequarter amputation.

It is important to carefully evaluate the interval between the tumor and vessels; this may require surgical exploration prior to resection. If this interval is clear, the resection may proceed. The surgical team must be prepared to convert from a limb-sparing procedure to a forequarter amputation should the tumor be found to involve the neurovascular bundle. The most medial margin, the paraspinal muscles, and the base of the neck must be explored if there is any possibility of their involvement. It is difficult to evaluate these anatomic areas thoroughly from preoperative studies alone.

Resection includes all the muscles arising from the scapula and inserting on the proximal humerus and an extraarticular excision of the glenohumeral joint. Occasionally, it is possible to preserve the deltoid muscle and the axillary nerve. The deltoid should be preserved whenever possible because it facilitates reconstruction, and soft tissue reconstruction is essential for a stable shoulder.

The surgical guidelines are as follows:

- The utilitarian incision is used, utilizing a combined anterior and posterior approach. The anterior incision is used to explore the axillary vessels, brachial plexus, and axilla.

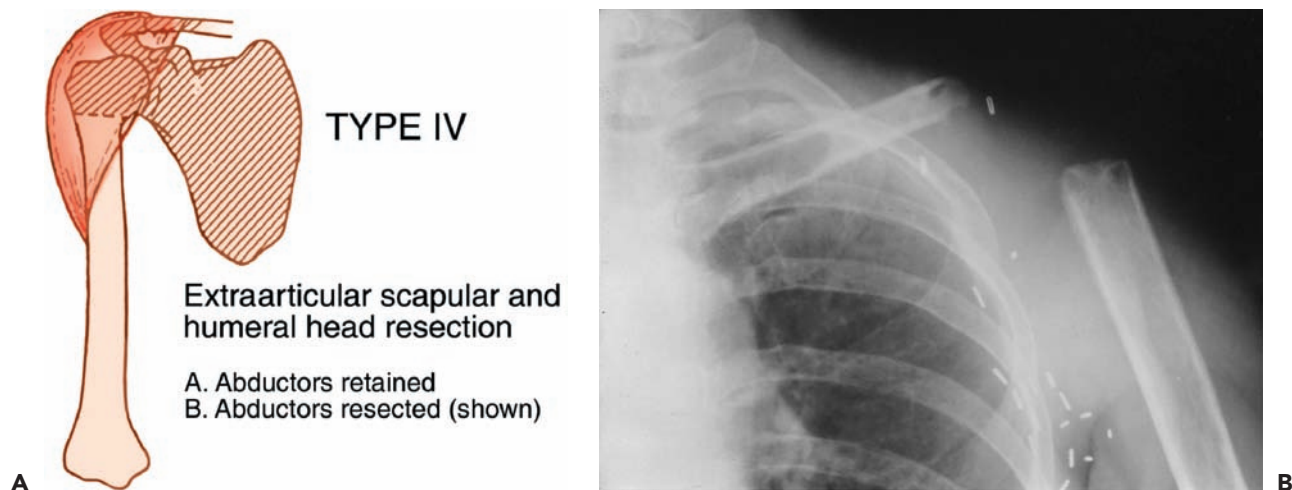


Figure 37-32 (A) Type IVB extraarticular scapula and humeral head resection. This is the original type of shoulder-girdle resection as described by Tikhoff and Linberg (see text). The Tikhoff-Linberg resection was the first limb-sparing surgical procedure performed around the shoulder girdle. Resection included the scapula, distal end of the clavicle, and the proximal humerus. Classically, the proximal humerus was suspended from the clavicle by the remaining muscles and/or heavy sutures. (From Malawer M, Wittig JC. Resections of the shoulder girdle. In: Malawer MM, Sugarbaker PH, eds. *Musculoskeletal cancer surgery: treatment of sarcomas and allied diseases*. Dordrecht, Netherlands: Kluwer Academic Publishers, 2001:190.) (B) Radiograph following a type IVB resection with soft tissue reconstruction only. Today, we would utilize a scapular prosthesis if the necessary musculature had been retained (see text).

- The pectoralis major muscle is released from the humerus. The pectoralis minor and conjoin tendon are released to permit exposure of the neurovascular structures.
- The glenohumeral joint is exposed anteriorly. The circumflex vessels as well as the axillary nerve are ligated. The joint covered by the subscapularis muscle is not opened.
- The axillary vessels and the brachial plexus are explored and gently retracted anteriorly. The pectoralis major has previously been detached and reflected toward the chest wall for adequate visualization of these structures.
- The posterior portion of the incision allows the release of all muscles that attach the scapula. The rhomboids, trapezius, and levator scapulae muscles are transected. The scapula is then lifted from the chest wall, which permits release of the serratus anterior muscle. It is important to palpate this interval early to determine any chest wall involvement by tumor.
- The glenohumeral joint is removed in an extraarticular manner through the anterior and posterior incisions. The osteotomy is performed below the level of the joint capsule.

To achieve both static and dynamic support, suspension of the proximal humerus is obtained by suturing of the remaining clavicle with Dacron tape (Genzyme Surgical Product Co., Fall River, MA) and muscle transfers. The long and short heads of the biceps and coracobrachialis are sutured through drill holes to the remaining clavicle, and the pectoralis muscle is rotated to cover the defect and to provide stability (Figs. 37-34 and 37-35).

In general, functional results are the same as those following a Tikhoff-Linberg resection (type IVB) and total scapulectomy (type IIIA/B). Patients retain hand function and good elbow function. The shoulder should be stable and no external orthosis should be required. A molded shoulder pad improves cosmesis (Fig. 37-36).

TECHNIQUE OF TOTAL SCAPULECTOMY

Total scapulectomy (intraarticular scapular resection, type III A or B) is indicated primarily for low-grade sarcomas (stage IA/B) of the body of the scapula that involve the suprascapular area, low-grade sarcomas of the glenoid, and soft tissue sarcomas that involve the scapula. Preoperative considerations are similar to those for a Tikhoff-Linberg resection. The neurovascular structures and chest wall must be free of disease. If the tumor extends anteriorly or laterally and involves the rotator cuff or the glenoid, an extraarticular resection (type IVB) should be performed. The skin flaps are similar to those obtained from the posterior limb during a Tikhoff-Linberg resection.

Other guidelines for total scapulectomy are as follows:

- Utilize two incisions: anterior and posterior portions of the utilitarian incision. The anterior incision is used to mobilize the axillary vessels and nerves, especially if there is a large anterior component arising from the scapula. The posterior incision permits exposure of the scapula, rhomboids, latissimus dorsi, and teres muscles.

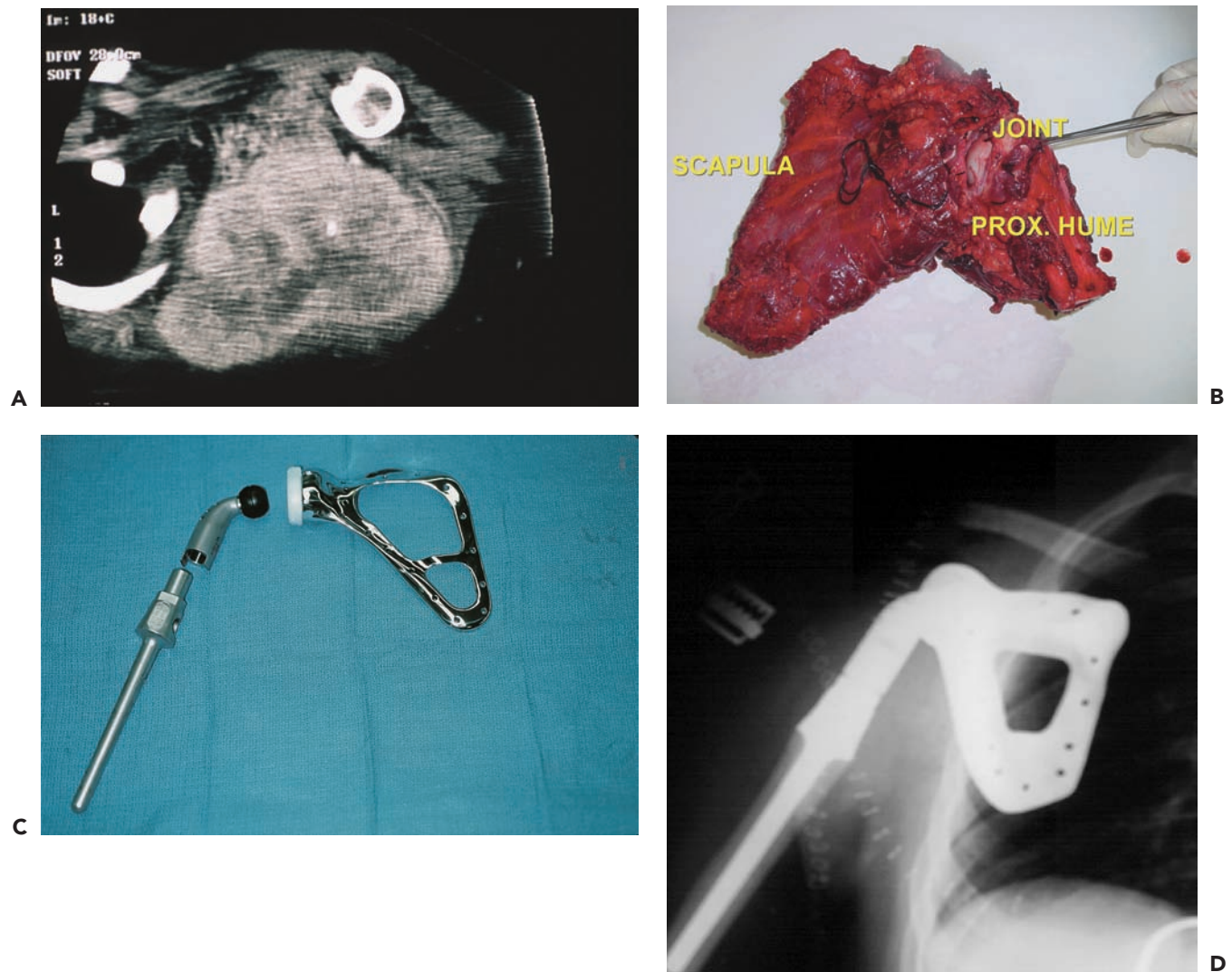


Figure 37-33 (A) Computed tomography scan showing a large tumor of the scapula, which is filling the axillary space and involves the proximal humerus. (B) Gross specimen following resection of the scapula and proximal one-third of the humerus. This is an extended Tikhoff-Linberg resection (type IVB). (C,D) Modular proximal humeral prosthesis and snap fit scapular component (Stryker Orthopedics, Mahwah, NJ).

TYPES OF SCAPULAR RECONSTRUCTION

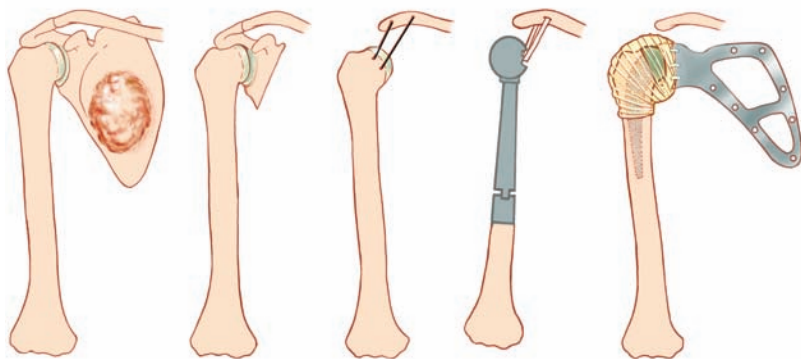


Figure 37-34 Types of scapular reconstruction. The authors prefer the use of a scapular prosthesis if the criteria (see text) can be met in lieu of a flail or hanging shoulder.

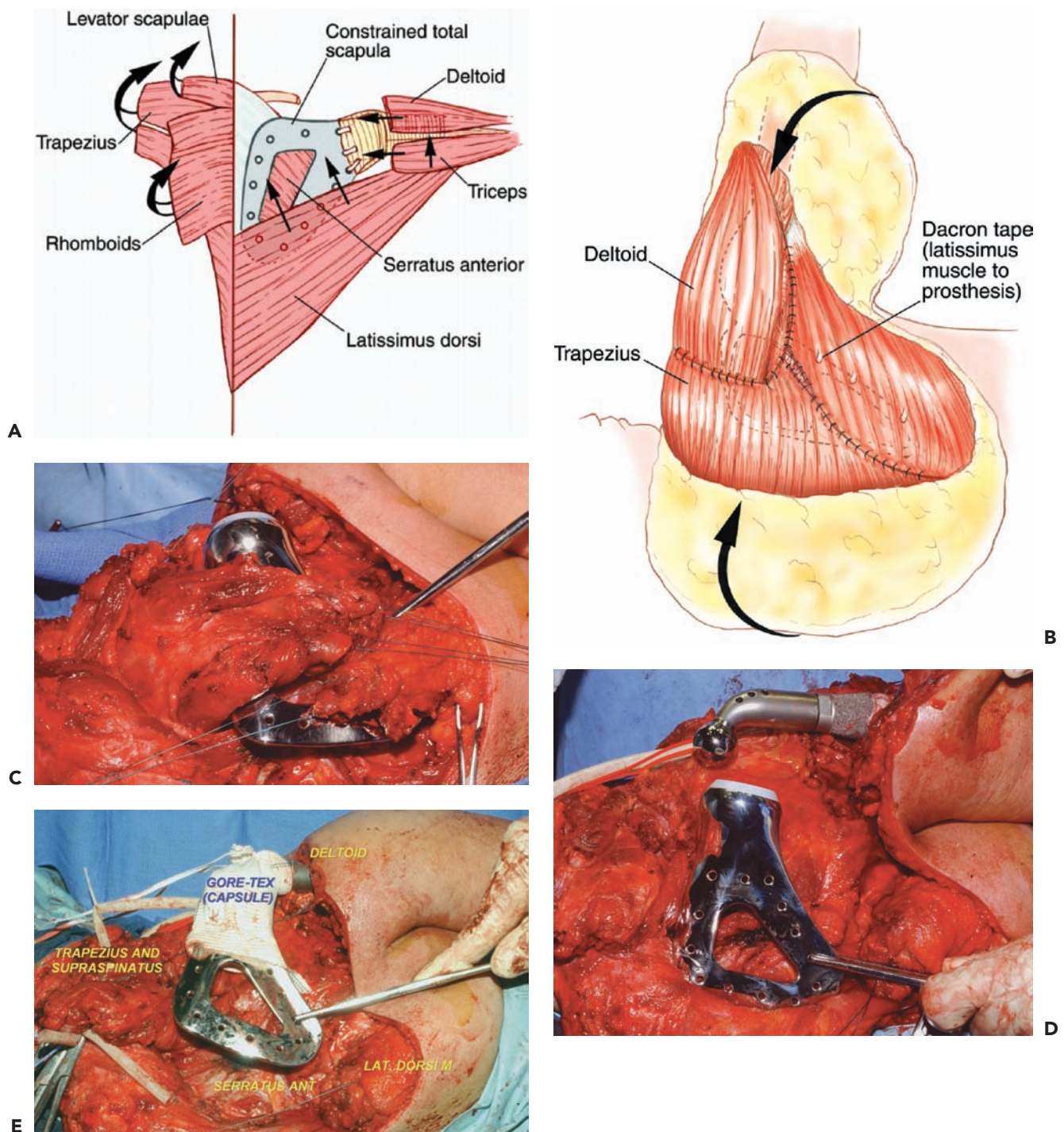


Figure 37-35 (A) Schematic of muscle transfers for a scapular endoprosthesis and proximal humeral component. (From Wittig JC, Bickels J, Wodajo FM, Kellar-Graney KL, Malawer MM. Constrained total scapula reconstruction after resection of a high-grade sarcoma. *Clin Orthop* 2002;397:143–155.) (B) Schematic muscular reconstruction required for shoulder-girdle endoprosthesis. The deltoid and trapezius must be retained to cover the prosthesis superiorly. The inferior portion of the body of the prosthesis is covered by the rhomboids and the latissimus dorsi. In general, the rhomboids and the latissimus muscles are often retained following type IVB resection. The major determinant of the use of a scapular prosthesis is the preservation of the deltoid and trapezius muscles. (From Malawer MM, Wittig JC, Rubert CK. Scapulectomy. In: Malawer MM, Sugarbaker PH, eds. *Musculoskeletal cancer surgery: treatment of sarcomas and allied diseases*. Dordrecht, Netherlands: Kluwer Academic Publishers, 2001:568.) (C) Intraoperative photograph of muscle reconstruction over a scapular endoprosthesis (see text). (D,E) Intraoperative photographs showing Gore-Tex graft reconstruction.

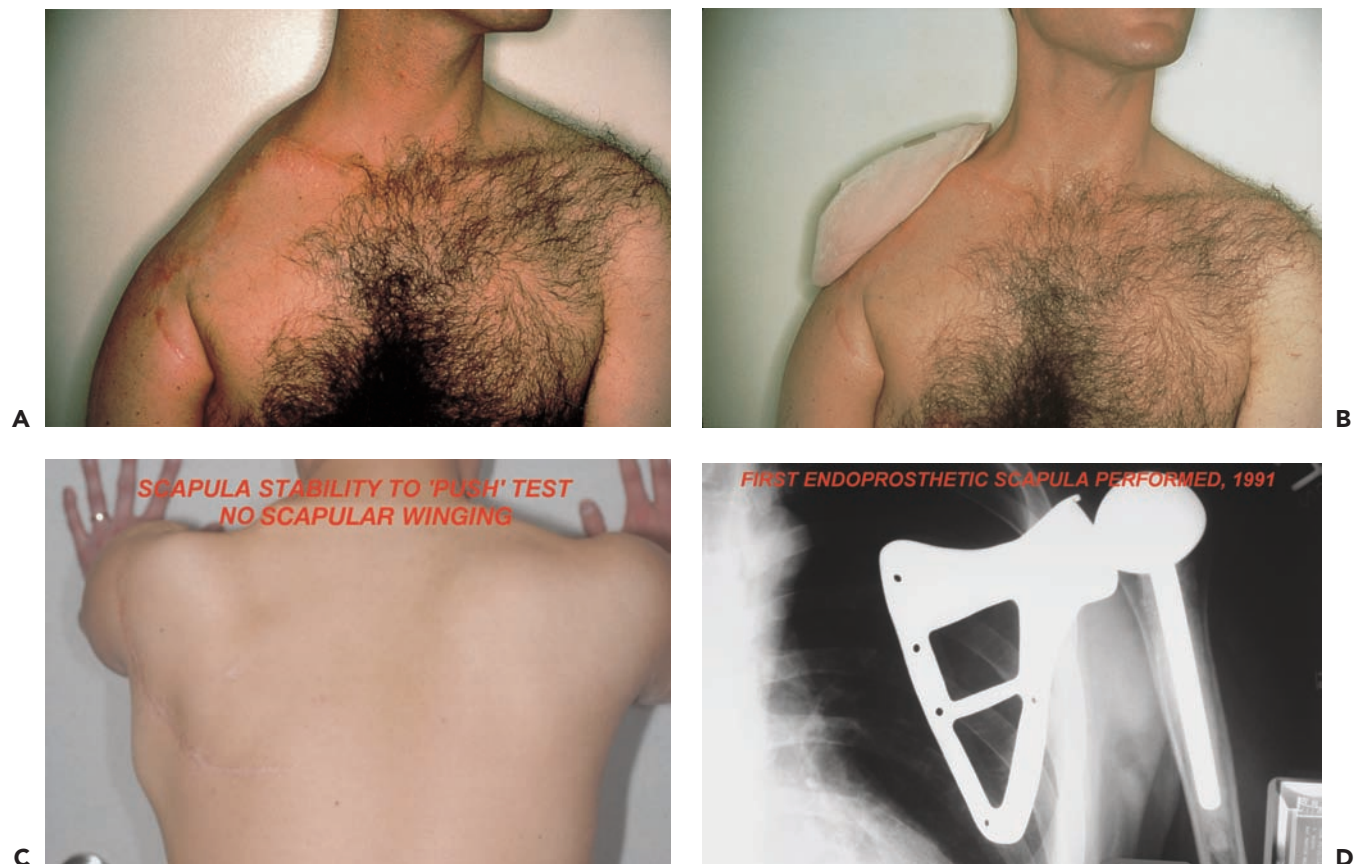

Figure 37-36 Cosmetic appearance following a Tikhoff-Linberg resection. (A) Typical clinical appearance. (B) Cosmesis is achieved by a contoured shoulder pad. (C) Cosmesis following scapular reconstruction with an endoprosthesis. (D) Plain radiograph showing a scapula and glenohumeral replacement. Gore-Tex is utilized to recreate the shoulder joint and reattach the humerus to the scapular neck.

- Transect all muscles away from the bone, starting at the lowest point inferiorly.
- Approach the neurovascular structures from the back, as the scapula is retracted away from the chest in a cephalad direction. Take care to avoid injuring the musculocutaneous and axillary nerves near the coracoid and around the subscapularis muscle.
- Be prepared to convert this approach (type III) to a Tikhoff-Linberg resection (type IVB) if the anterior or medial margins are questionable.

Soft tissue reconstruction is mandatory to provide stability and to avoid a flail extremity. Employ a dual-suspension technique using Dacron tape from the clavicle for static support and reattaching the biceps and triceps muscles through drill holes. Tenodesing the deltoid to the pectoralis major and trapezius muscles is essential to provide stability.

The functional results are similar to those with a standard Tikhoff-Linberg resection. If significant soft tissue remains, this defect occasionally can be reconstructed with a total scapula prosthesis. The important muscles for this purpose are the latissimus dorsi, rhomboids, and trapezius.

TECHNIQUE OF PARTIAL SCAPULECTOMY

A partial scapulectomy is indicated for low-grade or benign lesions involving only the body of the scapula. It preserves a cuff of infraspinatus, subscapularis, and serratus anterior muscle. Reconstruction consists of suturing together these muscles to close the dead space and reconstituting the points of origin and insertion of these muscles. A sling is required for 5 to 7 days.

Functional loss after a partial scapular resection (type II) is minimal; in fact, shoulder motion and strength are nearly normal. Total scapular resection (type IIIA/B) causes a significant loss of shoulder motion, but elbow and hand function are normal. The major limitation is the loss of shoulder abduction. Shoulder-girdle function is similar to that following total scapular resection and a Tikhoff-Linberg resection (type VB).

Soft tissue reconstruction is the key to establishing shoulder stability. A compressive arm stocking should be worn immediately after surgery to prevent swelling. The patient should be encouraged to flex the elbow but to

avoid extension until the wound has healed. The patient must wear a sling for 2 to 4 weeks, by which time the transferred muscles provide a stabilizing force to the entire upper extremity. Forward and backward flexion of approximately 30 to 45 degrees is obtained. The goal of rehabilitation is to strengthen the transferred pectoralis major, latissimus dorsi, and trapezius muscles around the shoulder as well as the elbow flexors. A shoulder pad contributes to cosmesis and restores symmetry.

TECHNIQUE OF SCAPULA ENDOPROTHETIC RECONSTRUCTION

Experience with total scapular replacement, although still limited, is increasing. If most of the musculature is retained (type IIIA), it usually is possible to reconstruct the defect with a custom scapular prosthesis. The most common indications for this procedure are large (stage III) GCTs, low-grade chondrosarcomas, and Ewing's sarcomas following induction chemotherapy. Successful reconstruction poses three primary challenges: (a) replacing the humeral joint, (b) stabilizing the scapula prosthesis within the humeral component (i.e., creating a new glenohumeral joint), and (c) providing soft tissue attachments to both the scapular and humeral components to ensure stability as well as active motion.

Types of Prostheses (Fig. 37-37)

A custom prosthesis is utilized for reconstruction of the scapula. The design features of these prostheses are summarized below:

- Nonconstrained or semiconstrained design (first- and second-generation prostheses)
- Holes along the periphery of the prosthetic scapular body for reattachment of the scapular stabilizing muscles (levator scapulae, rhomboids, and trapezius)
- Holes along the base of the prosthetic scapular neck for capsular reconstruction with Gore-Tex graft
- The body of the scapula is open to permit adjacent muscle tenodesis.
- No attempt is made to recreate the coracoid, acromion, or scapula spine. These structures would create wound complications and closure difficulties.

Technique of Constrained Total Scapula Endoprosthesis Reconstruction

The technique, surgical anatomy, and indications and results of the constrained scapula prosthesis are as follows:

- Tenodes the scapula prosthesis to the remaining trapezius, rhomboids, and latissimus dorsi muscles.
- Place the prosthesis in a pocket between the rhomboids and serratus anterior.
- Use Dacron tapes to tenodes the prosthesis to these muscles. Tenodes the trapezius to the prosthesis and to the deltoid muscle.
- Rotate the latissimus dorsi to cover the prosthesis in entirety with soft tissues.
- Suture a Gore-Tex graft over the proximal humeral component before snapping it into the glenoid for additional stability.
- Reconstruct the glenohumeral joint by sewing an aorta Gore-Tex (W.L. Gore & Associates, Flagstaff, AZ) graft over the scapula neck and the proximal humerus. This

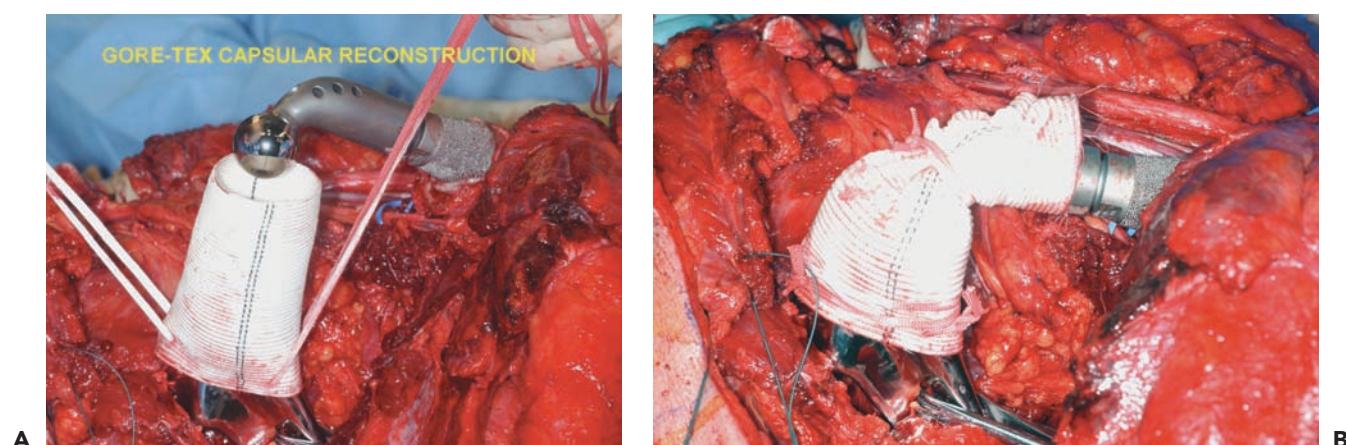


Figure 37-37 Gore-Tex reconstruction in conjunction with a bipolar snap fit head. **(A)** Reconstruction with Gore-Tex graft of a new capsule. Gore-Tex is initially sewn to the neck of the scapula. **(B)** Prosthesis is reduced into the glenoid. Note that the Gore-Tex graft has been placed proximally around the glenoid and scapular component. The Gore-Tex is brought over the proximal humeral component and sutured into place with 3-mm Dacron tape. Completion of the capsular reconstruction is achieved with the Gore-Tex graft. The rhomboid muscles and latissimus dorsi are then closed over the body of the prosthesis.

1192 Part VIII: Neoplasia and Infection

permits stabilization of the joint and provides additional stability.

- Reattach and tenodeses the remaining rhomboids, latissimus dorsi, and teres muscle to the prosthesis and to themselves to achieve reliable and functional soft tissue reconstruction.
- Advance the preserved deltoid proximally and suture it to the trapezius; then close the pectoralis major muscle anteriorly over the new joint.

Wittig et al.⁴ reported no infections or local recurrence and superior cosmesis when compared to the traditional Tikhoff-Linberg procedure. It was emphasized that it is essential to retain the deltoid, trapezius muscles, and axillary nerve. All patients had a stable shoulder and good to excellent hand and elbow function, thus providing a functional extremity. Most patients had good forward flexion, abduction, and external and internal rotation. Elevation, protraction, and retraction of the shoulder were preserved.

Wodajo et al.⁵ reported a retrospective comparison of patients undergoing scapular resection and reconstruction with and without an endoprosthesis. Patients with endoprosthetic reconstruction had higher Musculoskeletal Tumor Society (MSTS) scores than did patients with no endoprosthesis (86% and 62%, respectively). The former group also had a larger arc of abduction than the latter (60% to 90% and 10% to 20%, respectively) and improved cosmesis. Most bony sarcomas of the scapula are contained by the two surrounding muscles, the infraspinatus posteriorly, and the subscapularis muscle anteriorly and do not involve the deltoid and trapezius muscles. Therefore, most tumors of the scapula, irrespective of size, are amenable to endoprosthetic replacement.

AXILLARY TUMORS

Overview

Several types of malignant tumors may involve the axillary space and may require surgical resection. Primary sarcomas occur within the muscles (i.e., the pectoralis major, latissimus dorsi, teres major, and subscapularis) that make up the borders of the axillary space and rarely within the axillary fat itself. Large metastatic deposits to the regional lymph nodes occasionally create large, matted masses that may require resection. The most common are metastatic melanoma and recurrent breast carcinoma. In addition, certain primary tumors arise from the brachial plexus, either the nerves or the vessels. These include leiomyosarcomas of the axillary vein and neurofibrosarcomas of the adjacent nerves. Secondary extraosseous extension from large tumors of the proximal humerus or scapula often goes into the axillary space and require imaging evaluation and surgical resection. Tumor involvement of the brachial plexus and the major vessels is the main determinant of resectability (Fig. 37-38).

The key to adequate and safe surgical resection of axillary tumors is the complete visualization and mobilization of the infraclavicular portion of the brachial plexus (i.e., the axillary artery and vein and the cords that surround them). Multiple imaging studies are required, but the final decision to proceed with a limb-sparing surgery is made during intraoperative exploration of the axillary space. Gross tumor involvement of the brachial plexus and/or the major vessels is an indication for amputation or for abandoning the attempt for resection. Contraindications to axillary space resection include involvement of the neurovascular bundle and of the adjacent chest wall.

The technique of axillary space exploration via the transpectoralis approach, as described here, has been developed by the authors and has been found to be the most useful in this determination and in the surgical approach.

Unique Anatomic Considerations

Anatomic Borders

The axilla is a pyramid-shaped space between the chest wall and the arm. The apex of the pyramid is formed by the junction of the clavicle and the first rib. The superior border is determined by the scapula. This apex is approximately 1 to 2 cm medial to the coracoid process. The anterior wall of the axilla is formed by the pectoralis major muscle, and the posterior wall is formed by the subscapularis, the teres major, and the latissimus dorsi muscles. The chest wall and the serratus anterior muscle form the medial wall of the triangle. The humeral shaft is covered by the muscle fibers of the coracobrachialis, and the short head of the biceps defines the lateral wall. The axilla is triangular shaped from both the coronal and axial views.

The most significant structures of the axillary space are the axillary artery and vein, which are surrounded by the cords of the brachial plexus as they enter from the apex and pass through the axillary space medial to the coracoid to the medial aspect along the humeral shaft. This space is filled with a fair amount of fat and lymph nodes that follow the axillary vessels. The space is bounded anteriorly by the deep clavicular pectoralis fascia that arises from the clavicle and covers the deep fat below the pectoralis major muscle. Inferiorly, the fascia wraps around the base of the axilla. Identification of this layer is extremely important prior to entering the deeper structures.

Pectoralis Major and Conjoined Tendon Muscles

Two major muscles form the gateway to the axillary space. Lying just below the clavicular-pectoralis fascia, they are the pectoralis minor muscle, which arises from the chest wall and attaches to the coracoid, and the conjoined tendon, which arises from the coracobrachialis and short

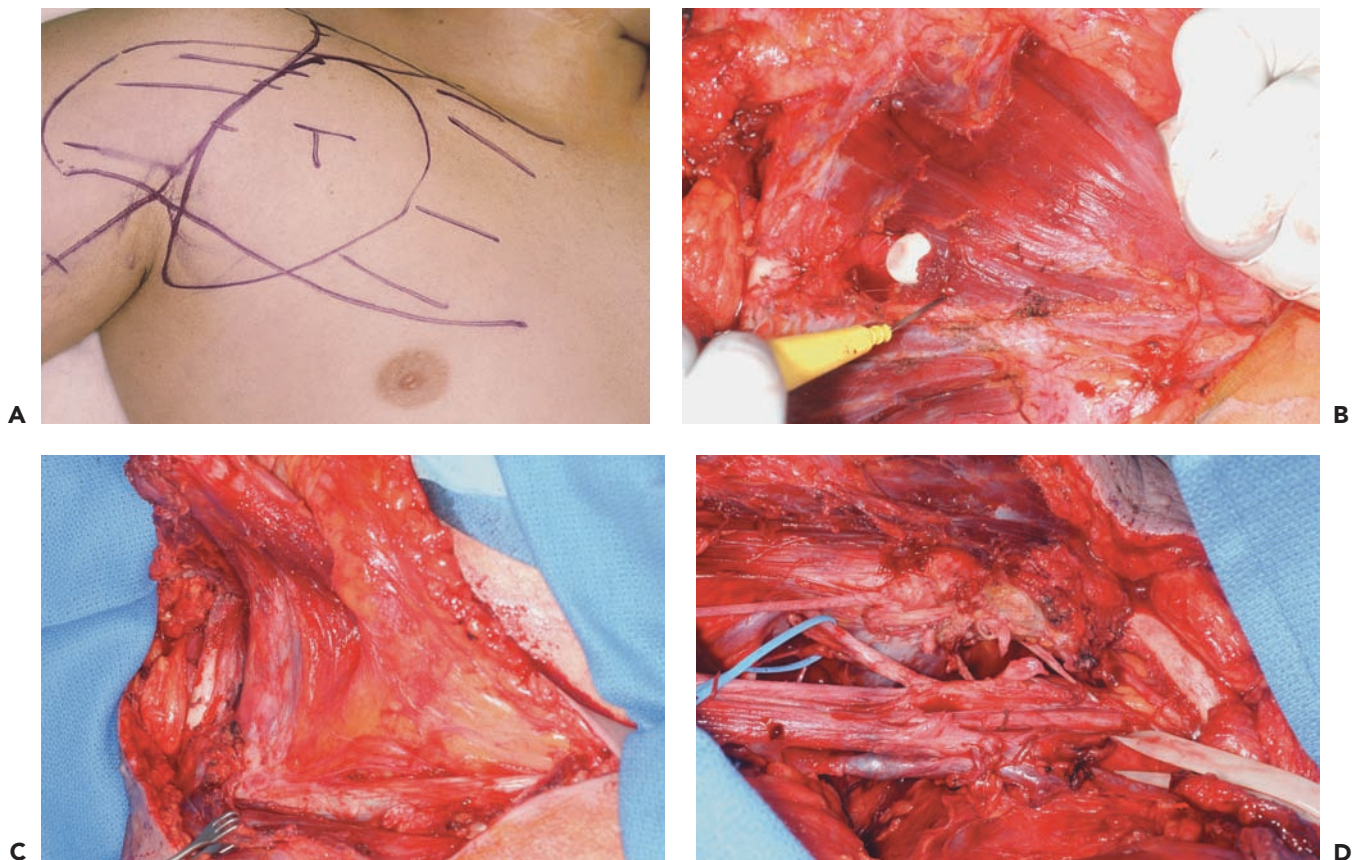


Figure 37-38 Axillary tumor. **(A)** Clinical photograph of a large axillary tumor and its relationship to the pectoralis major muscle. The initial step in the axillary exposure is release of the pectoralis major muscle. **(B)** Intraoperative view of release of the pectoralis major muscle, which provides access to the axilla. The pectoralis is released from the clavicle and its humeral insertion. Care is taken to protect the underlying vessels, which are often displaced anteriorly by a large axillary tumor. **(C)** The second layer of muscles and the axillary fascia are seen once the pectoralis major muscle is detached and rotated toward the chest wall. The second layer of muscle consists of the coracobrachialis and pectoralis minor by inserting on the coracoid. Surgically, both of these muscles are released prior to opening the axillary fascia. **(D)** Completion of exposure in the infraclavicular portion of the brachial plexus. The axillary nerve is within the vessel loop.

head of the biceps from the medial aspect of the humerus. These two muscles must be identified in the clavicular-pectoralis fascia during the surgery. Their identification is the key to accurate identification and dissection of all structures that are located deeper within the axillary fat.

Infraclavicular Brachial Plexus (see Fig. 37-38)

The infraclavicular portion of the brachial plexus is the most significant anatomic component; therefore, it must be thoroughly evaluated and its anatomy completely understood. The axillary artery and vein are contained within a single sheath and are surrounded by the cords of the infraclavicular plexus. The lateral, posterior, and medial cords of the plexus are found at the level of the pectoralis minor muscle. These cords occur in the sheath around the axillary artery and vein. At the lower border of the pectoralis minor muscle, these cords give rise to the five

major nerves of the extremity: median, ulnar, radial, musculocutaneous, and axillary nerves.

The lateral cord gives rise to the musculocutaneous nerve, which travels along the medial aspect of the conjoint tendon, moves into the muscle belly of the coracobrachialis, and then enters the short head of the biceps. This nerve is the first to be identified during the exploration. It is located in the superficial axillary fat inferior to the coracoid process. The posterior cord gives rise to the axillary nerve, which travels deep in the space and passes inferior to the glenohumeral joint and the subscapularis muscle. The axillary nerve innervates the deltoid muscle. The main portion of the posterior cord becomes the radial nerve, which travels posterior to the sheath and exits the axillary space along with the axillary sheath. The medial cord gives rise to the median nerve, which is found on the lateral aspect of the sheath and exits the inferior aspect of the axillary space along the sheath. The ulnar nerve arises from the median cord and travels along the most

medial aspect of the sheath and exits distally, along with the sheath. The ulnar nerve is the most common nerve to be involved by tumors arising inferior to the brachial plexus because of its medial position along the sheath. This nerve often displays the first symptom (i.e., weakness or neuro-pathic complaints) of brachial plexus involvement.

Axillary and Brachial Arteries

The axillary artery is a continuation of the subclavian artery as it passes below the clavicle and the first rib. As it exits the axillary space just distal to the take-off of the circumflex vessels, it is termed the brachial artery. This transition occurs anteriorly at the level of the inferior pectoralis major and teres major muscles. The axillary artery consists of three segments: (a) the portion between the clavicle and pectoralis minor, (b) the area under the pectoralis minor, and (c) the segment between the inferior lateral pectoralis minor border to the point of exit below the teres major muscle. Tumor involvement may occur secondary to lymph node metastases in any of these three locations. The most common sites for axillary sarcomas are the second and third segments. Metastatic carcinomas involving the axillary space can involve any of these areas; however, they most often present as large, matted tumor masses between areas two and three.

Radiographic Evaluation

Three-dimensional imaging of the axillary space is important for accurate tumor localization and surgical planning. CT, MRI, angiography, and three-phase bone scans are used in the same way as in other anatomic sites. In addition, venography of the axillary and brachial veins is essential to the evaluation of tumors of the axilla and brachial plexus.

Computed Tomography

CT is most useful in evaluating the bony walls of the axilla, specifically, the humerus, glenohumeral joint, and scapula. Soft tissue tumors are well defined by CT scans. CT scans with intravenous contrast will aid in the definition of the axillary vessels.

Magnetic Resonance Imaging

MRI is extremely useful in determining the extent of a soft tissue mass in the axillary space and the involvement of the underlying serratus anterior and/or the anterior and posterior walls of the axillary space (pectoralis major, subscapularis, latissimus dorsi, and teres major muscles).

Angiography

Angiography should be part of the evaluation of all tumors of the axillary space. This technique will demonstrate any

vascular displacement (very often inferior or anterior) and vascular anomalies of the axillary vessels. In addition, it can provide useful information on any response to induction chemotherapy (e.g., decrease in tumor vascularity).

Venography

Venography is one of the most accurate means of determining brachial plexus and axillary sheath involvement or infiltration by tumor. The arterial wall is thick and almost never shows signs of occlusion, whereas the axillary vein is a thin-walled structure that is easily compressed and infiltrated by tumor. Therefore, occlusion is almost synonymous with vascular sheath and brachial plexus involvement. A venogram should be routinely performed to evaluate the axillary vein. A positive venogram showing occlusion of the vein, in combination with neurologic pain and weakness, is almost always pathognomonic of axillary sheath and brachial plexus involvement by tumor. The triad of axillary vein occlusion, distal motor weakness, and neuro-pathic pain is a very reliable predictor of tumor infiltration of the brachial plexus sheath.

Biopsy

Biopsy of axillary tumors should be performed utilizing a needle or fine needle aspiration (FNA) technique. If a metastatic lesion is most likely, then FNA is the more appropriate means of identifying carcinoma cells. If a sarcoma is suspected, a needle or core biopsy should be performed. The biopsy site should be inferior through the base of the axillary space and not through the pectoralis major muscle or near the vascular sheath. This can easily be performed under CT guidance. The biopsy site must be removed in its entirety during resection of the tumor. Deep-seated lesions near the chest wall should be approached in this manner. Anterior lesions occasionally may be approached through the lower portion of the pectoralis major.

Surgical Management

Guidelines

1. Use of an anterior utilitarian incision with axillary extension. This incision extends along the deltopectoral interval with preservation of the cephalic vein. It then curves inferiorly and distally over the base of the axilla.
2. Detachment of the pectoralis major muscle. This muscle is detached from its insertion on the humerus and is reflected toward the chest wall while maintaining its vascular pedicles. This permits exposure of the entire axillary space and fascial sheaths.
3. Development of an anterior axillary fascial plane (claviculopectoralis fascia). This thick layer of fascia contains

the entire axillary space and structures. It is extremely well defined. This plane must be developed prior to any further dissection.

4. Release of the pectoralis minor and conjoin tendon. The pectoralis minor and conjoin tendon form the anterior muscle layer within the axillary space. Release of these muscles is key to exposure of the vascular sheath, the brachial plexus, and the numerous vascular branches feeding any large tumors.
5. Initial identification of the musculocutaneous and axillary nerves. The musculocutaneous nerve comes around the lower border of the coracoid under the pectoralis minor muscle. The axillary nerve comes off deeper from the posterior cord and travels toward the shoulder joint.
6. Mobilization of the axillary sheath and brachial plexus. Proximal and distal control of the vascular sheath is obtained prior to tumor dissection. Once the deep fascia is opened and the pectoralis minor muscle is released, the sheath is found very easily by palpating the axillary fat. Vessel loops are placed around the entire sheath; there is no need to dissect the individual components.
7. Resection of tumor. All the feeding branches entering into the mass are serially ligated and transected. Axillary fat is left around the tumor mass as the only true margin.
8. Closure. The pectoralis minor and conjoin tendon are reattached to the coracoid process.
9. Insertion of catheter. An epineural catheter is placed in the axillary sheath for postoperative pain relief.
10. Closure of the empty space. Often following resection, there is a large empty space that is prone to collect fluid and may lead to wound complications and dehiscence. The latissimus dorsi may be released from its insertion onto the humerus and inserted into the defect and sutured to the subscapularis muscle.
11. Suspension and adduction. The arm is suspended and kept adducted at the side of the body to close off this space. Multiple drains are used for 4 to 7 days.

Surgical Technique

- Place the patient in a supine semilateral position. Prepare and drape the arm, shoulder girdle, and chest. Full mobilization of the ipsilateral extremity is essential.
- Use a deltopectoral incision. This incision starts over the junction of the inner and middle thirds of the clavicle, continues along the deltopectoral groove, and curves distally over the anterior axillary fold (inferior border of the pectoralis major muscle).
- Open the superficial fascia, ligate or preserve the cephalic vein, and raise medial and lateral fasciocutaneous flaps.
- Detach the pectoralis major muscle from its insertion to the proximal humerus, leaving at least 1 cm of the tendon for reattachment. Take care to protect the axillary vessels. Large axillary tumors may displace the axillary

sheath anteriorly and adjacent to the pectoralis major muscle.

- Divide the short head of the biceps and coracobrachialis (conjoined tendon) and pectoralis minor muscles at their insertion on the coracoid process. Perform the reflection with caution to prevent traction injury to the musculocutaneous nerve, which pierces the substance of the coracobrachialis muscle.
- Detach the pectoralis minor and conjoined tendon. Expose the axillary cavity after detachment and reflection of the second layer of muscles. The coracoid insertion of the pectoralis minor and the coracobrachialis are detached and retracted. Reflect the pectoralis minor muscle medially and the conjoined tendon (coracobrachialis and biceps muscles) caudally. Tag all edges of reflected muscles with a suture for later identification and use in reconstruction.
- The deep axillary fascia, neurovascular bundle, and content of the axillary cavity are now fully exposed. The anatomic relation of the tumor to the neurovascular bundle can be determined and the decision regarding tumor resectability made. At this anatomic site, the artery, vein, and brachial plexus are in close relation, and tumor extension to the neurovascular bundle usually affects all its components and negates resection. Benign tumors and soft tissue sarcomas usually push the adjacent neurovascular bundle; only at a later stage do soft tissue sarcomas break into it. Metastatic carcinomas directly invade the surrounding tissues, irrespective of compartmental borders. For these reasons, resection of large metastases with preservation of the neurovascular bundle is occasionally not feasible. If resection is not feasible, dissect the neurovascular bundle off of the tumor mass, ligate the subscapular and thoracodorsal vessels, and perform hemostasis.
- Resect the tumor with wide margins.
- Reattach the conjoined tendon and pectoralis minor muscles.
- Reattach the pectoralis minor and conjoined tendons to the coracoid process with a nonabsorbable suture. Reattach the pectoralis major to its insertion site on the proximal humerus in the same manner.
- Close the wound over suction drains.

Following surgery, the upper extremity is kept in an arm sling. Continuous suction is required for 4 to 7 days. Perioperative intravenous antibiotics are continued until the drainage tubes are removed. Postoperative mobilization with gradual range of motion of the shoulder joint is then introduced.

CLAVICLE TUMORS

Sarcomas arising from the clavicle are exceedingly rare. ABCs are also rare but are one of the more common neoplasms to arise from the clavicle. Metastatic carcinomas

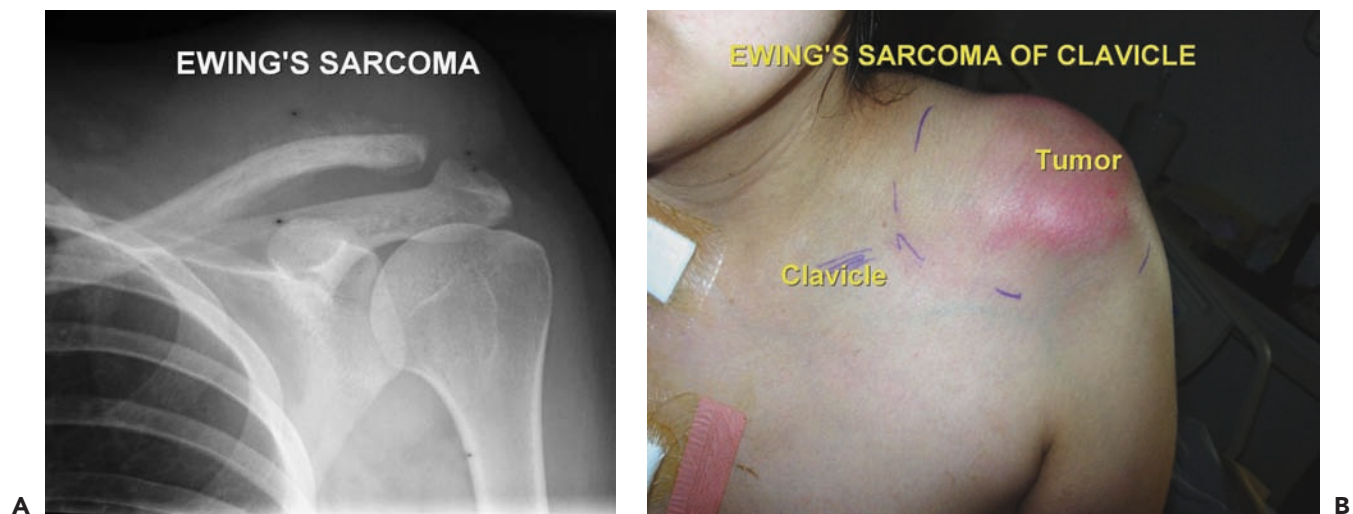


Figure 37-39 (A) Anteroposterior radiograph showing sclerosis and destruction of the distal clavicle as well as a large soft tissue mass with no evidence of matrix formation. (B) Clinical view of a large Ewing's sarcoma of the clavicle showing a large extraosseous soft tissue mass.

can affect the clavicle. Most can be treated with radiation, although surgical resection may occasionally be indicated for metastatic carcinomas that present with a large soft tissue component that encroaches on the brachial plexus. There is no replacement following radical resection of the clavicle. Most patients will be pain free and have full shoulder motion. The most common postoperative complaint is fatigue of the trapezius muscle (Fig. 37-39).

The key to safe resection of the clavicle is proper dissection and mobilization of the subclavian, axillary vessels and brachial plexus away from the tumor. Proximal expo-

ration and mobilization occur at the base of the neck; distally, the axillary vessels and brachial plexus are explored deep to the pectoralis major muscle and medial to the coracoid process (similar to the axillary approach). Once the pertinent neurovascular structures have been separated from the neoplasm, the clavicle can be resected. A modification of the utilitarian shoulder-girdle incision is used.

The resection proceeds as follows:

1. Extend the incision from the midsternocleidomastoid muscle past the sternoclavicular joint. It extends trans-

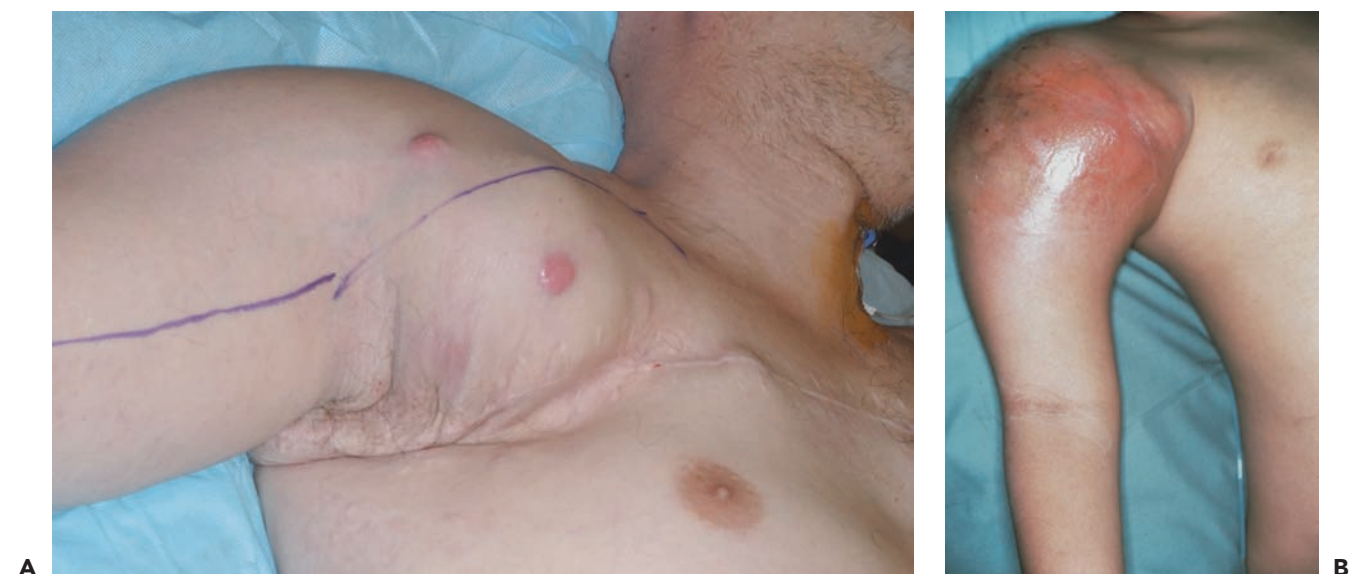

Figure 37-40 (A) Large recurrent chondrosarcoma of the shoulder girdle. (B) Large telangiectatic osteosarcoma of the proximal humerus. Both patients required forequarter amputation. Although amputation is less common today, approximately 5% to 10% of sarcomas of the proximal humerus or axilla are not candidates for limb-sparing surgery and require amputation.

versely across the chest at approximately the third rib level to the deltopectoral groove.

2. Raise a large subcutaneous flap to expose the clavicle, the anterior third of the deltoid, the sternoclavicular joint, and the posterior triangle of the neck.
3. Release the pectoralis major proximally from the clavicle, leaving a margin on the tumor. Transect the pectoralis minor tendon from its insertion on the coracoid. This exposes the axillary sheath. Open the sheath to expose the axillary vessels and brachial plexus.
4. Release the sternocleidomastoid muscle from its insertion and retract it proximally. The fascia overlying the posterior triangle of the neck is opened to expose the brachial plexus. Identify the internal jugular vein (which may be ligated) and carotid artery and dissect distally to the base of the neck, where the subclavian

vessels are identified. The subclavian vein, which is located anterior to the scalenus anticus muscle, is often compressed by tumor in this region and is difficult to visualize. The subclavian artery is posterior to the scalenus anticus muscle. Proximal and distal dissection ensures proper identification and a safe resection.

5. Once the subclavian vessels and brachial plexus have been mobilized, osteotomize the clavicle. It may be necessary to resect the sternoclavicular or acromioclavicular joint. Transect the subclavius and deltoid muscles and then remove the tumor.
6. Rotate the pectoralis major muscle proximally and suture it to the trapezius. Rotate the sternocleidomastoid muscle and attach it to the proximal border of the pectoralis muscle to cover the neurovascular structures with soft tissue.
7. Place drains and suture the skin flap in place.

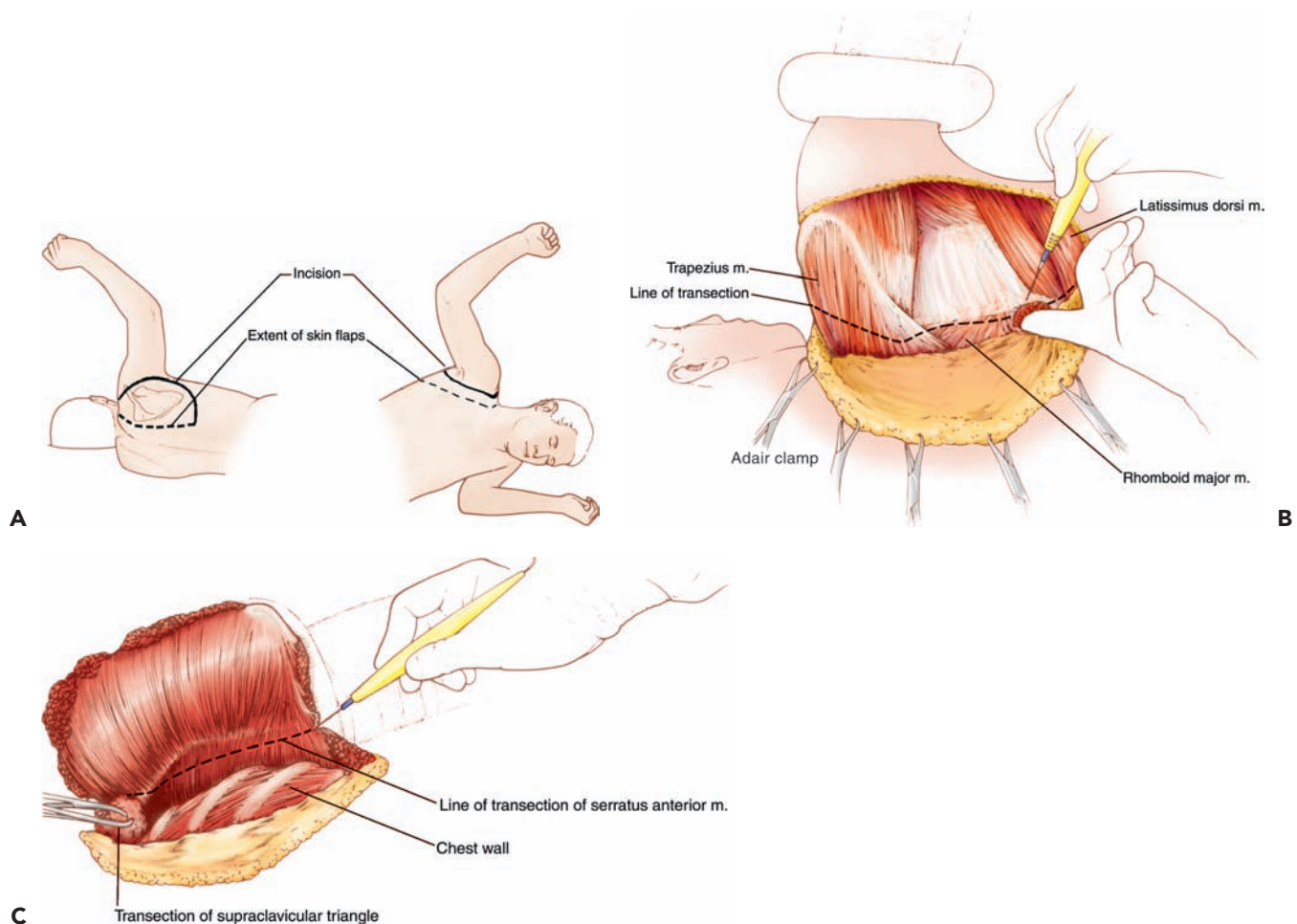


Figure 37-41 Technique of forequarter amputation. **(A)** Incision. **(B)** Release of periscapular muscles. **(C)** Mobilization of scapula and release of the anterior axillary muscles. **(D)** Isolation and ligation of the axillary vessels and brachial plexus. **(E)** Completion of amputation with posterior flap closure. Note that the surgical approach to a forequarter amputation may include initial exploration and ligation of axillary vessels from an anterior incision prior to the posterior approach (see text). (From Malawer M, Sugarbaker PH. Forequarter amputation. In: Malawer MM, Sugarbaker PH, eds. *Musculoskeletal cancer surgery: treatment of sarcomas and allied diseases*. Dordrecht, Netherlands: Kluwer Academic Publishers, 2001:294–296.)

AMPUTATION

As a result of advances in chemotherapy regimens and limb-sparing surgical techniques, forequarter amputations are rare. Only 5% to 10% of patients with primary bone sarcomas and fewer than 5% of patients with soft tissue sarcomas of the shoulder compartment require amputation. In rare instances, however, forequarter amputation may be indicated for palliation of patients with locally advanced, unresectable metastatic carcinomas of the shoulder girdle. These tumors commonly arise from metastatic spread to regional lymph nodes, the proximal humerus, or the scapula. A large soft tissue mass may encase the neurovascular bundle or invade the chest wall. At this point, the tumor becomes unresectable. Patients typically present with the following symptoms: severe intractable pain, a useless extremity, varying degrees of paralysis or sensory impairment, and chronic lymphedema. Continued tumor growth may lead to tumor fungation, sepsis, hemorrhage, and venous gangrene (Fig. 37-40).

The indications for amputation include extremely large tumors that are associated with pathologic fracture, tumor hemorrhage, fungation, infection, or brachial plexus or axillary neurovasculature involvement. Forequarter amputation is contraindicated when tumor extends to the chest wall or extends to the paraspinal and posterior triangles of

the neck structures. The surgeon must not proceed with amputation until after ascertaining that all surgical margins will be free of tumor or for palliation of uncontrolled pain, as this radical procedure is both debilitating and disfiguring and should be avoided in a patient where curative intervention is not anticipated.

Staging studies for an anticipated forequarter amputation are necessary to map out the local anatomy. It is recommended to perform CT, MRI, angiography, and venography prior to surgery. The final decision about proceeding with the amputation is made intraoperatively, after exploration of the tumor and neurovasculature structures.

If a preoperative biopsy is required, the biopsy site should follow the incision to ensure that it can be easily removed during the procedure. Care should be taken to avoid contamination of the large posterior flap, the deltopectoral interval, the suprascapular area near the neck, and the pectoralis muscles.

When forequarter amputation is required, the following surgical guidelines are followed (Fig. 37-41):

- Place the patient in a lateral position to facilitate a semi-lateral approach.
- Expose the brachial plexus and axillary vessels via the anterior portion of the utilitarian incision; at this point, the tumor is determined unresectable.

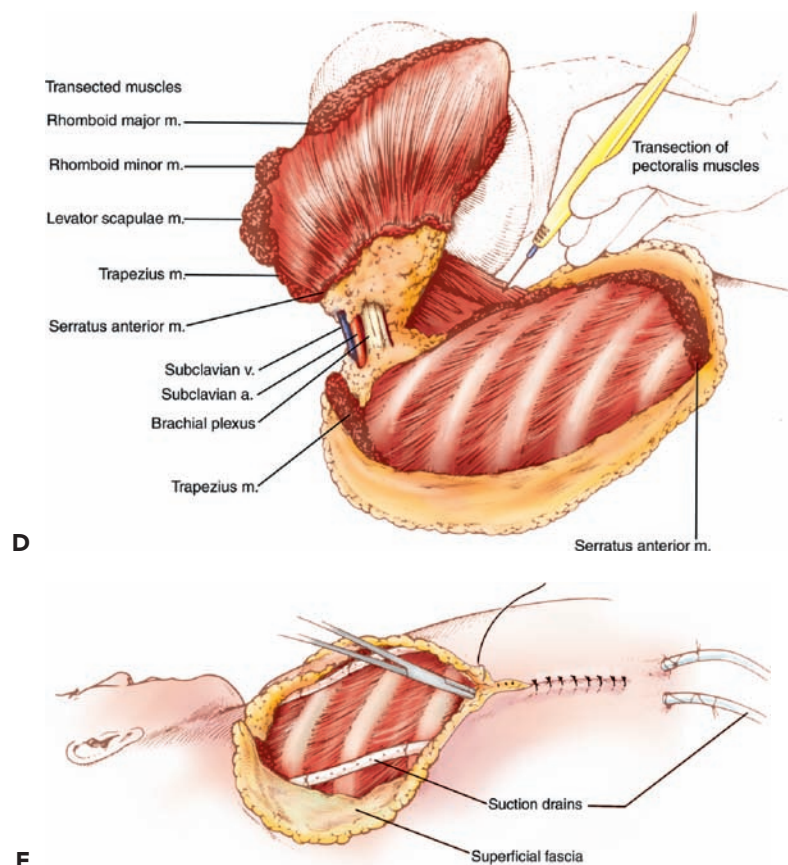


Figure 37-41 (continued)

- Prepare to explore the anterior vascular vessels by detaching the pectoralis major muscle from the clavicle, using a clavicle osteotomy at the proximal (one-third) junction.
- Clamp the vessels inferior to the clavicle.
- Use the posterior approach to detach the scapula from the trapezius, rhomboid muscles, levator scapulae, and latissimus dorsi.
- Elevate the scapula from the chest wall by detaching the latissimus dorsi to expose the chest wall.
- If no chest wall involvement is noted, the amputation proceeds with extension and connection of the anterior and posterior incisions.
- Remove the forequarter following ligation and transection of the brachial plexus and subclavian vessels.
- Insert perineural catheters bolused with 10 mL of 0.25% bupivacaine into the retained ligated nerves for regional postoperative pain relief.

Close a large posterior flap over the remaining defect and place a chest tube for drainage. A flap may need to be mobilized to accommodate heavily irradiated skin in patients who were previously treated with external-beam radiation therapy.

REFERENCES

1. Dahlin DC. *Bone tumors: general aspects and data on 6221 cases*, 3rd ed. Springfield, IL: Charles C Thomas Publisher, 1978.
2. Linberg B. Interscapulo-thoracic resection for malignant tumors of the shoulder girdle region. *J Bone Joint Surg Am* 1928;10:344.
3. Malawer MM, Meller I, Dunham WK. A new surgical classification system for shoulder-girdle resections. Analysis of 38 patients. *Clin Orthop* 1991;(267):33-44.
4. Wittig JC, Bickels J, Kellar-Graney KL, Meller I, Malawer MM. Constrained total scapula reconstruction after resection of high-grade sarcoma. *Clin Orthop* 2002;(397):143-155.
5. Wodajo F, et al. Reconstruction with scapular endoprotheses provides superior results after total scapular resection. Presented at the Annual meeting of the Musculoskeletal Tumor Society, Toronto, Ontario, (April 2002).

