

# Osteosarcoma of the Proximal Humerus: Long-Term Results With Limb-Sparing Surgery

*James C. Wittig, MD\*;  
Jacob Bickels, MD\*\*;  
Kristen L. Kellar-Graney, BS†;  
Frank H. Kim, MS†;  
and Martin M. Malawer, MD†*

The purpose of the current study was to analyze the long-term oncologic and functional results and complications associated with limb-sparing surgery and endoprosthetic reconstruction for 23 patients with osteosarcoma of the proximal humerus. There was one Stage IIA lesion, 18 Stage IIB lesions, and four Stage III lesions in this study group. Twenty-two patients were treated with an extraarticular resection that included the deltoid and rotator cuff and one patient was treated with an intraarticular resection that spared the shoulder abductors. In all these patients, the proximal humerus was reconstructed with a cemented endoprosthetic replacement that was stabilized via a technique of static suspension (Dacron tapes) and dynamic suspension (muscle transfers). At latest followup (median, 10 years), 15 patients (65%) were alive without evidence of disease. There were no local recurrences. Prosthetic survival

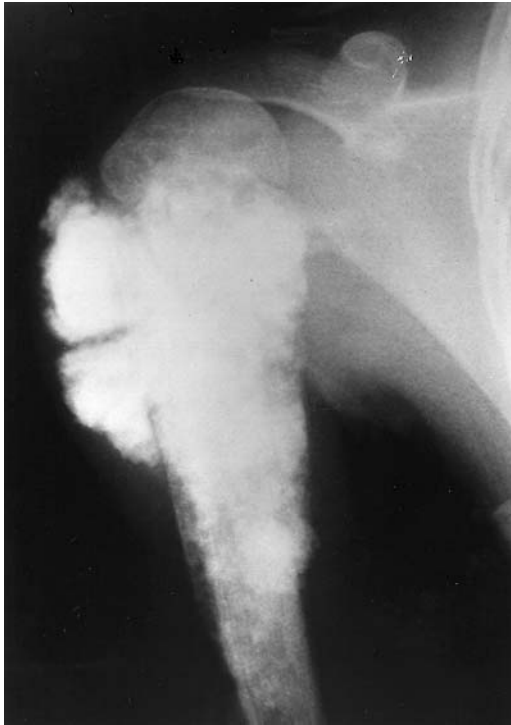was 100% for the 15 survivors. The Musculoskeletal Tumor Society upper extremity functional score ranged from 24 to 27 (80%–90%). All shoulders were stable and pain-free. Elbow and hand function were preserved in all patients. The most common complication was a transient neurapraxia (n = 8). En bloc extraarticular resection and endoprosthetic reconstruction is a safe and reliable method of limb-sparing surgery for patients with high-grade extracompartmental osteosarcoma of the proximal humerus.

The proximal humerus is the third most common site of origin for osteosarcoma<sup>22,44,49,51,52</sup> (Fig 1). Before 1970, most patients with high-grade sarcomas arising in this location were treated with a forequarter amputation.<sup>51</sup> The only reported limb-sparing shoulder girdle resections were done for patients with low-grade scapular and periscapular sarcomas and were termed Tikhoff-Linberg resections.<sup>16,38</sup> This procedure accomplished en bloc, extraarticular resection of the entire scapula with the intracapsular portion of the proximal humerus, lateral 2/3 of the clavicle, and overlying deltoid and rotator cuff muscles.

The development of effective induction and adjuvant chemotherapy protocols prompted

From the \*Department of Orthopedic Surgery, New York University Medical Center and the Hospital for Joint Diseases, New York, NY; the \*\*Tel-Aviv Sourasky Medical Center National Unit of Orthopedic Oncology; and the †Department of Orthopedic Oncology, Washington Cancer Institute at the Washington Hospital Center, Washington, DC.

Reprint requests to Martin Malawer, MD, Department of Orthopedic Oncology, Washington Cancer Institute, Suite C-2713, 110 Irving Street, N.W., Washington, DC 20010.



**Fig 1.** A plain radiograph shows a proximal humerus osteosarcoma. The metaphyseal epicenter and extraosseous soft tissue component that is a common characteristic of most osteosarcomas arising in this location can be seen.

Marcove et al<sup>50</sup> to extend the indications for limb-sparing shoulder girdle resections to include high-grade sarcomas of the proximal humerus and scapula. In 1977, they published the first series of osteosarcomas of the proximal humerus treated with wide, en bloc, extraarticular resection.<sup>50</sup> This procedure, termed a modified Tikhoff-Linberg resection, entailed resection of the proximal humerus, intact glenohumeral joint, lateral  $\frac{2}{3}$  of the clavicle, rotator cuff muscles, and deltoid muscle. Surgical margins and local tumor control rates were similar to those achieved with forequarter amputation. Most important, survival did not seem to be compromised and a functional hand and elbow were preserved. Limb-sparing resection for patients with high-grade osteosar-

coma of the proximal humerus, in lieu of a forequarter amputation, subsequently became widely accepted.<sup>1,4,7,10,12,17,19,21,23,25,32,33,37,39,40,43,46,48,53,54,61,67</sup>

The major obstacle after a limb-sparing proximal humerus resection is the restoration of shoulder girdle stability. During the earliest experience with shoulder girdle resections, surgeons made no attempt at reconstruction.<sup>13,17,25,50</sup> Extremities were left flail, which resulted in instability, traction neurapraxia, and the need to wear an orthosis. Subsequently, attempts were made to stabilize the remaining humeral shaft to the clavicle or a rib, either via direct attachment, using heavy nonabsorbable sutures or wires, or indirectly, by cementing a Kuntscher rod or custom-made spacer into the remaining shaft and stabilizing its proximal end.<sup>4,33,50,67</sup> Many surgeons were dissatisfied with these techniques because of the high incidence of failure of fixation, hardware failure, skin breakdown secondary to chronic rod irritation, and pain. Some surgeons advocated fusions using allografts from cadavers or free vascularized autogenous bone grafts to restore stability.<sup>10,19,37,54</sup> These constructs required long periods of immobilization and frequently failed secondary to fracture, nonunion, and infection. Donor site morbidity also was a problem. If a successful fusion was achieved, the patient lost rotation below the shoulder level, where most activities of daily living are done.

In 1985, Malawer<sup>39</sup> and Malawer et al<sup>48</sup> reported results of nine patients with high-grade sarcomas of the proximal humerus (four osteosarcomas) who were treated with en bloc, extraarticular resection (modified Tikhoff-Linberg resection; Malawer Type VB shoulder girdle resection).<sup>46</sup> The goals were to do an oncologically safe and reliable resection and to provide a method of reconstruction that stabilized the shoulder, without compromising rotation and that preserved elbow and hand function. Reconstruction was accomplished with an endoprosthetic proximal humerus that was stabilized to the remaining scapula and clavicle with nonabsorbable 3-mm Dacron tapes (static suspension) and various muscle transfers (dy-

dynamic suspension). There were no local recurrences. All shoulders were stable, and a functional elbow and hand were preserved in all patients. Complications were minimal, and no patients experienced pain or required an orthosis.

Since 1980, the senior author (MMM) has done limb-sparing surgery with endoprosthetic reconstruction for 23 patients with osteosarcoma of the proximal humerus. The current authors report the indications, surgical technique, oncologic and functional results, and complications associated with limb-sparing resection and endoprosthetic reconstruction for osteosarcoma of the proximal humerus. Emphasis is given to en bloc, extraarticular resection including the deltoid and lateral portion of the rotator cuff (Type VB resection; Malawer's classification) for tumors with an extraosseous component and endoprosthetic reconstruction using static (Dacron tapes) and dynamic (muscle transfers) suspension to achieve stability.<sup>46</sup> The authors summarize the results of that 20-year surgical experience. The strengths of this study are that (1) it focuses on a relatively large number of patients, all with high-grade intramedullary osteosarcomas; (2) all surgeries were done by one surgeon; (3) the same surgical method for resection and reconstruction was used for each patient; and (4) followup is relatively long, with a median of 10 years. This study is the largest series reported to date that focuses on limb-sparing surgery for osteosarcoma of the proximal humerus.

## MATERIALS AND METHODS

A retrospective analysis was conducted on all patients treated for osteosarcoma of the proximal humerus, by the senior author, between 1980 and 1998. Twenty-six patients were identified. Three patients were treated with forequarter amputation. Twenty-three of the 26 patients were treated with limb-sparing resection and endoprosthetic reconstruction. These 23 patients are the focus of this analysis.

### Patient Demographics

Twenty-three patients, 10 to 77 years of age (median, 18 years), had limb-sparing resection and en-

doprosthetic reconstruction for high-grade osteosarcoma of the proximal humerus (Table 1). There were 12 males and 11 females. The overall followup ranged from 6 months to 234 months (median, 76 months). All survivors were followed up for at least 2 years or until death (range, 24 months–234 months; median 120 months). Biopsy was done through the anterior  $\frac{1}{3}$  of the deltoid in all patients and confirmed the diagnosis of a high-grade osteosarcoma.

One patient (4%) presented with a Stage IIA lesion, 18 presented with Stage IIB lesions (78%), and four presented with Stage III lesions (17%). The primary tumors in all patients with Stage III lesions extended extraosseously (extracompartmental). All patients with Stage III lesions presented with pulmonary metastases only. Nine of 18 patients with Stage IIB tumors had pulmonary metastases develop during their course of treatment. Three of these patients also had bony metastases develop. All patients, except one (Patient 23), who presented with or had pulmonary metastases develop had thoracotomy, pulmonary metastasectomy, and additional chemotherapy. The size of the primary lesion was retrievable from the medical records for 13 patients. The length varied from 5 to 21 cm (median, 13 cm) and the width ranged from 2 to 12 cm (median, 6 cm). Seven patients presented with pathologic fractures (Patients 3, 4, 6, 7, 9, 13, and 20). All extremities were immobilized and treated with induction chemotherapy. All fractures healed and the patients were considered candidates for limb salvage surgery.

Eighteen patients received induction chemotherapy before surgical resection. The induction chemotherapy regimen was based on cisplatin and doxorubicin for the majority of patients. Five patients (Patients 2, 10, 12, 17, and 23) did not have induction chemotherapy because they were participants of an early protocol that randomized patients to induction chemotherapy, surgery plus adjuvant chemotherapy, or immediate surgery followed by adjuvant chemotherapy. All patients received postoperative adjuvant chemotherapy per standard protocols at the time of administration. Additional details about dosages and deviations from protocol were not available.

All patients with Stage IIB and Stage III tumors ( $n = 22$ ) were treated with an extraarticular resection encompassing the deltoid and lateral portions of the rotator cuff (Type VB; Malawer classification<sup>46</sup>). The tumor was removed en bloc with the

**TABLE 1. Demographics and Clinical Data on 23 Patients With High-Grade Osteosarcoma of the Proximal Humerus**

Patient Number	Gender	Age (years)	Stage	Size (cm)	Pathologic Fracture	Induction Chemotherapy	Tumor Necrosis (percent)	Followup (months)	Metastases	Patient Status	E	Complication
1	M, 15	I/A	—	21×2	—	CDDP and DOX	95–100	101	—	ANED	M	AIN
2	F, 22	I/B	—	—	—	—	—	216	—	ANED	M	—
3	M, 77	I/B	19×7	—	+	CDDP and DOX	80–85	21	—	D (CVA)	M	RN
4	F, 14	I/B	—	—	+	CDDP and DOX	90	76	—	ANED	M	—
5	M, 16	I/B	20×9	—	—	CDDP and DOX	100	120	—	ANED	M	—
6	F, 10	III	—	—	+	CDDP and DOX	100	122	P	ANED	M	—
7	M, 18	III	15×6	—	+	CDDP and DOX	25–50	48	P	D	C	Skin necrosis
8	M, 12	III	—	—	—	HDMTX and BCD	25–50	24	P and B (18 months)	D	C	—
9	F, 19	I/B	20×12	—	+	CDDP and DOX	99	30	—	ANED	C	RN and UN
10	M, 18	I/B	—	—	—	—	—	210	—	ANED	C	—
11	M, 29	I/B	—	—	—	CDDP and DOX	99	71	P (22 months)	ANED	M	—
12	F, 15	I/B	12×5	—	—	—	—	234	—	ANED	C	—
13	M, 20	I/B	12×5	—	+	CDDP and DOX	100	103	—	ANED	M	RN and UN Skin necrosis
14	M, 17	I/B	12×6	—	—	V and HDMTX	25–50	12	P (3 months) and B (9 months)	D	C	RN/UN
15	F, 24	I/B	17×4	—	—	CDDP and DOX	95	30	P and B (14 months)	D	M	—
16	F, 17	III	—	—	—	HDMTX and BCD	?	203	P	ANED	C	Fracture (15 years) and AL
17	M, 20	I/B	—	—	—	—	?	190	P (24 months)	ANED	C	—
18	F, 30	I/B	—	—	—	CDDP and DOX	?	18	P and B (8 months)	D	C	RN
19	M, 34	I/B	8×6	—	—	CDDP, DOX and IFOS	50	19	P (8 months)	D (CML)	M	RN and UN
20	F, 16	I/B	6×4	—	+	CDDP and DOX	10	24	—	ANED	M	—
21	F, 14	I/B	17×10	—	—	CDDP and DOX	90	139	P (10 months)	ANED	M	AIN
22	F, 16	I/B	5×3	—	—	CDDP and DOX	50	108	P (8 months)	ANED	M	—
23	M, 20	I/B	—	—	—	—	—	6	P (3 months)	D	C	—

P = pulmonary metastases, B = bony metastases, E = endoprosthesis type, M = modular prosthesis, C = custom prosthesis, MSTs = Musculoskeletal Tumor Society Functional Score, CDDP = cisplatin, DOX = doxorubicin, V = vincristine, HDMTX = high-dose methotrexate, BCD = bleomycin, cyclophosphamide, actinomycin D, IFOS = ifosfamide, ANED = alive without evidence of disease, D = deceased, RN = radial neuroparaxia, UN = ulnar neuroparaxia, AL = aseptic loosening, AIN = anterior interosseous neuroparaxia, + = received induction chemotherapy, ? = unknown or not retrievable from chart, CVA = cerebrovascular accident, CML = chronic myelogenous leukemia



proximal humerus, intact glenohumeral joint, lateral  $\frac{1}{3}$  to  $\frac{1}{2}$  of the clavicle, overlying rotator cuff, and deltoid. The joint capsule was not violated and the scapular osteotomy was made just medial to the coracoid process. Extraarticular resection was followed with endoprosthetic reconstruction using a method of static (3-mm Dacron tapes) and dynamic (muscle transfers) suspension of the prosthesis to the clavicle and scapula for prosthetic stabilization, as described previously by Malawer<sup>39</sup> and Malawer et al.<sup>48</sup> The only patient with a Stage IIA tumor was treated with an intraarticular resection that spared the deltoid and rotator cuff (Type IA resection; Malawer classification system<sup>46</sup>). A 40-mm wide Goretex aortic graft (WL Gore and Associates, Flagstaff, AZ) was used to statically stabilize the proximal humerus endoprosthesis to the glenoid. The rotator cuff muscles and deltoid were sutured to the prosthesis and Goretex graft for dynamic stabilization and reconstruction of the abductor mechanism. Thirteen modular segmental prosthetic replacements (after 1988) that permitted intraoperative sizing and 10 custom replacements (before 1988) were used for reconstruction. All endoprostheses were cemented into the remaining distal humeral shaft.

Routine pathologic analysis was done on all specimens after resection. The response of the primary neoplasm to the induction chemotherapy regimen was determined by an experienced pathologist according to the system of Rosen et al<sup>59</sup> and expressed as the percentage of tumor necrosis in the surgical specimen. The estimated percentage of histologic tumor necrosis was retrievable from the medical records for 16 of the 18 patients treated with induction chemotherapy.

Postoperatively, clinical examination, plain radiographs of the operative extremity, and computed tomography (CT) scans of the chest were done approximately every 3 months for 2 years after surgery, every 6 months from the second through fifth years, and on a yearly basis thereafter. After the tenth year, a radiograph of the chest usually was substituted for the CT scan of the chest. Function at latest followup was evaluated according to the Musculoskeletal Tumor Society functional evaluation system.<sup>14</sup> This system evaluates each of the following areas: pain, function, emotional acceptance, hand positioning, dexterity, and lifting ability. The greatest cumulative score that a patient could be assigned was 30 points and was based on a greatest possible score of 5 points in

each subcategory. Elbow and hand strength were evaluated by comparing results of manual motor testing of the affected and unaffected extremities. Shoulder range of motion (ROM) was estimated by visual inspection. All patients were questioned about their ability to do activities of daily living and about their participation in athletic or recreational activities.

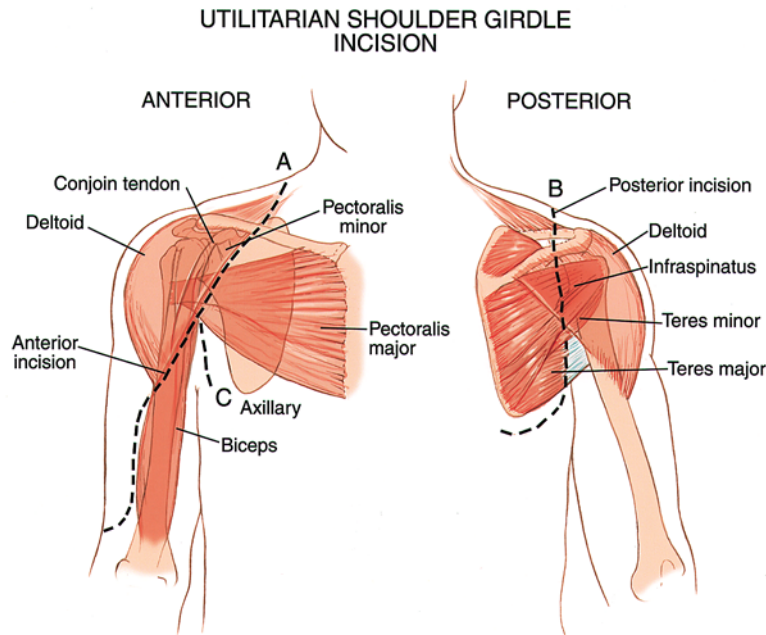
### Surgical Technique

Extraarticular resection requires a combined anterior and posterior approach. An intraarticular resection, by contrast, can be done solely through an anterior approach. In an extraarticular resection, the neurovascular bundle initially is explored and resectability determined through the anterior approach. The neurovascular bundle is dissected away from the pseudocapsule of the tumor during this portion of the procedure. The posterior approach is required for exposing the scapula and doing the scapular osteotomy.

The approach that is used is referred to as the utilitarian shoulder approach (Fig 2). The incision consists of three arms, each of which results in construction of a skin flap in which the base is at least as wide as the flap is long. The incision results in a large, medially based posterior skin flap that can be used for anterior coverage of the chest wall if a forequarter amputation is necessary at the time of the index procedure or postoperatively to treat a local recurrence or complication. For an extraarticular resection of a proximal humerus osteosarcoma, incision A is used in entirety and a portion of incision B. The incision can be extended into the axilla (incision C) for tumors with a large axillary component; however, this was not necessary in any of the patients in this study.

### Anterior Approach

The patient is positioned in a semilateral position on a bean bag with the affected arm abducted and extended, and resting on a padded, sterile stand. The surgical incision extends distally from the middle  $\frac{1}{3}$  of the clavicle, passes just medial to the coracoid along the deltopectoral groove, and follows the course of the neurovascular bundle, distally along the anteromedial aspect of the arm. The biopsy site is removed in an elliptical manner in continuity with the skin incision and left attached to the surgical specimen. Full-thickness, fasciocutaneous skin flaps are developed medially and laterally. The deltopectoral groove is identified and



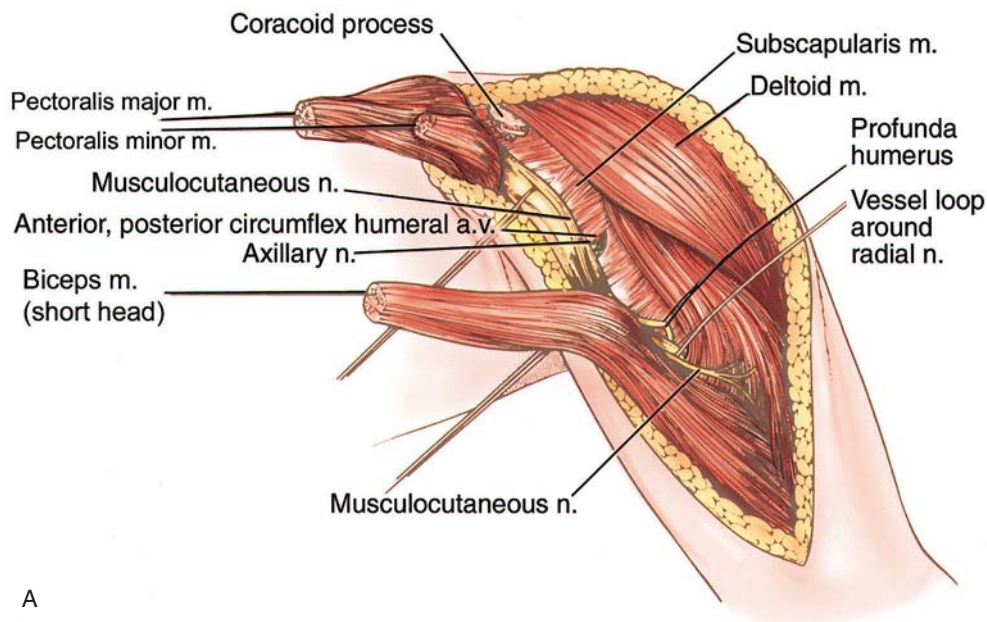
**Fig 2.** This schematic shows the utilitarian shoulder girdle approach. The approach consists of three potential incisions (A, B, C) all of which result in a skin flap in which the base is at least the same width as the length of the flap. Incision A (anterior approach) permits exposure and exploration of the neurovascular bundle and osteotomy through the humerus. Incision B (posterior approach) exposes the posterior scapula and creates a wide medially-based posterior fasciocutaneous skin flap. Incision C (axillary extension) can be used for exposure of tumors with an extremely large axillary component. All extraarticular resections in the current series were done through a combined anterior (incision A) and posterior (incision B) approach. The only intraarticular resection was done via an anterior approach only (incision A). (Reprinted with permission from Wittig J, Kellar-Graney K, Malawer M, Bickels J, Meller I: Limb sparing surgery for high grade sarcomas of the proximal humerus. *Tech Shoulder Elbow Surg* 2:54–69, 2001.)

the cephalic vein is ligated, divided, and resected proximally and distally at the wound margins.

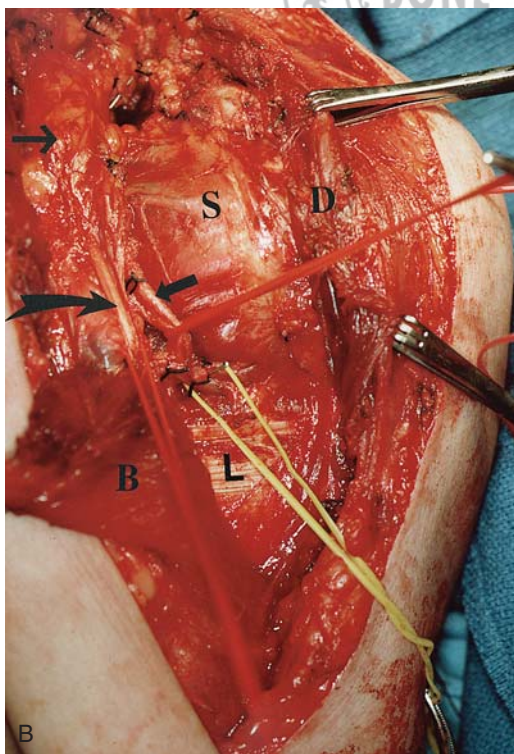
### Exposure and Exploration of the Neurovascular Bundle

The key step in exposing the neurovascular bundle is releasing the pectoralis major from its humeral insertion followed by the strap muscles (coracobrachialis, short head of the biceps, pectoralis minor) from their insertions on the coracoid. The inferior border of the pectoralis major is identified and the fascia is opened. The pectoralis major insertion is released from the humerus using Bovie cautery. The pectoralis major is retracted medially. The musculocutaneous nerve is dissected inferomedial to the coracoid in the interval between the pectoralis minor and coracobrachialis and short

head of the biceps insertions, where it enters these latter muscles. With the musculocutaneous nerve protected, the coracobrachialis and short head of the biceps complex is released from its coracoid insertion. This is followed by release of the pectoralis minor. At this point, the entire neurovascular bundle can be observed from the clavicle to the humerus (Fig 3). The axillary and radial nerves are dissected up to their origins from the posterior cord of the brachial plexus and are protected. The anterior and posterior humeral circumflex vessels are ligated and divided to retract the neurovascular bundle away from the tumor pseudocapsule (subscapularis muscle). For tumors with an extraosseous component, the axillary nerve is ligated. The musculocutaneous nerve, radial nerve, remainder of the plexus, and vascular structures are retracted and protected



A



B

**Fig 3A–B.** (A) This schematic shows exposure of the major neurovascular bundle to the upper extremity after release of the pectoralis major, short head of the biceps, coracobrachialis, and pectoralis minor (m = muscle; n = nerve; a.v. = artery and vein). (Reprinted with permission from Wittig J, Kellar-Graney K, Malawer M, Bickels J, Meller I: Limb sparing surgery for high grade sarcomas of the proximal humerus. *Tech Shoulder Elbow Surg* 2:54–69, 2001.) (B) An intraoperative photograph shows exposure of the neurovascular bundle. B = short head of biceps; S = subscapularis (overlying tumor of the proximal humerus); D = deltoid L = latissimus. The large straight arrow points to the neurovascular bundle in axillary sheath; the large curved arrow points to the musculocutaneous nerve; and the small wide arrow points to the axillary nerve and posterior humeral circumflex vessels.



for the remainder of the procedure. In all cases in this study, it was possible to preserve the musculocutaneous, radial, ulnar, and median nerves and the vascular structures.

### Extraarticular Resection

The skin incision is extended posterolaterally over the top of the shoulder to the scapular tip. A wide, medially based fasciocutaneous skin flap is raised. A distally based, lateral, fasciocutaneous skin flap also is raised to expose to entire deltoid. The trapezius is released from its insertion on the clavicle, acromion, and scapular spine to the area just medial to the coracoid process where the scapular osteotomy is done (Fig 4). The rotator cuff is incised just medial to the coracoid and an osteotomy is made through this area with a high-speed burr or sagittal saw. A second osteotomy is made through the clavicle, usually at the junction of its middle  $\frac{1}{3}$  and outer  $\frac{1}{3}$ . The latissimus dorsi and teres major are released from the humerus. The humeral osteotomy is made 2 cm to 3 cm distal to the tumor extent to ensure a wide margin. Any brachialis muscle overlying tumor is resected en bloc. The tendon of the long head of the biceps is resected where it is juxtaposed to tumor. All margins, in-

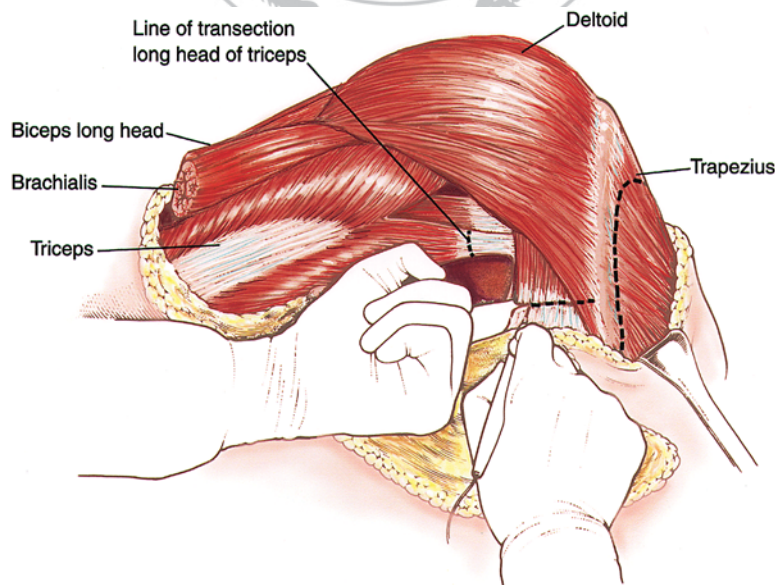
cluding the distal intramedullary margin and axillary sheath, are sent for frozen section analysis. The proximal humerus, intact glenohumeral joint, deltoid, and lateral portions of the rotator cuff and clavicle are removed en bloc.

### Intraarticular Resection

The anterior approach is done as described previously; however, the axillary nerve is protected and preserved. There is no need to extend the skin incision posteriorly. The deltoid, long head of the biceps, latissimus-teres major complex, rotator cuff, and glenohumeral joint capsule are released sequentially from their insertions. The osteotomy is made through the proximal humerus as described for an extraarticular resection. The trapezius insertion is not violated.

### Extraarticular Reconstruction

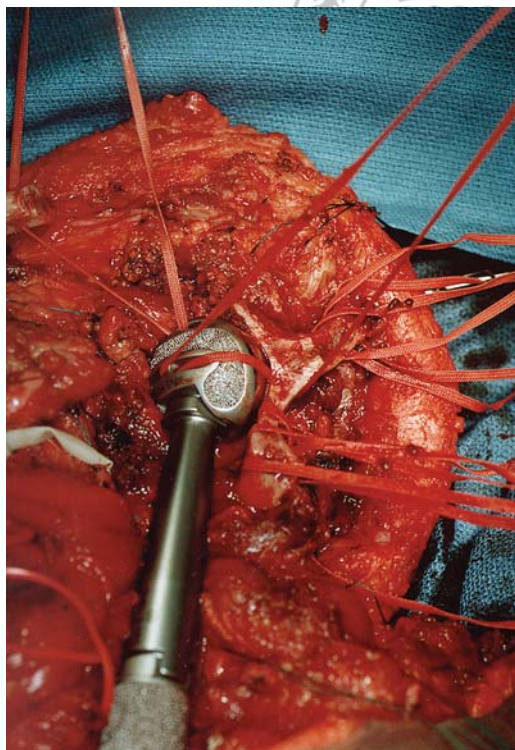
An endoprosthetic proximal humerus is used. The authors currently recommend a modular system. The length should allow shortening of the arm by 2 cm to 3 cm to prevent traction on the neurovascular structures and to facilitate wound closure. The canal of the remaining distal humerus is reamed for placement of the thickest possible stem, accommo-



**Fig 4.** This schematic shows the posterior approach to the scapula for an extraarticular resection. (Reprinted with permission from Wittig J, Kellar-Graney K, Malawer M, Bickels J, Meller I: Limb sparing surgery for high grade sarcomas of the proximal humerus. *Tech Shoulder Elbow Surg* 2:54–69, 2001.)



dating for a 2-mm cement mantle. The prosthesis is cemented in retroversion so the head of the humerus faces the subscapular fossa. Static suspension is provided by Dacron tapes (3-mm) that are passed separately through the scapula and clavicle, and through holes in the neck of the proximal humerus prosthesis (Fig 5). The proximal humerus is suspended vertically from the clavicle (vertical static suspension) and horizontally from the scapula (horizontal static suspension). The pectoralis minor is attached to the remaining subscapularis muscle so that it protects the neurovascular structures from the prosthesis. Dynamic prosthetic suspension, consisting of multiple muscle transfers, subsequently is done. The short head of the biceps is transferred to the clavicle and tenodesed with a 3-



**Fig 5.** Static suspension of the prosthesis is accomplished with 3 mm Dacron tapes. The prosthesis is retroverted so that its articular surface faces the subscapular fossa. It then is suspended vertically from the clavicle and horizontally from the lateral border of the scapula. Additional Dacron tapes are passed through the lateral border of the scapula for tenodesis of the pectoralis major.

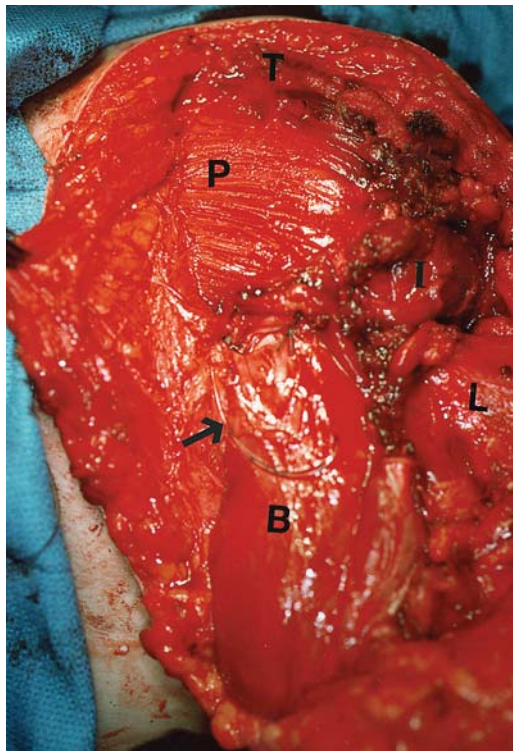
mm Dacron tape (dynamic vertical suspension). The trapezius is transferred distally over the head of the humerus and tenodesed to the prosthesis (dynamic vertical suspension). The pectoralis major is transferred laterally so that it covers the entire proximal humerus. It is sutured to the holes in the neck of the prosthesis, any remaining infraspinatus muscles, the lateral border of the scapula, and the border of the trapezius (dynamic horizontal suspension). To restore external rotation and cover the distal lateral aspect of the prosthesis, the latissimus-teres major complex is rerouted around the posterolateral aspect of the prosthesis and attached in an anterolateral position to the prosthesis and to adjacent muscles. The long head of the biceps is reattached to the pectoralis major with the forearm supinated and the elbow in 45° flexion. The tension of the biceps is set at  $\frac{1}{2}$  the distance of full stretch. All adjacent muscle borders are sutured to each other using number 0 braided nonabsorbable suture. At the conclusion of all the muscle transfers, the entire prosthesis is covered with muscle (Figs 6, 7).

### Intraarticular Reconstruction

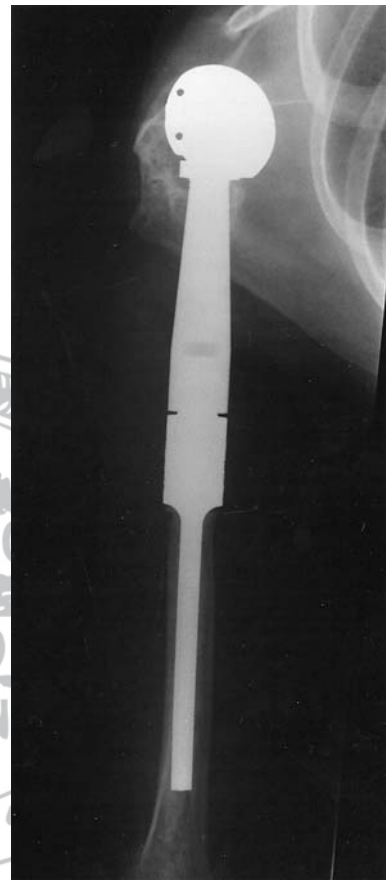
A modular proximal humerus prosthesis is recommended. The canal is reamed and the prosthesis is implanted while maintaining proper retroversion of the humeral head (30°–45° retroversion). Static capsular reconstruction is accomplished with a 40-mm diameter Goretex aortic graft. The aortic graft is sutured with Dacron tapes to the glenoid labrum and capsular base, and its free end is pulled over the head of the prosthesis where it is sutured to the holes in its neck. The aortic graft provides static stability until healing and scarring occur. It also facilitates muscle reattachment. The rotator cuff and deltoid are reattached to the prosthesis and Goretex aortic graft. The short head of the biceps is reattached proximally to the coracoid, and the long head of the biceps is tenodesed to the pectoralis major.

### Epineural Analgesia

Before doing muscle transfers, a 20-gauge silastic epidural catheter is threaded proximally within the plexus sheath and sutured to surrounding fascia with 4-0 absorbable suture.<sup>41</sup> The free end is brought through the skin using a 14-gauge angio-catheter. Bupivacaine (0.25% without epinephrine) is infused through the catheter postoperatively for analgesia (a bolus of 10 cc, followed by 4 cc/hour continuous infusion). The dosage can be titrated for maximal pain relief.



**Fig 6.** Dynamic suspension of the prosthesis is accomplished with multiple muscle transfers. At the conclusion, the entire prosthesis is covered with muscle. P = pectoralis major; T = trapezius; I = infraspinatus; B = biceps; L = latissimus major complex. The arrow points to the epineural catheter in axillary sheath.



**Fig 7.** A radiograph taken after extraarticular resection shows endoprosthetic reconstruction.

### Closure

Closed suction drains are placed. The wound is closed in layers. A bulky soft dressing and elbow splint are applied to reduce postoperative edema and maintain the elbow in 45° flexion, respectively.

## RESULTS

### Local Control

There were no local recurrences in any of the 23 patients.

### Overall Survival

Fifteen patients (65%) were alive without evidence of disease at a range of 24 months to

234 months (median, 120 months). This included two patients with Stage III lesions, 12 with Stage IIB lesions, and one with a Stage IIA lesion. Eight patients (35%) died at a range of 6 months to 48 months (median, 20 months). Six of these patients died of tumor-related causes and two died of unrelated causes.

### Prosthetic Survival

Prosthetic survival for the 15 survivors has been 100% at a median followup of 120 months (range, 24 months – 234 months). No prosthesis required a revision in any of the survivors or patients who died. There was one instance of aseptic loosening that was detected radiograph-

ically. It developed after a periprosthetic fracture and was asymptomatic (Patient 16).

### Complications

Complications included eight transient nerve palsies (two anterior intraosseous nerve palsies; two radial nerve palsies; four combined radial and ulnar nerve palsies). All nerve palsies resolved within 6 to 12 months after surgery. There were two instances of minor skin necrosis that healed with dressing changes. One periprosthetic fracture occurred distal to the prosthesis 15 years after surgery, secondary to a fall. The patient was treated with a brace until a stable union occurred. The patient was pain-free and function was unaltered after the fracture healed, although the patient subsequently had radiographic signs of aseptic loosening. The patient was asymptomatic and therefore a revision was not done. There were no instances of prosthetic instability or dislocation, clinically or radiographically. There were no infections. No patients had late traction neurapraxias develop from the weight of the upper extremity.

### Functional Outcome

The Musculoskeletal Tumor Society upper extremity functional scores ranged from 24 to 27 (80% to 90%). All shoulders were stable. All patients could do activities of daily living with the involved extremity. Functional results were consistent and uniform among all patients. All survivors received a score of 5 (best possible rating) in the areas of pain, hand dexterity, and emotional acceptance. No patient complained of pain. All patients had normal functional use of the hand (normal sensation; Grade 5 motor strength) and all were emotionally accepting of the procedure and outcome. Patients lost points in the following areas: function, hand positioning, and lifting ability. Because the score for each of these areas was subjective, a range was assigned as the score. In terms of function, patients were assigned a score of 3 to 4 points. All patients had some restrictions in activities but were capable of participating in some recreational activities.

Most restrictions were in high-level athletics, although one patient (Patient 1) wrestled for his high school and college teams. Other patients played tennis, lifted weights (within limits), rode bicycles, rowed boats, and swam regularly. All patients were assigned a score of 3 to 4 for hand positioning. Hand positioning was not unlimited, but all patients could place their hands above their shoulders, touch the back of their head and opposite shoulder, and feed themselves. Active shoulder ROM varied slightly from patient to patient but was within the following ranges: forward flexion, 25° to 45°; abduction, 25° to 45° (secondary to trapezius transfer and scapulothoracic motion); internal rotation, 90°; external rotation, -15° to neutral. Passive shoulder motion was within normal limits for all patients. Lifting ability was graded 3 to 4 for each patient. All patients had normal functional use of the elbow and elbow motor strength was at least Grade 4 in all patients. Patients did not have difficulty carrying objects with the arm adjacent to the body; however, they had difficulty carrying objects with the arm away from the body because of a lack of deltoid and rotator cuff function. No patients could lift objects significantly above shoulder level.

### DISCUSSION

It is difficult to derive from the literature an exact approach to treating osteosarcomas arising from the proximal humerus. Controversy exists concerning the indications for extraarticular versus intraarticular resection and regarding the best method of reconstruction after each type of resection. Much of this difficulty has arisen from the low incidence of osteosarcoma arising in this location. Although the proximal humerus is the third most common site of origin for osteosarcoma, only approximately 15% of all osteosarcomas arise from this location.<sup>44</sup> In the United States, this translates into approximately 50 to 70 cases per year. Given this incidence, it has been difficult for individual surgeons to develop a large series of patients; consequently, most surgeons



report oncologic and functional results associated with limb-sparing shoulder girdle resections that are based on mixed groups of patients. Reports have included patients with various types and grades of sarcomas (osteosarcoma, chondrosarcoma, Ewing's sarcoma) and have combined results from patients with proximal humerus and scapular tumors. Patients with metastatic carcinomas occasionally have been included in some series. Frequently, the type of resection (extraarticular versus intraarticular) has not been specified for each tumor type, which causes difficulty in evaluating the oncologic results associated with the type of resection, as assessed by local recurrence rates.<sup>12</sup> Some reports have focused on results of reconstruction after limb-sparing surgery and have included patients reconstructed via multiple methods. Various systems, particularly the Musculoskeletal Tumor Society system<sup>14</sup> and the system of Gebhardt et al<sup>19</sup> have been used for functional evaluation by different authors. Therefore there has been difficulty with deriving statistically significant conclusions about functional results and complications, and in comparing results among different institutions.

The current study reports excellent local tumor control, consistently good to excellent function, and excellent long-term prosthetic survival for 23 patients with osteosarcoma of the proximal humerus who had limb-sparing resection (22 extraarticular, one intraarticular) and endoprosthetic reconstruction. The first priority of limb-sparing resection for a high-grade sarcoma is to achieve an oncologically safe resection. It has been proposed that the adequacy of a resection method can be evaluated by its associated local recurrence rate.<sup>12</sup> Local tumor control in this region is essential, because patients with local recurrence frequently are treated with a forequarter amputation and local recurrence of a high-grade lesion may compromise survival.<sup>1,62</sup> In the current authors' opinion, the resection should not be compromised to improve functional results. The senior author has preferred extraarticular resection that includes the deltoid and overlying

rotator cuff musculature for high-grade osteosarcomas arising from the proximal humerus that extend extraosseously. Such was the case for 22 of 23 patients in the current series. The goal has been to reliably achieve a wide surgical margin and maximize local tumor control without the need for a forequarter amputation or total scapulectomy combined with a proximal humerus resection. The reliability of this method of resection is supported by the 0% local recurrence rate presented in the current study. After resection, the goals of reconstruction were to stabilize the proximal upper extremity without compromising rotation below the shoulder level and to preserve a normally functioning hand and elbow. All patients in this study had reconstruction with an endoprosthetic proximal humerus replacement that was stabilized with static and dynamic methods of soft tissue reconstruction. Functional evaluation according to the Musculoskeletal Tumor Society System showed consistently good and uniform results among all patients. These scores ranged from 24 to 27 (80% to 90% of the maximum possible score). A score of at least 24 has been considered by at least one author as an excellent result.<sup>32</sup>

#### **Local Sarcoma Growth, Compartmental Borders, and Indications for an Extraarticular Resection**

Several biologic reasons support performance of an extraarticular resection that includes the abductor mechanism for high-grade sarcomas of the proximal humerus that extend beyond the cortices. Traditional teaching has emphasized a propensity for tumors in this location to contaminate the glenohumeral joint or to spread to the opposing glenoid and scapula, grossly and microscopically.<sup>13,39,40,46,48,61</sup> The mechanisms of spread across the glenohumeral joint are based on its unique anatomy. These mechanisms include: capsular extension, pathologic fracture hematoma, direct articular extension, spread along the long head of the biceps tendon, or through transarticular metastasis.

In discussion of local sarcoma growth, a compartmental border usually refers to any

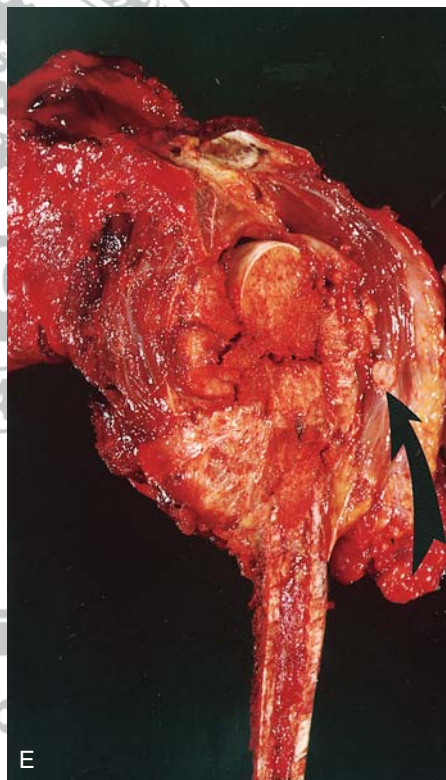
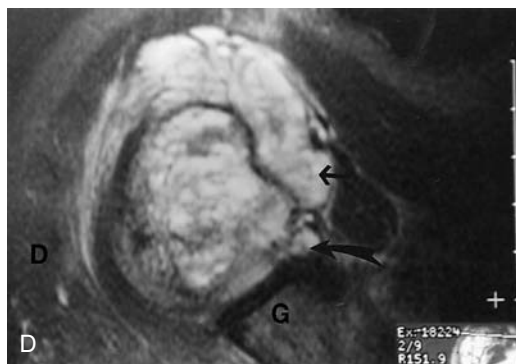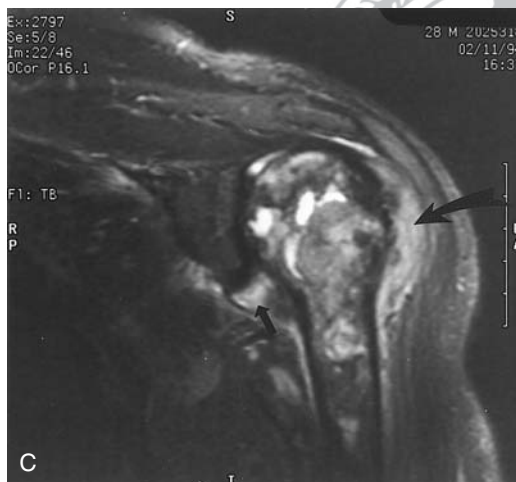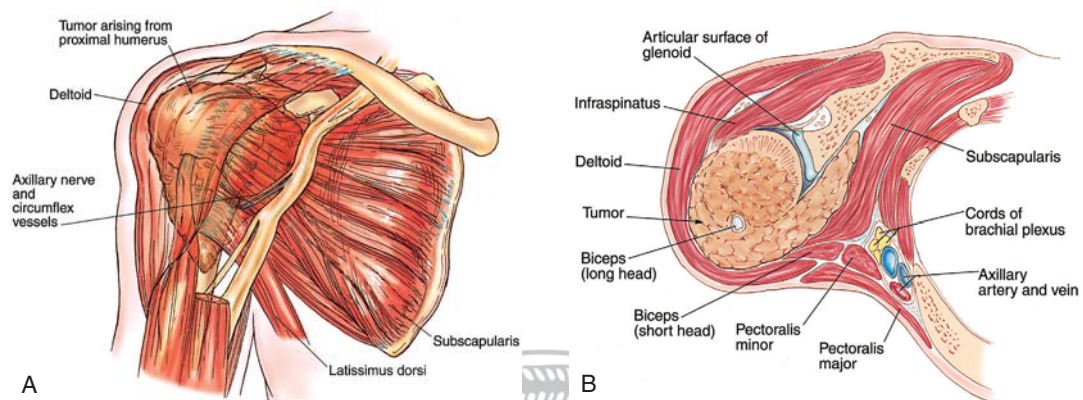


fascial boundary that resists tumor penetration as described by Enneking.<sup>12</sup> Sarcomas grow along the path of least resistance; therefore, any adjacent fascial border offers a boundary to local growth. The current authors propose that the important fascial boundaries surrounding the proximal humerus consist of the investing fascial layers of the deltoid, subscapularis, and remaining rotator cuff muscles and that these muscles form a compartment surrounding the proximal humerus that contains and delineates the local spread of a high-grade bone sarcoma. An osteosarcoma that arises from the proximal humerus and extends extraosseously will grow to fill the compartment and will compress the muscles that form the borders of the compartment into a pseudocapsular layer (Fig 8). By definition, a wide surgical margin includes the pseudocapsular layer around the tumor, because this layer contains microscopic tumor extension (satellite nodules). Therefore, for sarcomas of the proximal humerus, wide surgical resection entails en bloc resection of the deltoid and overlying rotator cuff. The axillary nerve and posterior humeral circumflex vessels pass along the inferior capsule and subscapularis muscle. They reside within the infe-

rior aspect of the pseudocapsule of any large tumor and, by strict definition, require resection. Because the glenoid is surrounded by the muscles forming the compartment, it resides within the same compartment as does the proximal humerus. The intracompartmental location places the glenoid at high risk of contamination, which lends support to concomitant glenoid resection with the proximal humerus. In addition, retention of the glenoid confers no functional benefit after resection of the axillary nerve and abductor mechanism. Its resection permits medialization of the prosthetic construct, which facilitates soft tissue coverage (Fig 9).

In a review of the literature (Table 2), the authors were able to identify 106 patients with high-grade spindle cell sarcomas (Stage IIB or Stage III) arising from the proximal humerus or scapula who were treated with an extraarticular resection encompassing the deltoid and rotator cuff.<sup>1,7,17,19,33,37,48,50,53</sup> Seven of these patients (7%) had a local recurrence develop. The authors also identified 51 patients with similar lesions who had intraarticular resection, sparing the shoulder abductors.<sup>1,20,21,32</sup> Nine patients (18%) in this group had a local recurrence develop. The difference was statis-

**Fig 8 A–E.** Local growth of an osteosarcoma from the proximal humerus is shown. (A) This schematic shows metaphyseal origin and extension beyond the cortices of the proximal humerus. The extraosseous component is crossing the glenohumeral joint. The deltoid, subscapularis, and remaining rotator cuff muscles form the compartmental boundaries around the tumor and are compressed into a pseudocapsular layer. The axillary nerve and circumflex vessels enter this compartment. The major neurovascular bundle is displaced by the tumor; however, the fascia overlying the subscapularis muscle and the axillary sheath usually protect the major neurovascular bundle from tumor involvement or encasement, in most instances. (Reprinted with permission from Wittig J, Kellar-Graney K, Malawer M, Bickels J, Meller I: Limb sparing surgery for high grade sarcomas of the proximal humerus. *Tech Shoulder Elbow Surg* 2:54–69, 2001.) (B) A cross section through the glenohumeral joint shows extension of the tumor across the glenohumeral joint and compression of the surrounding compartmental muscles into a pseudocapsular layer. The neurovascular bundle is protected by the subscapularis muscle. (Reprinted with permission from Wittig J, Kellar-Graney K, Malawer M, Bickels J, Meller I: Limb sparing surgery for high grade sarcomas of the proximal humerus. *Tech Shoulder Elbow Surg* 2:54–69, 2001.) (C) A coronal MRI scan shows the metaphyseal origin and tumor crossing the glenohumeral joint (straight arrow) and extending into the overlying deltoid muscle (curved arrow). (D) An axial MRI scan shows the extraosseous tumor extending beneath the subscapularis muscle (straight arrow) and crossing the glenohumeral joint (curved arrow). The deltoid (D) is involved by the extraosseous component (G = glenohumeral joint). (E) The surgical specimen of a high-grade osteosarcoma of the proximal humerus is shown. The pathologic fracture and extraosseous extension across the glenohumeral joint can be seen. A tumor nodule is evident in the deltoid muscle which forms part of the pseudocapsular layer. The curved arrow points to the tumor nodule in deltoid muscle.



tically significant ( $p < .05$  level). Several of these cited studies reported combined oncologic results for proximal humerus and scapular tumors; therefore, it was difficult, in many instances, to separate local control rates according to bone of origin. The current authors recommend extraarticular resection for high-grade spindle cell sarcomas (Stage IIB or Stage IIIB) arising from either the proximal humerus or scapula because of the propensity of these tumors to cross the joint in either direction. Definitive conclusions, however, should not be derived from this review because it does not consider differences in length of followup, tumor size, specific histologic type of spindle cell sarcoma, patient survival, incidence of pathologic fracture, and adjuvant treatment. However, the trend toward better local control rates with extraarticular resection encompassing the shoulder abductors should prompt additional investigation.

### Survival

In the current study, the survival rate of patients with osteosarcoma of the proximal humerus did not seem to differ significantly from survival rates reported from large studies that include similar lesions arising at other anatomic sites, such as the distal femur or proximal tibia.<sup>2,3,56,57,62</sup> Sixty-five percent of the patients in the current study were alive without evidence of disease at a median followup of 10 years (range, 2-19.5 years). There seemed to be a trend toward improved survival in patients who achieved greater than 90% tumor necrosis with induction chemotherapy, although the numbers were too small to do statistical analysis. Previous reports have documented the prognostic value of the estimated percentage of histologic tumor necrosis in the surgical specimen after induction chemotherapy.<sup>2,9,24,56,57</sup>

### Functional Results

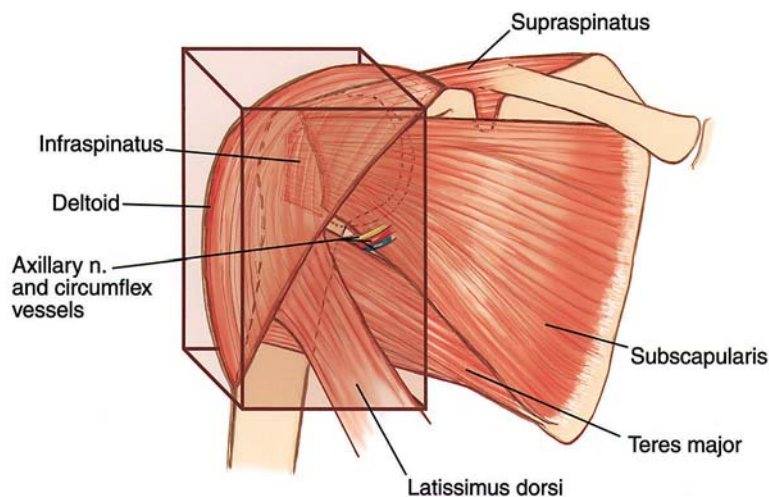
Functional results, as evaluated by the Musculoskeletal Tumor Society functional evaluation system, for all patients in this series were good to excellent (range, 80%-90%) and results were consistent among patients. Meller

et al<sup>53</sup> reported on six patients treated with extraarticular resection who had reconstruction with a modular prosthesis according to the same method as described originally by Malawer et al.<sup>48</sup> The median Musculoskeletal Tumor Society score was 75%. These results are similar to results reported by Asavamongkolkul et al<sup>1</sup> concerning intraarticular resection and endoprosthetic reconstruction. They reported an average Musculoskeletal Tumor Society functional score of 76% for 17 of their patients who had intraarticular resection and reconstruction with endoprosthetic replacement.<sup>1</sup> Preservation of the glenoid and abductor mechanism does not seem to offer better functional results, as assessed by the Musculoskeletal Tumor Society system, when compared with the patients in the current report. All of the patients in the current study had stable shoulders and all were able to do activities of daily living with the affected extremity, including feeding themselves, grooming, and personal hygiene. All patients could place their hand above the shoulder, touch the back of the head, and touch the opposite shoulder (Fig 10).

Some surgeons have advocated arthrodesis after extraarticular resection to restore shoulder stability and improve abduction. Complications and failures have occurred frequently with this method of reconstruction and functional results do not seem to be superior to those presented in the current study. In 1991, Gebhardt et al<sup>19</sup> reported on 12 patients treated with allograft arthrodeses. Five of 12 patients (42%) were considered to have failed results. In 1994, Kumar et al<sup>37</sup> reported on six patients who had reconstruction via arthrodesis with a free vascularized fibula ( $n = 4$ ) or free vascularized scapular graft ( $n = 2$ ). Two of the free vascularized fibula grafts became infected. One was not salvageable and the other was salvaged with a second free vascularized fibula graft. Three patients had nonunions develop and required repeat surgery. Two patients experienced extreme shortening of 8 to 10 cm. No patient was able to do activities above shoulder level.

O'Connor et al<sup>54</sup> recommended reconstruction via arthrodesis with a combination of an





**Fig 9.** The concept of a compartmental resection of the proximal humerus is shown. All structures that potentially are involved by the tumor (overlying muscles that form the pseudocapsular layer and compartmental borders, the glenoid, and the axillary nerve and circumflex vessels) are removed en bloc. N = nerve

**TABLE 2. Local Recurrence Rates: Extraarticular Resection Versus Intraarticular Resection of High-Grade Shoulder Girdle Sarcomas**

Authors	Extraarticular Resection			Intraarticular Resection		
	Number of Patients	Number of Local Recurrences	Percent	Number of Patients	Number of Local Recurrences	Number of Percent
Marcove et al <sup>50</sup> 1977	16	1	6	—	—	—
Malawer et al <sup>48</sup> 1985	4	0	0	—	—	—
Kaelin and Emans <sup>33</sup> 1985	7	0	0	—	—	—
Capanna et al <sup>7</sup> 1990	20	1	5	—	—	—
Frassica et al <sup>17</sup> 1987	8	1	13	—	—	—
Gebhardt et al <sup>19</sup> 1991	13	2	15	—	—	—
Meller et al <sup>63</sup> 1997	9	1	11	—	—	—
Kumar et al <sup>37</sup> 1994	6	0	0	—	—	—
Asavamongkolkul et al <sup>1</sup> 1999	1	1	100	33	5	15
O'Connor et al <sup>54</sup> 1996**	—	—	—	—	—	—
Wittig et al (current study) 2000	22	0	0	—	—	—
Gebhardt et al <sup>20</sup> 1990	—	—	—	4	2	50
Jensen and Johnston <sup>32</sup> 1995	—	—	—	8	2	25
Getty and Peabody <sup>21</sup> 1999	—	—	—	6	0	0
Total	106	7	7%	51	9	18%

\*\*unable to analyze data; surgical procedure not specified for histologic type and grade of tumor and local recurrences not specified according to type of surgical procedure





**Fig 10.** Function after extraarticular resection and endoprosthetic reconstruction (3 years postoperatively) is shown. The patient can place her hand above shoulder level with some external rotation. This is important for hair grooming and feeding.

intercalary allograft and vascularized free fibula construct for young patients treated with an extraarticular resection. They reported results for five patients. All extremities were immobilized in a spica cast for an average of 14 weeks. One patient had an infection develop postoperatively that required repeat surgery and was salvaged with a second free vascularized fibula transfer. Two patients experienced fractures and their extremities were immobilized in spica casts for 3 months; the fracture in one patient healed, and the other patient had a pseudarthrosis develop. Donor site morbidity was a frequent problem. Function according to the Musculoskeletal Tumor Society system averaged 66% for this group. These results compare inferiorly with those in the current study. Complications also were more prevalent and of greater magnitude.

The major goal after extraarticular resection of a proximal humerus osteosarcoma is to restore stability to the proximal upper extremity. The current authors accomplish this with a method of static and dynamic and prosthetic suspension as opposed to an arthrodesis for the following reasons: adequate stability can be restored; reconstruction is simplified and operating time is reduced; rotation is not restricted below the shoulder level, where most

activities are done; the procedure does not require prolonged immobilization and is associated with fewer complications, especially in the early postoperative period when chemotherapy is administered; functional results are uniform and reliable; and there is consistent healing, fewer secondary procedures, and no donor site morbidity. Most activities that require use of the upper extremity (activities of daily living) are done below the shoulder level and therefore motion in this region is more important than overhead motion. Arthrodesis severely restricts rotation below shoulder level (internal rotation, external rotation, and forward flexion). Complication rates and failures also seem greater in patients treated with arthrodeses and have resulted in many secondary procedures. Complications should be viewed seriously because the major goal is to restore a stable shoulder girdle and early functional use of the extremity, and to resume chemotherapy shortly after surgery.

Intraarticular resection has been preferred by some authors for treatment of select Stage II and Stage III sarcomas of the proximal humerus. This has been done in an effort to spare the articular surface and abductor mechanism and improve function by reconstructing the proximal humerus with an osteoarticular allograft or allograft combined with a prosthetic replacement.<sup>20,21,32</sup> In addition to potentially increasing the risk of local recurrence when done for high-grade extracompartmental sarcomas, intraarticular resection with deltoid and rotator cuff preservation confers a dubious functional benefit. One time proponents of osteoarticular allograft reconstruction no longer recommend its routine use because of high complication and failure rates.<sup>20,21</sup> Gebhardt et al<sup>20</sup> reported on 20 patients treated with osteoarticular allografts after intraarticular resection of the proximal humerus (five had high-grade tumors; 15 had low-grade or benign aggressive). Fifteen percent of patients had an infection develop. Twelve complications occurred in eight patients and 11 additional procedures were needed for treatment. Patients rarely achieved shoulder abduction or

forward flexion greater than 45° and only two patients were able to abduct their shoulder 90°. Getty and Peabody<sup>21</sup> also reported on 16 patients who had intraarticular resection and reconstruction with an osteoarticular allograft. The mean Musculoskeletal Tumor Society functional score was 70%. Maximum abduction in patients who were assessed was 40° and four of nine patients who were assessed had no active abduction. None of the patients could do activities above the shoulder or could abduct against resistance. They had similar limitations in external rotation and forward flexion. Eleven patients (79%) had unstable glenohumeral joints and five (36%) had revision for fracture or infection. In both of these studies, active shoulder ROM was not dissimilar to the active shoulder motion presented in the current study.

Jensen and Johnston<sup>32</sup> reported on 14 patients who were treated with composite reconstruction of the proximal humerus (allograft or autoclaved autograft combined with a proximal humerus Neer II prosthesis) after intraarticular resection. These authors reported a 25% local recurrence rate. Active shoulder abduction was between 70° and 90° in all the patients. Most patients, however, had low- or high-grade tumors that were entirely intraosseous and therefore, the majority of resections were of smaller magnitude than those presented in the current study. Function according to the Musculoskeletal Tumor Society system was at least 24 (80%) in 12 of the 14 patients. Overall function, as evaluated by the Musculoskeletal Tumor Society system, did not seem to be significantly different, despite preservation of the shoulder abductors and glenohumeral joint.

### Prosthetic Survival

Survivability of large segment proximal humerus endoprostheses has been excellent after limb-sparing resection, especially when compared with the use of large segmental prostheses at other anatomic sites, such as the distal femur or proximal tibia.<sup>5,6,11,15,26,30,35,36,58,60,63,64</sup> In the patients in the current series, actual prosthetic survival was 100% at a me-

dian followup of 10 years (120 months). Only one patient in the current study had radiographic signs of aseptic loosening that was secondary to trauma. Malawer and Chou<sup>43</sup> previously reported 95% 5-year survival rates for proximal humerus endoprostheses after resection for various types of tumor. Feruzzi et al<sup>15</sup> reported on 33 patients followed up for at least 10 years who were treated with proximal humerus endoprosthetic reconstruction. Fifty percent of these endoprosthetic devices were placed secondary to tumor resection. There were no instances of loosening or bone resorption. Asayamongkokul et al<sup>1</sup> reported no instances of aseptic loosening in 30 patients who had cemented proximal humerus replacements after tumor resection. The low rate of failure secondary to aseptic loosening of large segment proximal humerus endoprostheses may be related to many variables such as the lack of weightbearing forces across the joint; decreased angular and torsional forces secondary to resection of the deltoid and rotator cuff muscles; the nonconstrained nature of the prosthesis; the absence of a polyethylene articulation;<sup>18,28,65</sup> the presence of porous coating at the bone-prosthesis junction that facilitates extracortical bone fixation and soft tissue ingrowth;<sup>31,34,42,65</sup> and the use of modern cementing techniques.<sup>55</sup>

Shoulder instability (prosthetic dislocation or subluxation) is a potential complication after a limb-sparing procedure for a proximal humerus sarcoma. None of the patients in the current series had prosthetic instability develop. The authors think that the success is attributable to the method of static (Dacron tapes) and dynamic (muscular) suspension of the prosthesis. The Dacron tapes probably function until sufficient soft tissue scarring of the transferred muscles occurs to stabilize the prosthesis. Other authors who combine static and dynamic methods of restraint also have reported a low incidence of prosthetic instability.<sup>1,53</sup>

Infection has been a source of failure for endoprostheses and allografts.<sup>5,8,19,26,27,36,42</sup> However, no patients in the current study had an infection develop. The use of local muscu-

lar rotational flaps (gastrocnemius flap) has been beneficial in decreasing complications, especially secondary infections, associated with proximal tibial and, occasionally, distal femoral reconstruction.<sup>11,29,45,47</sup> The same concept applies to the shoulder girdle. The pectoralis major is the key muscle used for covering the entire prosthesis with soft tissue. The pectoralis major has an excellent blood supply and provides a protective barrier for the prosthesis. Coverage by this muscle is facilitated by extraarticular resection, which permits medialization of the entire construct.

The most common complication in the current patients was transient nerve palsy. Eight patients had transient nerve palsies develop; in many cases, it developed postoperatively, during the initial 24 hours after surgery. The most likely contributing factor was intraoperative traction that was compounded by postoperative swelling. All of the neurapraxias occurred in patients who were treated with induction chemotherapy. Chemotherapeutic agents used in the treatment of osteosarcoma have known neurotoxic effects that may have predisposed this population to the nerve complications.<sup>66</sup>

The authors recommend extraarticular resection encompassing the deltoid and rotator cuff (modified Tikhoff-Linberg resection; Malawer Type VB resection) for all patients with high-grade osteosarcomas arising from the proximal humerus that present with a significant extraosseous soft tissue component. This method of resection is consistent with the basic biologic rules of sarcoma surgery, in that it accomplishes a compartmental resection of the tumor and removes all structures (pseudocapsule) potentially contaminated by tumor cells. The authors think that this approach is the safest method for achieving a wide surgical resection and obtaining local tumor control. This is important because patients with a local recurrence in this region often are treated with a forequarter amputation, which can have an adverse effect on survival. The authors recommend intraarticular resection that spares the rotator cuff and deltoid for high-grade osteosarcomas that are entirely intraosseous (Stage IIA). Reconstruction with

an endoprosthesis and static and dynamic methods of soft tissue reconstruction should be strongly considered. This method of reconstruction consistently has achieved good functional results, is durable, and is associated with a low rate of complications. Most patients have resumed chemotherapy promptly and have had functional use of the extremity within 6 weeks. Shoulder stability has been restored without compromising rotation below the shoulder level, where most activities are done. Patients have been pain-free and have had normal functional use of the elbow and hand. Low-level athletic activities also are possible.

## References

1. Asavamongkolkul A, Eckardt JJ, Eilber FR, et al: Endoprosthetic reconstruction for malignant upper extremity tumors. *Clin Orthop* 360:207–220, 1999.
2. Bacci G, Picci P, Ferrari S, et al: Primary chemotherapy and delayed surgery for nonmetastatic osteosarcoma of the extremities: Results in 164 patients preoperatively treated with high doses of methotrexate followed by cisplatin and doxorubicin. *Cancer* 72:3227–3238, 1993.
3. Bacci G, Springfield D, Capanna R, et al: Neoadjuvant chemotherapy for osteosarcoma of the extremity. *Clin Orthop* 224:268–276, 1987.
4. Badhwar R: Reconstruction following limb-sparing en bloc resection of the shoulder girdle-Tikhoff-Linberg procedure. *Ind J Cancer* 27:31–37, 1990.
5. Brien EW, Terek R, Healey JH, Lane JM: Allograft reconstruction after proximal tibial resection for bone tumors: An analysis of function and outcome comparing allograft and prosthetic reconstructions. *Clin Orthop* 303:116–127, 1994.
6. Capanna R, Morris HG, Campanacci D, Del Ben M, Campanacci M: Modular uncemented prosthetic reconstruction after resection of tumors of the distal femur. *J Bone Joint Surg* 76B:178–186, 1994.
7. Capanna R, Van Horn JR, Biagini R, et al: The Tikhoff-Linberg procedure for bone tumors of the proximal humerus: The classical “extensive” technique versus a modified “transglenoid” resection. *Arch Orthop Trauma Surg* 109:63–67, 1990.
8. Clohisy DR, Mankin HJ: Osteoarticular allografts for reconstruction after resection of a musculoskeletal tumor in the proximal end of the tibia. *J Bone Joint Surg* 76A:549–554, 1994.
9. Davis AM, Bell RS, Goodwin P: Prognostic factors in osteosarcoma: A critical review. *J Clin Oncol* 12:423–431, 1994.
10. Damron TA, Rock MG, O'Connor MI, et al: Functional laboratory assessment after oncologic shoulder joint resections. *Clin Orthop* 348:124–134, 1998.
11. Eckardt JJ, Matthews JG, Eilber FR: Endoprosthetic reconstruction after bone tumor resections of the proximal tibia. *Orthop Clin North Am* 22:149–160, 1991.
12. Enneking WF: Natural History. In Enneking WF



- (ed). *Musculoskeletal Tumor Surgery*. Vol 1. New York, Churchill Livingstone 3–68, 1983.
13. Enneking WF: Shoulder Girdle. In Enneking WF (ed). *Musculoskeletal Tumor Surgery*. Vol 1. New York, Churchill Livingstone 378–410, 1983.
  14. Enneking WF, Dunham W, Gebhardt MC, Malawer MM, Pritchard DJ: A system for the functional evaluation of reconstructive procedures after surgical treatment of tumors of the musculoskeletal system. *Clin Orthop* 286:241–246, 1993.
  15. Feruzzi A, Ruggieri P, Capanna R, Campanacci M: Prosthetic Replacement of the Proximal Humerus: Update of Cases Presented in 1981. In Brown KLB (ed). *Complications of Limb Salvage. Prevention, Management and Outcome*, Montreal, International Society of Limb Salvage 473–477, 1991.
  16. Francis KC, Worcester JN: Radical resection for tumors of the shoulder with preservation of a functional extremity. *J Bone Joint Surg* 44A:1423–1430, 1962.
  17. Frassica FJ, Sim FH, Chao EYS: Primary malignant bone tumors of the shoulder girdle: Surgical technique of resection and reconstruction. *Am Surg* 53:264–269, 1987.
  18. Friedman RJ: Advances in biomaterials and factors affecting implant fixation. *Instr Course Lect* 41:127–136, 1992.
  19. Gebhardt MC, Flugstad DI, Springfield DS, Mankin HJ: The use of bone allografts for limb salvage in high grade extremity osteosarcoma. *Clin Orthop* 270:181–196, 1991.
  20. Gebhardt MC, Roth YF, Mankin HJ: Osteoarticular allografts for reconstruction in the proximal part of the humerus after excision of a musculoskeletal tumor. *J Bone Joint Surg* 72A:334–345, 1990.
  21. Getty PJ, Peabody TD: Complications and functional outcomes of reconstruction with an osteoarticular allograft after intra-articular resection of the proximal aspect of the humerus. *J Bone Joint Surg* 81A:1138–1146, 1999.
  22. Glasser DB, Lane JM, Huvos AG, Marcove RC, Rosen G: Survival, prognosis and therapeutic response in osteogenic sarcoma: The Memorial Hospital experience. *Cancer* 69:698–708, 1992.
  23. Glynn MK, Quinlan W, Fennelly J: Endoprosthetic replacement of the proximal humerus for osteogenic sarcoma. *Ir J Med Sc* 151:285–287, 1982.
  24. Goorin AM, Shuster JJ, Baker A, et al: Changing pattern of pulmonary metastases with adjuvant chemotherapy in patients with osteosarcoma: Results from the multiinstitutional osteosarcoma study. *J Clin Oncol* 9:600–605, 1991.
  25. Ham SJ, Hoekstra HJ, Eisma WH, Koops HS, Oldhoff J: The Tikhoff-Linberg procedure in the treatment of sarcomas of the shoulder girdle. *J Surg Oncol* 53:71–77, 1993.
  26. Ham SJ, Koops HS, Veth RP, et al: Limb salvage surgery for primary bone sarcoma of the lower extremities: Long term consequences of endoprosthetic reconstructions. *Ann Surg Oncol* 5:423–436, 1998.
  27. Hornicek FJ, Mnaymneh W, Lackman RD, Exner GU, Malinin TI: Limb salvage with osteoarticular allografts after resection of proximal tibial bone tumors. *Clin Orthop* 352:179–186, 1998.
  28. Horowitz SM, Gautsch TL, Frondoza CG, Riley Jr L: Macrophage exposure to polymethylmethacrylate leads to mediator release and injury. *J Orthop Res* 9:406413, 1991.
  29. Horowitz SM, Lane JM, Healey JH: Soft-tissue management with prosthetic replacement for sarcomas around the knee. *Clin Orthop* 275:226–231, 1992.
  30. Horowitz SM, Land JM, Otis JC, Healey JH: Prosthetic arthroplasty of the knee after resection of a sarcoma in the proximal end of the tibia: A report of sixteen cases. *J Bone Joint Surg* 73A:286–293, 1991.
  31. Hulbert SF, Cooke FW, Klawitter JJ, et al: Attachment of prostheses to the musculoskeletal system by tissue ingrowth and mechanical interlocking. *J Biomed Mater Res Symp* 4:1–23, 1973.
  32. Jensen KL, Johnston JO: Proximal humeral reconstruction after excision of a primary sarcoma. *Clin Orthop* 311:164–175, 1995.
  33. Kaelin AJ, Emans JB: En-bloc resection for proximal humerus osteogenic sarcoma. *Z Kinderchir* 40:217–220, 1985.
  34. Kaste SC, Neel MD, Meyer WH, Pratt CB, Rao BN: Extracortical bridging callus after limb salvage surgery about the knee. *Clin Orthop* 363:180–185, 1999.
  35. Kawai A, Healey JH, Boland PJ, Athanasian EA, Jeon DG: A rotating hinge knee replacement for malignant tumors of the femur and tibia. *J Arthroplasty* 14:187–195, 1999.
  36. Kawai A, Muschler GF, Lane JM, Otis JC, Healey JH: Prosthetic knee replacement after resection of a malignant tumor of the distal part of the femur: medium to long term results. *J Bone Joint Surg* 80A:636–647, 1998.
  37. Kumar VP, Satku SK, Mitra AK, Pho RWH: Function following limb salvage for primary tumors of the shoulder girdle. *Acta Orthop Scand* 65:55–61, 1994.
  38. Linberg BE: Interscapulo-thoracic resection for malignant tumors of the shoulder joint region. *J Bone Joint Surg* 10A:344–349, 1928.
  39. Malawer MM: Surgical technique and results of limb sparing surgery for high grade bone sarcomas of the knee and shoulder. *Orthopedics* 8:597–607, 1985.
  40. Malawer MM: Tumors of the shoulder girdle: Technique of resection and description of a surgical classification. *Orthop Clin North Am* 22:73–75, 1991.
  41. Malawer M, Buch R, Khurana JS, Garvey T, Rice L: Postoperative infusional continuous regional analgesia: A technique for relief of postoperative pain following major extremity surgery. *Clin Orthop* 266:227–237, 1991.
  42. Malawer M, Canfield D, Meller I: Porous Coated Segmental Prostheses for Large Tumor Defects. In Yamamuro T (ed). *New Developments for Limb Salvage in Musculoskeletal Tumors*. New York, Springer 247–255, 1989.
  43. Malawer MM, Chou LB: Prosthetic survival and clinical results with use of large-segment replacements in the treatment of high grade bone sarcomas. *J Bone Joint Surg* 77A:1154–1165, 1995.
  44. Malawer MM, Link MP, Donaldson SS: Sarcomas of Bone. In DeVita Jr VT, Hellman S, Rosenberg SA (eds). *Cancer: Principles and Practice of Oncology*.



- Ed 5. Philadelphia, Lippincott-Raven Publishers 1891–1935, 1997.
45. Malawer MM, McHale K: Limb-sparing surgery for high grade malignant tumors of the proximal tibia: Surgical technique and a method of extensor mechanism reconstruction. *Clin Orthop* 239:231–248, 1989.
  46. Malawer MM, Meller I, Dunham WK: A new surgical classification system for shoulder girdle resections: Analysis of 38 patients. *Clin Orthop* 267:33–44, 1991.
  47. Malawer MM, Price W: Gastrocnemius transposition flap in conjunction with limb-sparing surgery for primary bone sarcomas around the knee. *Plast Reconstr Surg* 73:741–750, 1984.
  48. Malawer MM, Sugarbaker PH, Lampert M, Baker AR, Gerber NL: The Tikhoff-Linberg procedure: Report of ten patients and presentation of a modified technique for tumors of the proximal humerus. *Surgery* 97:518–528, 1985.
  49. Marcove RC, Abou-Zahr K: En bloc surgery for osteogenic sarcoma: Analysis and review of ninety operative cases. *Bull NY Acad Med* 60:748–758, 1984.
  50. Marcove RC, Lewis MM, Huvois AG: En bloc upper humeral interscapulo-thoracic resection: The Tikhoff-Linberg procedure. *Clin Orthop* 1124:219–228, 1977.
  51. Marcove RC, Mike V, Hajek JV, Levin AG, Hutter RVP: Osteogenic sarcoma under the age of twenty-one. *J Bone Joint Surg* 52A:411–423, 1970.
  52. Marcove RC, Rosen G: En bloc resections for osteogenic sarcoma. *Cancer* 45:3040–3044, 1980.
  53. Meller I, Bickels J, Kollender Y, et al: Malignant bone and soft tissue tumors of the shoulder girdle. *Acta Orthop Scand* 68:374–380, 1997.
  54. O'Connor MI, Sim FH, Chao EYS: Limb salvage for neoplasms of the shoulder girdle: Intermediate reconstructive and functional results. *J Bone Joint Surg* 78A:1872–1888, 1996.
  55. Poss R, Brick GW, Wright RJ, Roberts DW, Sledge CB: The effects of modern cementing techniques on the longevity of total hip arthroplasty. *Orthop Clin North Am* 19:591–598, 1988.
  56. Provisor AJ, Ettinger LJ, Nachman JB, et al: Treatment of nonmetastatic osteosarcoma of the extremity with preoperative and postoperative chemotherapy: A report from the children's cancer group. *J Clin Oncol* 15:76–84, 1997.
  57. Rha SY, Chung HC, Gong SJ, et al: Combined preoperative chemotherapy with intraarterial cisplatin and continuous intravenous adriamycin for high grade osteosarcoma. *Oncol Rep* 6:631–637, 1999.
  58. Roberts P, Chan D, Grimer RJ, Sneath RS, Scales JT: Prosthetic replacement of the distal femur for primary bone tumors. *J Bone Joint Surg* 73B:762–769, 1991.
  59. Rosen G, Caparros B, Huvois AG, et al: Preoperative chemotherapy for osteogenic sarcoma: Selection of postoperative adjuvant chemotherapy based on the response of the primary tumor to preoperative chemotherapy. *Cancer* 49:1221–1230, 1982.
  60. Ross AC, Wilson JN, Scales JT: Endoprosthetic replacement of the proximal humerus. *J Bone Joint Surg* 69B:656–661, 1987.
  61. Rubert CK, Malawer MM, Kellar KL: Modular endoprosthetic replacement of the proximal humerus: Indications, surgical technique, and results. *Semin Arthroplasty* 10:142–153, 1999.
  62. Ruggieri P, De Cristofaro R, Picci P, et al: Complications and surgical indications in 144 cases of non-metastatic osteosarcoma of the extremities treated with neoadjuvant chemotherapy. *Clin Orthop* 295:226–238, 1993.
  63. Shih LY, Sim FH, Pritchard DJ, Rock MG, Chao EYS: Segmental total knee arthroplasty after distal femoral resection for tumor. *Clin Orthop* 292:269–271, 1993.
  64. Sim FH, Beauchamp CP, Chao EYS: Reconstruction of musculoskeletal defects about the knee for tumor. *Clin Orthop* 221:188–201, 1987.
  65. Ward WG, Johnston KS, Dorey FJ, Eckardt JJ: Extramedullary porous coating to prevent diaphyseal osteolysis and radiolucent lines around proximal tibial replacements. *J Bone Joint Surg* 75A:976–987, 1993.
  66. Weiss RB: Miscellaneous Toxicities. In DeVita Jr VT, Hellman S, Rosenberg SA (eds). *Cancer: Principles and Practice of Oncology*. Ed 5. Philadelphia, Lippincott-Raven Publishers 2799–2802, 1997.
  67. Whitehall R, Wanebo HJ, Mabie KN, Schildwachter T, Rosenberger R: Reconstruction after the Tikhoff-Linberg procedure. *Arch Surg* 117:1248–1249, 1982.

Unauthorized Use  
Prohibited