

# Appendix A: Abdominoinguinal Incision for the Resection of Pelvic Tumors

Constantine P. Karakousis

---

## OVERVIEW

The abdominoinguinal incision allows a vast improvement in the exposure and resectability of tumors in the lower abdomen with fixation to the pelvic side wall. A midline abdominal incision is connected to a longitudinal inguinal incision across the inguinal ligament. The pelvic side wall is directly exposed by detachment of the rectus muscle from its origin on the pubic crest and by division of the inguinal canal along the spermatic cord. This exposure allows safe resections along the iliac vessels without tumor spillage. The abdominoinguinal incision should be part of the armamentarium of every surgeon willing to accept responsibility for pelvic and pelvic side wall malignancy.

## INTRODUCTION

Pelvic tumors with lateral fixation present difficulties in their resection, primarily due to inadequate exposure through conventional abdominal incisions. The difficulty arises especially with tumors in the lower parts of the pelvis where the anterior abdominal wall converges with the retroperitoneal structures (e.g. iliopsoas muscle, iliac vessels). In this area the inguinal ligament spanning between the anterior superior iliac spine and the pubic tubercle provides an obstacle to unhindered exposure.

A midline, paramedian, or oblique abdominal incision often does not provide adequate exposure for these tumors. These incisions render sufficient exposure for the dissection and control of the common iliac vessels proximally, below the bifurcation of the aorta, but do not afford exposure of the terminal portion of the external iliac vessels because the presence of tumor hinders further visibility. Often these tumors are considered unresectable or are managed with hemipelvectomy.

Queral and Elias reported a two-stage procedure for removal of a sarcoma localized in the right iliac fossa with involvement of the iliac vessels.<sup>1</sup> In the first operation a femorofemoral bypass was performed from the left side to the right, and the common femoral artery was proximally ligated and divided. In the second operation, through an abdominal incision the mass was resected with en-bloc resection of a segment of the right iliac vessels, which were ligated and divided proximally. This example provides a solution to the distal control of the iliac vessels, but it requires two operations, and exposure at the time of resection of the tumor mass through an abdominal incision remains suboptimal.

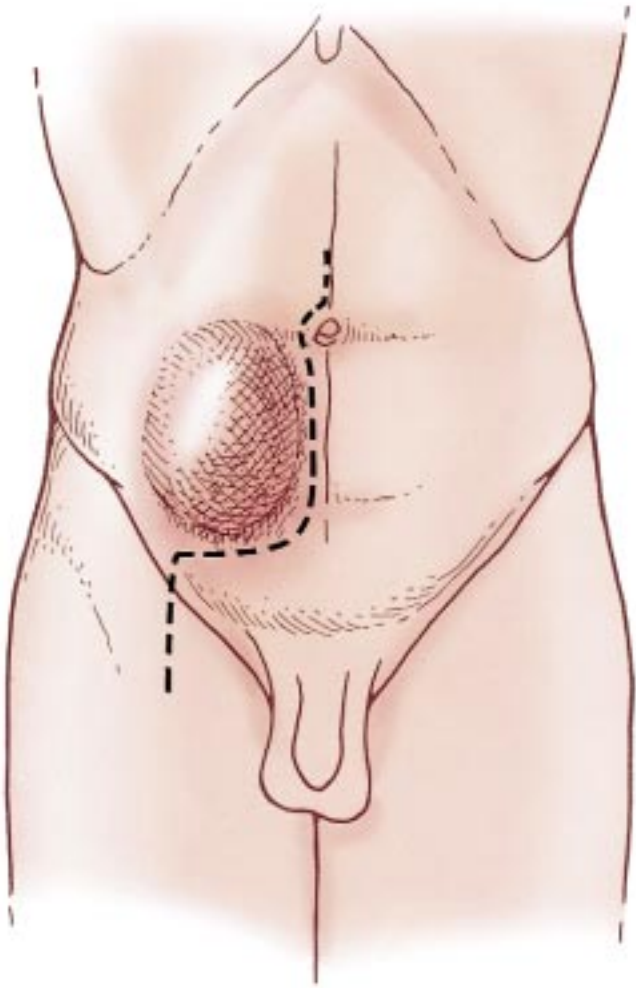
What is needed for the resection of these tumors is an incision that would simultaneously provide an continuity in exposure of the abdominal cavity and one or both groins so that both iliac and femoral vessels would

be exposed in one field. For this incision an abdominal component would be needed and an discontinuity inguinal component, i.e. an abdominoinguinal incision. The inguinal ligament would have to be divided to allow uninterrupted exposure and control of the iliofemoral vessels.

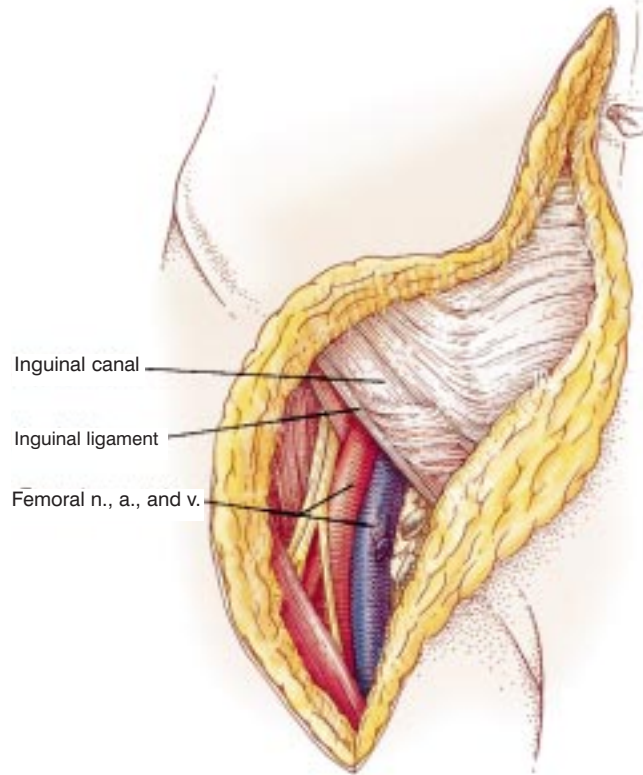
A lower midline incision provides good exposure of the intrapelvic structures. An inguinal incision exposes the femoral vessels. A transverse incision connecting the two, by dividing the origin of the rectus abdominis from the pubic crest and the insertion of the inguinal ligament to the pubic tubercle, provides the necessary link that allows a single discontinuity field and optimizes exposure. Although in the preceding discussion we arrived at the abdominoinguinal incision deductively, in reality I stumbled upon variations of it in the first few cases in the process of designing an incision for a specific tumor.<sup>2</sup> Later I realized that this could be developed into a formal incision for exposure in the lower quadrants of the abdomen. The abdominoinguinal incision may function much in the same way that the thoracoabdominal incision is used for the upper quadrants of the abdomen.<sup>3</sup>

## INDICATIONS

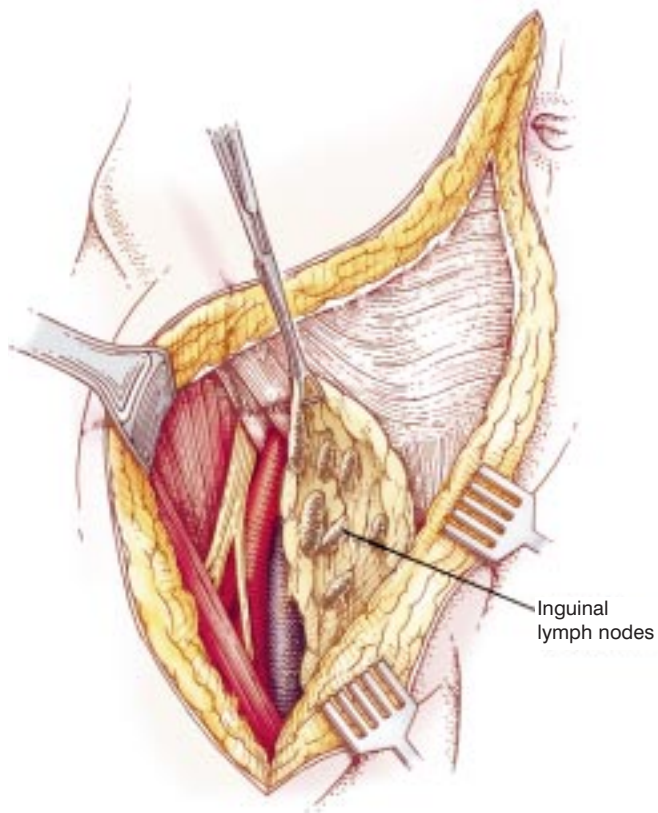
The indications for the abdominoinguinal incision are: (1) abdominal or pelvic tumors extending over the iliac vessels, (2) tumors in the iliac fossa (Figure A1), (3) primary tumors, possibly involving the iliac vessels or large iliac lymph node metastases, (4) tumors with fixation to the wall of the true pelvis or large obturator nodes, (5) tumors involving the pubic bone with or without extension to the pelvis or adductor group of muscles, and (6) tumors of the groin when they involve the vessels of the lower abdominal wall or extend in the retroperitoneal area.



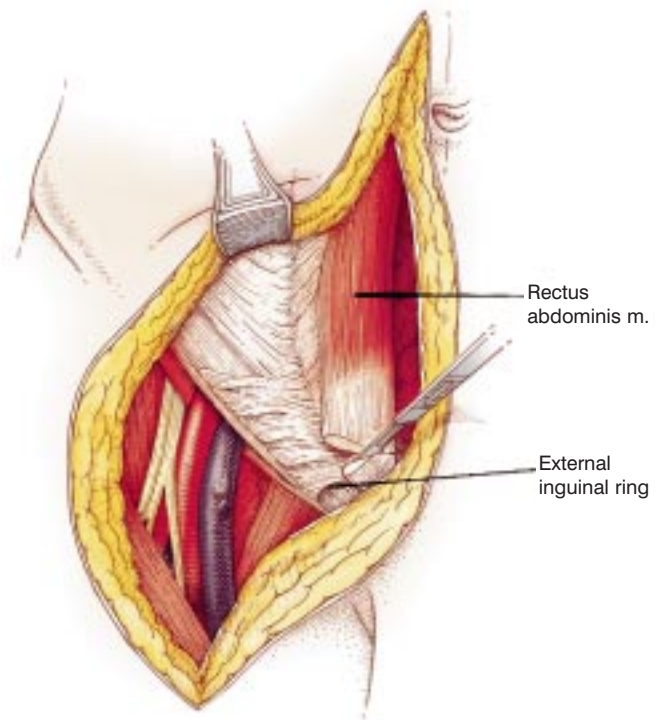
**Figure A1** Position and incision. With the patient in the supine position, a lower midline abdominal incision is outlined from just above the umbilicus to the pubic symphysis. The peritoneal cavity is entered, and exploration is carried out to assess the extent of disease. Preliminary dissection between the tumor mass and midline pelvic structures may be carried out. Involvement of the latter does not necessarily mean unresectability, of course, since they can often be removed en-bloc with the tumor. When there is a question of involvement of the iliac vessels distally, the common iliac vessels are dissected free and vessel loops are passed around them.



**Figure A2** Incision through inguinal canal. If the decision is made to proceed with the resection the lower end of the incision is extended transversely to the midinguinal point and then vertically, over the course of the femoral vessels, for a few centimeters. The vertical portion of the incision is deepened to expose the common femoral vessels.

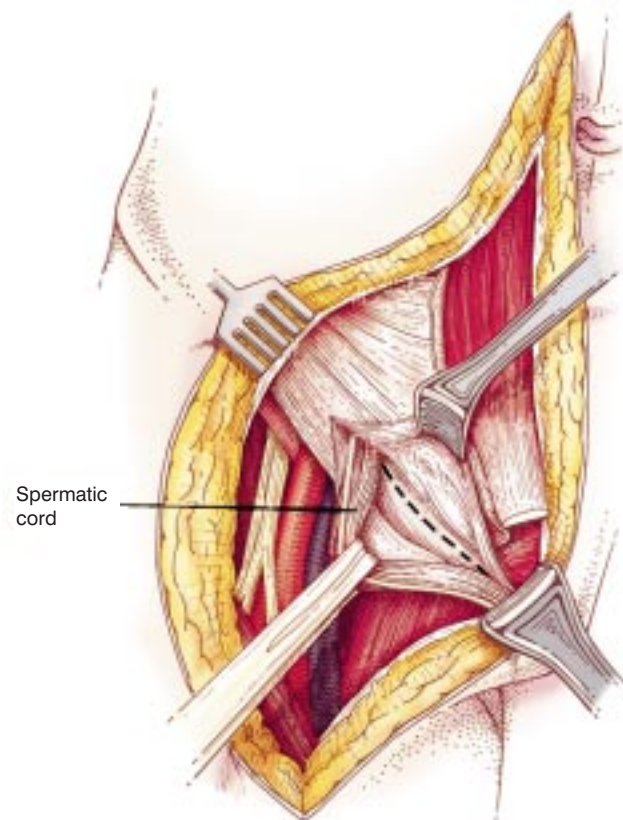


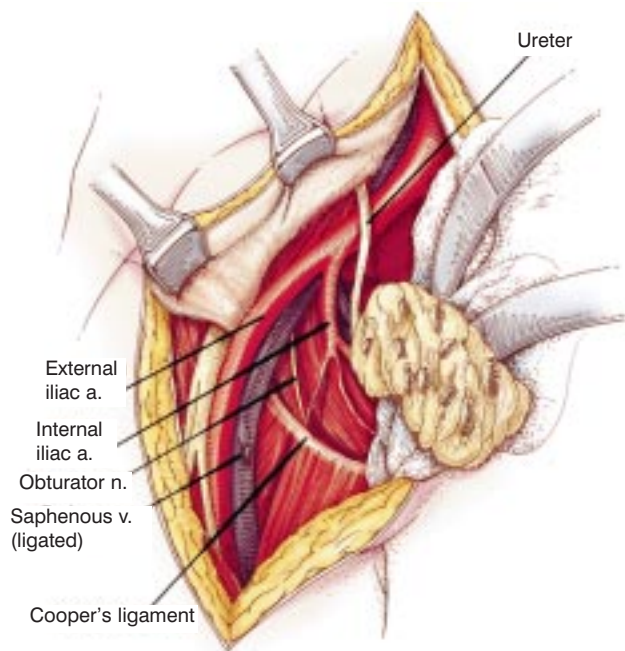
**Figure A3** Dissection of inguinal nodes. When the operation is performed for large iliac and/or obturator nodes, or if there is clinical or potential microscopic involvement of the inguinal nodes, the vertical portion of the incision is made to extend to the apex of the femoral triangle, flaps are raised as in a groin dissection,<sup>4</sup> and the nodes are mobilized off the femoral vessels, but their proximal continuity with the deep nodes is preserved.



**Figure A4** Division of rectus abdominis muscle. The transverse portion of the incision is deepened to the surface of the anterior rectus sheath, which is divided, and the rectus abdominis muscle is transected a few millimeters from its origin on the pubic crest. This incision is through its tendinous portion.

**Figure A5 (right)** Incising the floor of the inguinal canal. The inguinal canal floor is divided in the same direction up to and including the medial border of the internal inguinal ring. In so doing, the spermatic cord is displaced medially. Alternatively, after division of the medial crus the inguinal floor may be incised from inside and the cord exposed from within the abdomen and extracted from the inguinal canal for medial displacement. Deep to the internal inguinal ring the structures of the cord deviate, the vas deferens coursing medially, and the internal spermatic vessels toward a lateral and cephalad direction. Depending on the location of the tumor, the internal spermatic vessels may have to be divided at this level; this maneuver usually leaves a viable ipsilateral testis. Division of the cord at the level of the external inguinal ring does not require ipsilateral orchiectomy but will be accompanied by testicular atrophy.





**Figure A6** Exposure of the pelvic side wall. The inguinal ligament is then divided at the pubic tubercle and dissection carried on its undersurface until the inferior deep epigastric vein and artery are encountered, ligated, and divided. The lateral third of the inguinal ligament is then detached off the iliac fascia. This allows the completion of the abdominoinguinal incision and provides wide exposure of abdomen and pelvis.

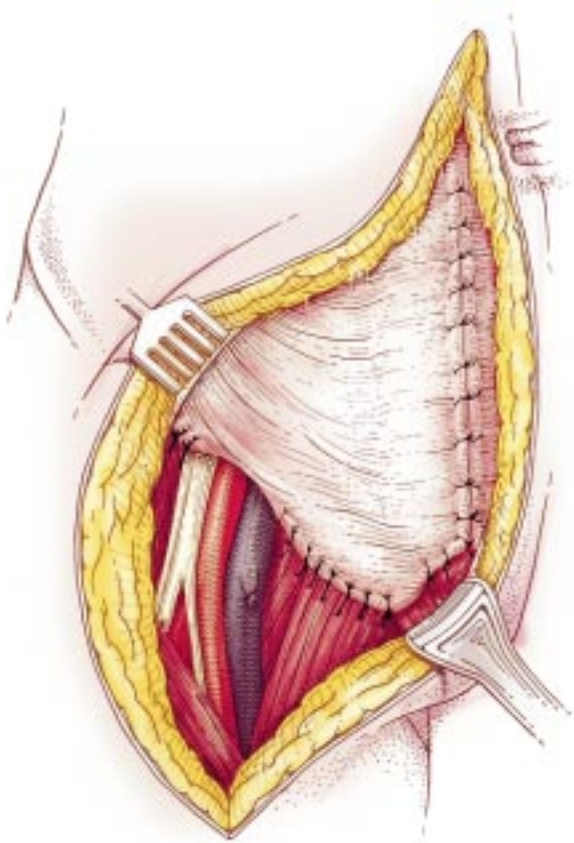
Further dissection depends on the location of the tumor. If the tumor is simply a pelvic mass extending over and obscuring the iliac vessels, the improved exposure now makes easy the dissection of the mass off the vessels and safe ligation of any tumor feeding branches. For large nodes the dissection is carried on the surface of the iliac vessels which are skeletonized. For a tumor located in the iliac fossa, the femoral nerve is located lateral to the femoral artery, immediately posterior to the continuation of the iliac fascia. A vessel loop is passed around it. Further cautious dissection along this nerve determines its relation to the tumor and whether it can be saved. If the tumor involves the vessels, proximal and distal control are secured and the dissection completed around the tumor mass, with any involved organs removed en-bloc. When the specimen is held only by the attachment to the vessels, the patient is heparinized, vascular clamps are placed proximally and distally, the specimen is removed, and ascular reconstruction is performed.

When the iliofemoral vessels are to be resected, the profunda femoris branches may have to be divided at a distance from the tumor in order to allow the mobilization of the specimen.

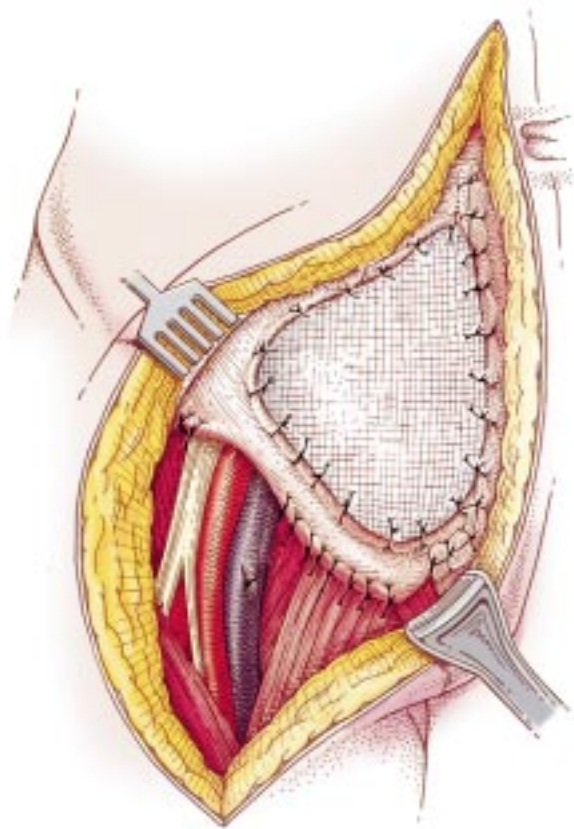
For tumors attached to the wall of the lesser pelvis or the obturator fossa, the improved exposure usually allows their resection. For tumors involving the pubic bone, following the completion of the abdominoinguinal incision, the abductor muscles are divided off the pubic bone at an appropriate distance from the tumor and the anterior and posterior pubic rami are exposed: the former just medial to the acetabulum and the latter medial to the ischial tuberosity. With the help of a right-angle clamp a Gigli saw is passed around the pubic symphysis, which is divided along with the anterior and posterior pubic rami. The obturator nerve and vessels have to be divided proximally because they course through the obturator foramen. The defect may be replaced with a polypropylene mesh.

For a large tumor located in the groin, covering or involving the entire length of the common femoral vessels and possibly the lower abdominal wall, the abdominoinguinal incision provides incontinuity exposure of the iliofemoral vessels. In making the incision, flaps may have to be raised around the mass. If the lower abdominal wall and inguinal ligament are involved, following transection of the anterior rectus sheath and rectus abdominis muscle off the pubic crest, the incision is continued through the external oblique aponeurosis and internal oblique and transversus abdominis muscles at a sufficient distance from the tumor. The inguinal ligament is divided off the anterior superior iliac spine and the pubic tubercle, and thus the lower abdominal wall muscles and inguinal ligament are removed en-bloc with the tumor. The inferior epigastric vessels are divided at the point they proceed behind the rectus muscle.

In **Figure A6** the lateral third of the inguinal ligament has not been detached off the iliac fascia, a step providing further exposure.

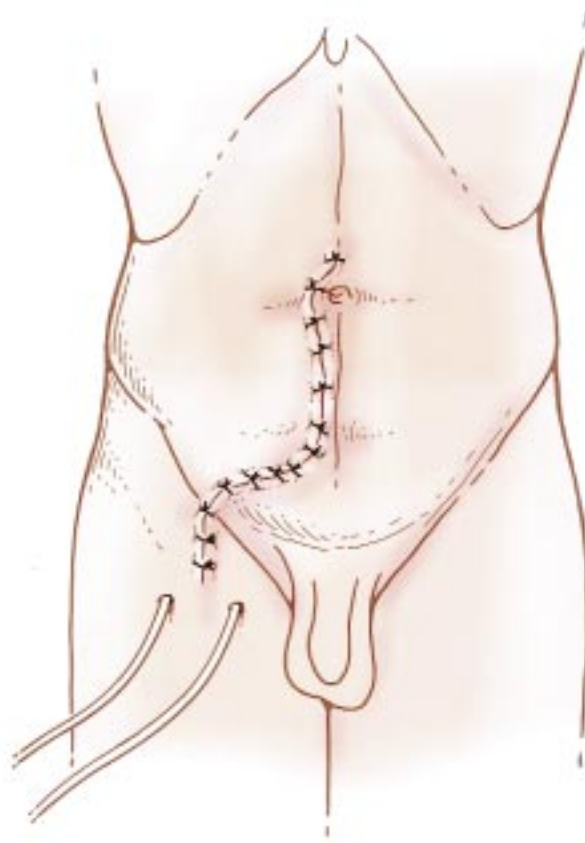


**Figure A7** Deep closure. The closure of the abdominoinguinal incision is uncomplicated. Lateral to the vessels the inguinal ligament is approximated to the iliac fascia and medial to the vessels to Cooper's ligament. The rectus sheath and muscle are approximated to their remnants on the pubic crest. A suction drain is placed in the inguinal portion of the incision. A subcutaneous layer of absorbable material may be used. The skin and the midline portion of the incision are closed in a routine fashion.



**Figure A8** Deep closure requiring mesh. When a defect in the fascia has been created, it may be covered with a plastic mesh, which also replaces the inguinal ligament. The mesh should not be in direct contact with the vessels. This can usually be done by dividing the sartorius muscle distally at the apex of the femoral triangle and mobilizing the distal end so that the vessels are covered, taking care to avoid devascularization of this muscle.

When the defect in the groin also involves the skin, we have used the contralateral rectus abdominis muscle which is divided proximally and rotated with the posterior sheath attached to it, its blood supply deriving from the inferior epigastric vessels. The muscle is sutured to the defect and skingrafted immediately.



**Figure A9** Skin closure.

## DISCUSSION

The abdominoinguinal incision has been used in over 50 patients with a variety of tumors, usually soft-tissue sarcomas. One of these patients had adenocarcinoma of the sigmoid fixed to the iliac fascia. This tumor was thought to be unresectable at another hospital, but was successfully removed through this incision. The majority of the patients had been operated on once or twice elsewhere, and were found to be unresectable or thought to need a hemipelvectomy.

All these tumors, presenting with fixation to the soft tissues of the wall of the pelvis, were resected with the abdominoinguinal incision, with the exception of two patients. They required hemipelvectomy due to extensive nerve involvement. One patient required an abdominobiinguinal incision, i.e. bilateral extension of the abdominal inguinal midline incision to the groins. Tumors involving the innominate bone, with the exception of the medial portion of the pubic bone, are resected best with the use of the techniques of internal hemipelvectomy,<sup>4</sup> and, if necessary, hemipelvectomy.

The abdominoinguinal incision heals well without complications. In the event of a previous transverse incision in the lower quadrant, which may have interrupted the connection to the superior epigastric vessels and the distal portion of intercostal and lumbar branches, a small area of necrosis at the junction of the midline and transverse portions of the incision may occur, since this incision divides the inferior epigastric vessels. In two patients with this condition a small area of ischemic necrosis developed, which, following debridement, healed by secondary intention.

There was one death 2 weeks postoperatively, which resulted from erosion and hemorrhage of a previously heavily radiated external iliac artery that was in contact with a mesh used to replace a fascial defect. It is important therefore to cover the vessels with the sartorius or rectus femoris muscle (by dividing its origin from the anterior inferior iliac spine and displacing it medially) when a mesh is placed adjacent to the vessels or when there is concern about pap necrosis. No instances of postoperative incisional hernia have been noted.

The abdominoinguinal incision renders resectable the majority of pelvic tumors with lateral fixation to the soft tissues of the pelvis and, through improvement in exposure, allows for a safe, deliberate dissection. It is the counterpart of the thoracoabdominal incision for the upper quadrants of the abdomen. The results from the use of this incision obviously depend on the histologic type and stage of the tumor and the expected margin of resection one can thus obtain. It should be used when appropriate and in the context of the biology of the tumor, the expected margin, and the possible use of adjuvant treatments.

In many situations in which the tumor is not laterally fixed, but when it is large and distal and pressing against the obturator foramen(s) or the obturator areas, one can obtain sufficient exposure with a unilateral or bilateral use of the transverse portion of the full incision. In other words, the lower end of the midline incision is extended transversely from the pubic symphysis to the pubic tubercle, and the ipsilateral rectus sheath and muscle are divided off the pubic crest.

## References

1. Queral LA, Elias KG. Femorofemoral and venous bypasses in association with resection of a pelvic leiomyosarcoma. In General Surgery Motion Picture Session 10/24/84 of the American College of Surgeons, 1984 Clinical Congress.
2. Karakousis CP. Exposure and reconstruction in the lower portions of the retroperitoneum and abdominal wall. *Arch Surg.* 1982; 117:840-4.
3. Karakousis CP. The abdominoinguinal incision in limb salvage and resection of pelvic tumors. *Cancer.* 1984;54: 2543-8.
4. Karakousis CP. Ilioinguinal lymph node dissection. *Am J Surg.* 1981;141:299-303.